

# Surgical treatment of primary cardiac tumors: an eleven-year experience of a single center

Kenan Sever, Ozgur Yildirim

Department of Cardiovascular Surgery, Faculty of Medicine, Istanbul Yeniuzyil University Gaziosmanpasa Hospital, Istanbul, Turkey

Copyright © 2020 by authors and Annals of Medical Research Publishing Inc.

## Abstract

**Aim:** We aimed to report our surgical experience about cardiac tumors in our hospital

**Material and Methods:** The study enrolled 25 patients who underwent cardiac surgery for cardiac tumors between June 2009 and June 2019. Baseline clinical features, symptoms of the patients, localizations of the tumors and surgical notes of the patients were recorded.

**Results:** In 22 of 25 patients, histopathologic result was atrial myxoma. The other three tumors were hibernoma, papillary fibroelastoma and angiosarcoma. Hibernoma was in interatrial septum, papillary fibroelastoma was on subvalvular surface of aortic valve and angiosarcoma was in right atrium invading into right ventricle. We experienced our own recurrence in one patient, also re-operated another patient who underwent the first operation in a different hospital. No death and major complication occurred during post-operative period.

**Conclusion:** Surgical removal of the cardiac tumors is an effective treatment with low complication and recurrence rates.

**Keywords:** Cardiac tumor; myxoma; neoplasm; surgery

## INTRODUCTION

Primary tumors of the heart are less common than metastases. Cardiac tumor is relatively rare among all tumors and present in 0.3% of patients undergoing cardiac surgery (1). Its incidence is reported as 0.001% to 0.3% (2). Approximately 80% of primary cardiac tumors are benign and 20% are malignant (3). More than 50% of primary cardiac tumors are myxoma. After that, lipoma, papillary fibroelastoma and rhabdomyoma are seen at lesser rates. Different types of sarcomas constitute 95% of malignant cardiac tumors (4).

It can be quite insidious that cardiac tumors give evidence. Therefore, it can follow a wide spectrum from completely symptom free to different symptoms. If the symptom develops, it may be constitutional (such as weight loss, fever) or due to distal embolization and direct effect of the tumor. Obstruction of blood flow by tumor can lead to dyspnea, syncope, palpitations and even heart failure (1,2,3). Echocardiography, computed tomography and magnetic resonance imaging (MRI) are non-invasive methods used in the investigation of cardiac tumors (5). Removal of tumors by surgery is the preferred and effective approach for the treatment of either benign or malignant tumors (6). In this study, we aimed to review surgical experience of primary cardiac tumors at a period of eleven years.

## MATERIAL and METHODS

The study included 25 patients who underwent cardiac surgery for cardiac tumors in our center between June 2009 and June 2019. The enrollment of the patients were performed consecutively. Most of the patients underwent solely cardiac tumor surgery. However, patients who underwent valve surgery or coronary artery bypass grafting in addition to cardiac tumor surgery was also added to the study group. It was approved by institutional ethical committee, informed consent of the patients were obtained. Clinical and operational data and in-hospital complications were gathered by hospital database system and the files of the patients. Baseline clinical features, symptoms of the patients and localization of the cardiac tumors were also noted. Echocardiography was performed in all patients in preoperative diagnosis. For better imaging, transesophageal echocardiogram (TEE) and MRI were applied in some of the patients, if necessary. Coronary angiography was also performed for patients over 40 years old

Myxomas were bright, brown in color, elastic in texture and fragile. Papillary fibroelastoma was seen as a myxomatous mass with an irregular surface. Angiosarcoma was seen as a hard surface with irregular structure, bleeding, and in some places as a necrotic mass.

**Received:** 13.06.2020 **Accepted:** 21.08.2020 **Available online:** 18.09.2020

**Corresponding Author:** Kenan Sever, Department of Cardiovascular Surgery, Faculty of Medicine, Istanbul Yeniuzyil University Gaziosmanpasa Hospital, Istanbul, Turkey **E-mail:** kenansever@gmail.com

Pathologic diagnosis of the removed tumors were obtained from pathology department of our hospital.

### Surgical technique

Standard median sternotomy was achieved with total cardiopulmonary bypass with moderate hypothermia (32-34 ° C) and blood cardioplegia. Interatrial septum was reached in all patients via the right atrium. None of the patients required combined right-left atriotomy or left atriotomy. The mass of the patient, who had a mass in the right ventricle, was also reached from the right atrium. The cardiac mass was removed with at least 5 mm non-tumorous tissue. To reduce the risk of complication, we had performed minimal manipulation until cross-clamp was placed. The mass was carefully removed to prevent mass embolization. Left atrial vent catheter was inserted after the removal of the mass.

## RESULTS

Of 25 patients enrolled, 8 of them were male (32%) and 17 were female (68%). The average age was 52.12 (Minimum 24- maximum 75). The mass was in the left atrium in 21 patients, the right atrium in 2 patients (one of them extending into right ventricle), interatrial septum in 1 patient and aortic valve in 1 patient.

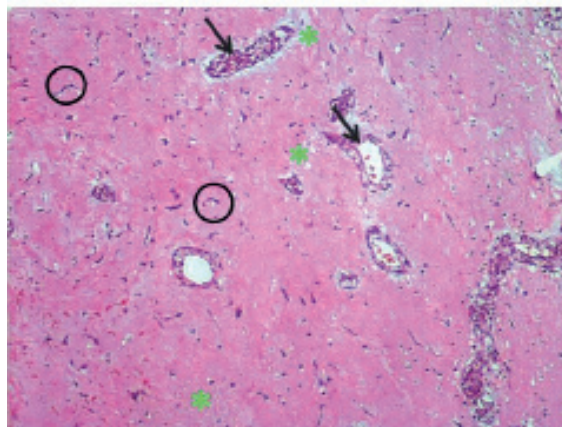
**Table 1. Baseline clinical features of the patients with medical history, symptoms and localizations of the tumors**

Age	Mean (Minimum- maximum)	52.12 (24-75)
Gender	Male	8 (32%)
	Female	17(68%)
Medical history	Hypertension	12 (48%)
	Atrial fibrillation	5 (20%)
	Diabetes mellitus	6 (24%)
	Coronary artery disease	8 (32%)
	Hypothyroidism	2 (8%)
	Inflammatory disease	1 (4%)
	History of cancer	2 (8%)
	Asymptomatic	0
Symptoms and signs at admission	Dyspnea	22 (88%)
	Palpitation	16 (64%)
	Systemic symptoms	10 (40%)
	Cerebral embolism	2 (8%)
	Asymptomatic	0
Localization of the mass	Left atrium	22 (88%)
	Right atrium	2 (8%)
	Aortic valve	1 (4%)

### The symptoms of the patients and preoperative evaluation

The most common symptom was dyspnea (88%). Palpitations were present in 64% of patients. In 52% of patients, shortness of breath and palpitations were together. Systemic symptoms (fever, weakness, anemia, weight loss) were 40% and thromboembolic symptoms were 8%.

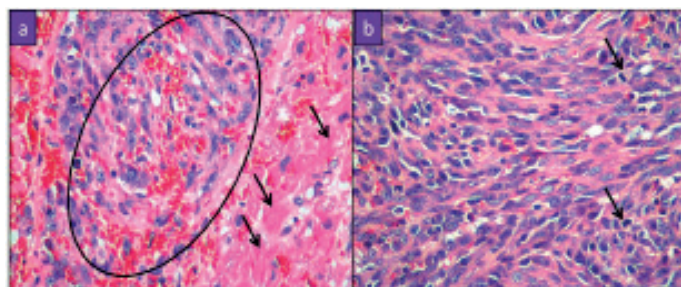
During preoperative period, TEE was performed in 5 patients, cardiac MRI in 4 patients. Coronary angiography was implemented in 17 patients over 40 years age. All patients were operated on average within 48 hours of diagnosis. No complications developed during this period in patients awaiting an operation.



**Figure 1.** Myxoma composed syncytia (circles) and glandular-like structures (arrows) embedded in a myxoid stroma (stars). (H&E: 100x, 200x, respectively).

### Operation information

During surgery, the interatrial septum was closed with primary closure in 23 patients (92%) and pericardial patch in 2 patients (8%). Afterwards, the additional procedure was started. 6 patients underwent coronary artery bypass, 1 patient aortic valve replacement (AVR), 1 patient tricuspid annuloplasty, 1 patient neo-atrium creation. Materials extracted from all patients were sent for pathological examination.



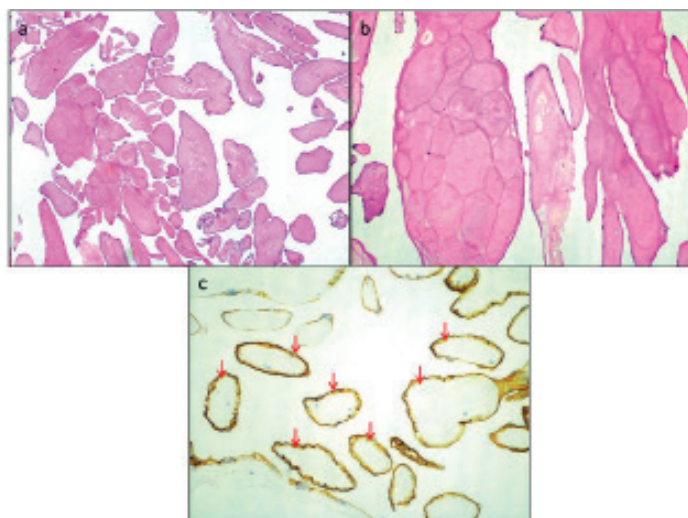
**Figure 2.** Angiosarcoma a: Infiltrative pattern of tumor growth (circle) into the myocardium (arrows). (H&E, 400X). b: Highly pleomorphic tumor cells with spindle-oval hyperchromatic nuclei. Two mitotic figures are demonstrated in this figure (arrows)

### Lesion features

In 22 of 25 patients, the pathology result was reported as atrial myxoma. Hibernoma was detected in 1 patient,

papillary fibroelastoma in 1 patient, and angiosarcoma in 1 patient.

Localizations of the cardiac tumors were as follows. Out of 22 myxomas, 21 of them were in the left atrium and 1 of them was in the right atrium. Of left atrial myxomas, 57 % of the masses was adhered to the fossa ovalis, 20% was in the mitral annulus, 17% was between the two pulmonary vein orifices, 7% was adhered to the left atrium floor. Hibernoma was in interatrial septum, papillary fibroelastoma was on subvalvular surface of aortic valve and angiosarcoma was in right atrium invading into right ventricle. Baseline clinical features and localizations of the cardiac tumors were depicted in Table 1. Histopathologic confirmation of myxoma, angiosarcoma and papillary fibroelastoma were depicted in Figure 1,2,3, respectively.



**Figure 3.** Papillary fibroelastoma. Long, branching papillary structures composed of collagen and elastin, lined by hyperplastic endothelial cells. (H&E, 100X, 200X, respectively). c) Endothelial cells lining the papillary structures display positive immunoreaction with CD34 antibody (arrows), (CD34, 100X)

#### Short-term and long-term follow-up of the patients

The average length of hospital stay of our patients was 5 days, after which they were discharged by suggesting outpatient clinic control. There was no death in the early postoperative period (<30 days). Supraventricular arrhythmia was observed in 5 patients as an early postoperative complication. Re-operation was performed in 2 of 25 patients due to recurrence. Recurrent atrial myxoma was detected in 1 patient in the postoperative 4<sup>th</sup> year and in 1 patient (underwent first operation for myxoma in another hospital) in the postoperative 10<sup>th</sup> year. These patients underwent reoperation and were closed with a pericardial patch.

## DISCUSSION

This study reviewed the surgical treatment of the primary cardiac tumors in a single center.

The results were satisfactory with low recurrence rates. Yin et al demonstrated that 79.47 % of their cardiac tumor

group had pathologically confirmed benign cardiac tumors compared to 16.03% malignant cardiac tumors (1).

Most of the malignant tumors were undifferentiated sarcoma and angiosarcoma in their study.

In our study, benign tumors were detected in 24 of 25 patients (96%). Malignant tumor (angiosarcoma) was detected only in 1 patient (4%). Among the benign tumors, the most common was myxoma (88%). This was a high rate compared to the current literature Hibernoma (4%) was detected in 1 patient and papillary fibroelastoma (4%) was detected in 1 patient.

A study of 23-years' experience of primary cardiac tumors by Li et al indicated that mean age was 50.7 and female ratio in study group 61.3%. Similarly, in our study, 17 women (68%) and 8 men (32%) patients were operated with the diagnosis of cardiac tumor. The average age was 52.12 (6).

Cardiac myxomas mostly originate from the atrium. 75 % originate from the left atrium and 15-20 % from the right atrium. A large part originates from the atrial septum, bounded by the fossa ovalis. Less often they originate from other parts of the atrium (7). Cianciulli et al reported that cardiac myxomas may be located 77.4 % in left atrium, 17 % in right atrium, 1.9 % right ventricle, 1.9 % left ventricle and 1.9 % biatrial (8). In our study, the myxoma was located in the left atrium in 21 patients out of 22 patients.

Cardiac myxomas have generally no obvious clinical symptoms. Asymptomatic cases can be seen as well as sudden cardiac death. Clinical symptoms may vary depending on the location, size, and mobility of the tumor. The most common symptoms are dyspnea and palpitations. Symptoms manifest in the heart cavity where the tumor is located, either by obstruction or by deforming the valve structure to which it is associated. In addition, non-cardiac symptoms can often be detected such as weakness, fever of unknown cause, high sedimentation, weight loss and anemia (9,10). Left atrial myxomas can often cause complaints similar to mitral valve stenosis symptoms, right atrial myxomas can cause pulmonary embolism. Patients who also apply with embolic symptoms can be seen. These include embolic symptoms such as stroke, mesenteric ischemia, splenic or renal infarction, acute leg ischemia (8,11). In our study, dyspnea in 22 of 25 patients (88%), palpitations in 16 (64%), and complaints of both dyspnea and palpitation in 13 patients (52%) were observed. In 2 patients out of 25, first symptom was syncope (8%) and in both of these patients, the tumor was located in the left atrium. Systemic symptoms such as fatigue in 10 of our patients and fever in 8 of the patients accompanied cardiac symptoms.

Echocardiography is the most important diagnostic method used in the diagnosis and imaging of intracardiac masses. It is non-invasive and has 95% sensitivity. TEE can be used to better visualize the intracardiac mass.

TEE has 100% sensitivity. An important advantage of echocardiography and TEE over cardiac catheterization and angiography is that there is no risk of tumor fragmentation and embolization. The diameter, shape, mobility and adhesion of the tumor can be easily displayed (9,10). Echocardiography was performed in all of our patients. TEE was performed as an additional diagnostic method in 5 patients, MRI in 4 patients, and coronary angiographic imaging in 17 patients.

When an intracardiac tumor is diagnosed, excision is required with early surgery regardless of the location, diameter and the presence of symptoms. With early surgery, potential systemic and pulmonary embolization and sudden death risk are tried to be prevented (12). When the diagnosis is made, there is consensus about the surgery as soon as possible. In all of our patients, the operation was performed within 48 hours of diagnosis.

The first myxoma surgery was done in 1954 by Swedish surgeon Clarence Crafoord (13). The main purpose of surgical treatment is to remove the tumor along with the implantation site and a tissue of at least 5 mm diameter without causing embolization. The most commonly used approach is the right atrium and transseptal approach (8). In our study group, the tumor was resected by transseptal entry by entering from the right atrium. It is advantageous, because the tumor can be biatrial and be localized in the septum.

Although cardiac myxomas are mostly sporadic, recurrent familial cases have been published in the literature. The recurrence rate varies between 5-14%. The cause of the recurrence is not fully known, there may be reasons such as tumor incomplete or insufficient excision, intraoperative implantation, embolization, multifocal tumor or subendocardial location of the precursor cells of the tumor (8,9,14,15). In our study, recurrence was detected in 2 patients, one was 4 years after the first operation and the other 10 years after the first operation. However, one of these patients had undergone the first operation in a different hospital.

Concomitant coronary artery disease was also an important issue regarding atrial myxoma operations (16). In our experience, we performed coronary artery bypass grafting in 6 patients in addition to the removal of the tumors.

Primary malignant cells are rarely seen. 75% of malignant tumors are sarcoma. Sarcomas are often found in the right atrium and survival without treatment is limited to several months. The most common type of sarcomas are angiosarcomas and constitute 30% of primary cardiac malignant tumors. It originates from mesenchymal angioblasts and is most common in middle-aged men. In our series, one case of angiosarcoma was detected. Our patient's follow-up continues with radiotherapy and chemotherapy in the first postoperative year (11).

Papillary fibroelastoma is relatively rare benign tumor of heart. It generally involves cardiac valves with white color and gelatinous structure and 1-2 cm in size (17). In our case aortic valve was the involvement site.

Hibernoma is also rare benign tumor originating from brown adipose tissue (18). It is exclusively rare in heart. Interatrial septum is a possible site because of its content of brown adipose tissue (19). Hibernoma was located in interatrial septum in our case.

## CONCLUSION

Treatment of primary cardiac tumors by surgery has satisfactory short and long term results. Majority of these tumors are myxomas with good prognosis and low recurrence rates.

*Competing interests: The authors declare that they have no competing interest.*

*Financial Disclosure: There are no financial supports.*

*Ethical approval: Istanbul Yeni Yuzyl University Clinical Research Ethics Committee (13.08.2020/1391)*

## REFERENCES

1. Yin L, He D, Shen H, et al. Surgical treatment of cardiac tumors: a 5-year experience from a single cardiac center. *J Thorac Dis* 2016;8:911-9.
2. Shah IK, Dearani JA, Daly RC, et al. Cardiac Myxomas: A 50-Year Experience With Resection and Analysis of Risk Factors for Recurrence. *Ann Thorac Surg* 2015 ;100:495-500.
3. Poterucha TJ, Kochav J, O'Connor DS, et al. Cardiac Tumors: Clinical Presentation, Diagnosis, and Management. *Curr Treat Options Oncol*. 2019;20:66.
4. Shapiro LM. Cardiac tumours: diagnosis and management. *Heart* 2001;85:218-22.
5. Esposito A, De Cobelli F, Ironi G, et al. CMR in assessment of cardiac masses: primary benign tumors. *JACC Cardiovasc Imaging* 2014;7:733-6.
6. Li S, Gao Ch. Surgical Experience of Primary Cardiac Tumor: Single-Institution 23-Year Report. *Med Sci Monit* 2017;23:2111-7.
7. Reynen K. Cardiac myxomas. *N Engl J Med* 1995; 333:1610-7.
8. Cianciulli TF, Cozzarin A, Soumoulou JB, et al. Twenty Years of Clinical Experience with Cardiac Myxomas: Diagnosis, Treatment, and Follow Up. *J Cardiovasc Imaging* 2019;27:37-47.
9. Pinede L, Duhaut P, Loire R. Clinical presentation of left atrial cardiac myxoma. A series of 112 consecutive cases. *Medicine (Baltimore)* 2001;80:159-72.
10. Obrenović-Kirčanski B, Mikić A, Parapid B, et al. A 30-year-single-center experience in atrial myxomas: from presentation to treatment and prognosis. *Thorac Cardiovasc Surg* 2013;61:530-6.
11. Hoffmeier A, Sindermann JR, Scheld HH, et al. Cardiac tumors--diagnosis and surgical treatment. *Dtsch Arztebl Int*. 2014;111:205-11.

12. Bortolotti U, Maraglino G, Rubino M, et al. Surgical excision of intracardiac myxomas: a 20-year follow-up. *Ann Thorac Surg* 1990;49:449-53.
13. Chitwood WR Jr. Clarence Crafoord and the first successful resection of a cardiac myxoma. *Ann Thorac Surg* 1992;54:997-8.
14. Larsson S, Lepore V, Kennergren C. Atrial myxomas: results of 25 years' experience and review of the literature. *Surgery* 1989;105:695-8.
15. Lukács L, Lengyel M, Szedő F, et al. Surgical treatment of cardiac myxomas: a 20-year follow-up. *Cardiovasc Surg* 1997;5:225-8.
16. Frequency of left atrial myxoma with concomitant coronary artery disease. Erdil N, Ates S, Cetin L, et al. *Surg Today* 2003;33:328-3.
17. Mariscalco G, Bruno VD, Borsani P, et al. Papillary fibroelastoma: insight to a primary cardiac valve tumor. *J Card Surg* 2010;25:198-205.
18. Keskin H, Özçobanoğlu S, Özbilim G. Mediastinal hibernoma: An uncommon tumor. *Türk Gogus Kalp Damar Cerrahisi Derg* 2019;27:248-55.
19. Di Tommaso L, Chiesa G, Arena V, et al. Cardiac hibernoma: a case report. *Histopathology*. 2012;61:985-7.