

# Fixation of forearm fractures with intramedullary k-wire or elastic nail by fluoroscopy in children and radiation exposure

 Seyhmus Yigit

Department of Orthopaedic Surgery, Faculty of Medicine, Dicle University, Diyarbakir, Turkey

Copyright © 2020 by authors and Annals of Medical Research Publishing Inc.

## Abstract

**Aim:** To show midterm results and compare the two methods utilized in pediatric forearm fractures fixation and the risks of radiation.

**Material and Methods:** We conducted retrospective studies of 62 children and adolescent between the age of 6 to 16 years who were exposed to traumatic forearm fractures and treated with methods of fixation mini open reduction and intramedullary K-wire pinning (group 1) and close reduction and intramedullary elastic nailing (group 2). Patient data included age, gender, the mechanisms of injury, fluoroscopic screening time, dose area product (DAP) value, union time, duration of hospitalization, and complications.

**Results:** There was a significant difference in radiation exposure and radiation-related cancer risk in group 2 ( $P < 0.001$ ). There was no significant difference between the two groups in the first year of surgery compared to union ( $p: 0.49$ ), complications and Price CT et al criteria ( $p: 0,57$ ).

**Conclusions:** If the surgeon's experience is insufficient, the duration of close reduction and intramedullary nailing operation time and the number of fluoroscopic imaging will increase. This will increase the radiation exposure and the risks associated with radiation for the patient and surgical team. In our opinion, surgeons who do not have enough surgical experience should use open reduction technique to avoid using too much fluoroscopic imaging. Orthopedics surgeons must protect himself, his personnel and the patient from radiation exposure.

**Keywords:** Cancer risk; fluoroscopy; fracture healing; pediatric forearm fractures; radiation risk

## INTRODUCTION

Forearm fractures make up about 45% of pediatric fractures (1). It is more common in children aged 6-16 years (2). The most common mechanism is a fall (83%) and direct trauma is a second (10%) (2). There is currently no consensus as to the best method of treatment of forearm fractures. In the pediatric group, closed reduction and cast is the gold standard treatment method for minimally displaced and stable forearm fractures (3).

Recently, the use of fluoroscopy has increased in orthopedic procedures (4). In general, orthopedic surgeons are less conscious about radiation exposure and effects to health, and are insensible to protection (5). Exposure to radiation from intra-operative imaging is a source of risk for patients, surgeons, and other staff (6). The duration of fluoroscopy usage may be increased according to the surgical technique and the experience of the surgeon. A mild radiation dose can cause local skin damage and systemic absorption by body organs, resulting in altered

DNA damage response mechanisms and consequently cellular dysplasia and malignancy (7).

Close reduction and intramedullary elastic (CRIE) nailing (8,9) or mini open reduction and intramedullary K-wire (MOIK) pinning (9) are recognized operative management of diaphyseal forearm fractures and have been reported to be effective methods in treating pediatric midshaft forearm fractures.

If the surgeon's experience is insufficient, the duration of CRIE nailing operation time and the number of fluoroscopic imaging will increase. This will increase the radiation exposure and the risks associated with radiation for the patient and surgical team. We hypothesize that patients, surgeons and other operating room personnel are exposed to ionizing radiation during surgery and the results of two methods of fixation was same at 1 year. This study was performed to compare the result and complications of two methods of fixation and primary goal of the study was to wish to emphasize radiation exposure and risks of radiation-induced diseases.

**Received:** 10.06.2020 **Accepted:** 21.08.2020 **Available online:** 18.09.2020

**Corresponding Author:** Seyhmus Yigit, Department of Orthopaedic Surgery, Faculty of Medicine, Dicle University, Diyarbakir, Turkey

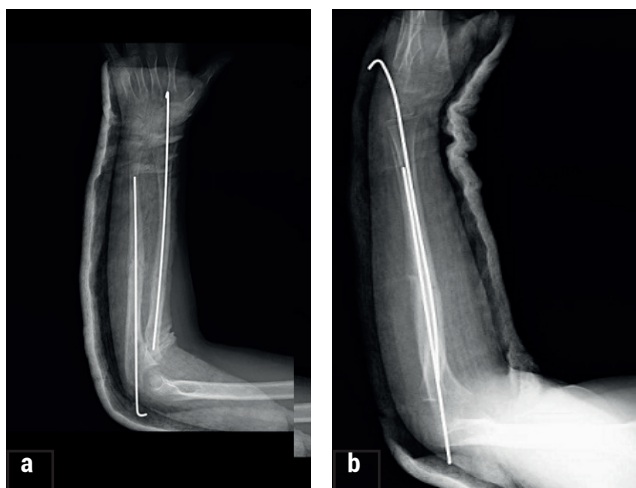
**E-mail:** dryigit8884@hotmail.com

## MATERIAL and METHODS

We conducted retrospective studies of 62 (44 were male and 18 female) children and adolescent between the age of 6 to 16 years who were had to traumatic forearm fractures and treated with methods of mini open reduction and intramedullary K-wire (MOIK) pinning(group 1) and close reduction and intramedullary elastic(CRIE) nailing (group 2). The study was approved by the Ethics Review Committee of our faculty (138 / 07.05.2020). Written informed consent was obtained from all participants. All data were obtained without a personal identification document and made in accordance with the Declaration of Helsinki regulation.

Patient data included age, gender, the mechanisms of injury, operation time, fluoroscopic screening time, dose area product (DAP) value union time, duration of hospitalization, and complications. To be included in the study: 1) patients aged 6–16 years, 2) both-bone forearm fractures (10), 3) failure to obtain or maintain adequate closed reduction (11), 4) Gustilo–Anderson open fractures up to type 3A(12). Patients with inappropriate radiographies, pathological fractures and multiple injuries were excluded from the study. 97 pediatric patients with forearm fractures were examined. We excluded 35 patients who applied other fixation methods and had missing patient data from the study.

Indications for operative treatment at our hospital were unstable, open, comminuted, combined, or failed cooperatively treated fractures. In our hospital, fixation methods with k-wires, titanium elastic nails and plate-screws are performed in appropriate indications for pediatric forearm fractures. In our study, k wire and titanium elastic nail techniques were compared in terms of radiation risks.

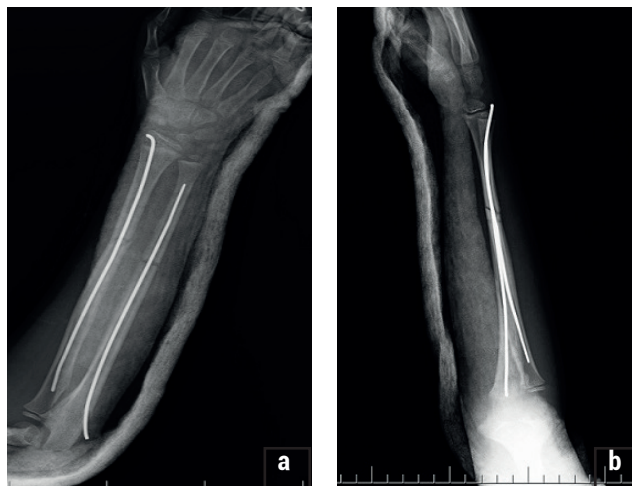

**Figure 1.** (1a-1b) an 11-year-old male was operated with mini open reduction and intramedullary K-wire method

Both surgical techniques were performed under general anesthesia by placing a pneumatic tourniquet in the supine position in the operating room. Open reduction was performed in the K-wire surgical technique (1.0 to 2.0 mm in diameter) and K wires were sent from the broken

ends to antegrade or retrograde. K wires were allowed to cross the physis line and exit the skin. The ends of the K wires were bent with pliers. The ends were cut out with a wire cutter, leaving outside of skin. Wounds were sutured in accordance with anatomy (Figure 1a-1b).

In the elastic nail surgery technique, after closed reduction was performed in the distal radius or proximal ulna, elastic nails were sent antegrade or retrograde. The ends of elastic nails were left under the skin and the wounds were sutured. If closed reduction was not achieved, open reduction was performed. Nails with a diameter of 1.5 mm to 2.5 mm were used depending on the age of the patients and the bone medulla thickness (Figure 2a-2b).



**Figure 2.** (2a-2b) a 10-year-old male was operated with closed reduction and elastic nail method

All patients were immobilized with a splint during the first postoperative 4 weeks. If sufficient healing would see at X-ray, splint had taken out. In our clinic, periodic clinical and radiological evaluation is performed at 2, 4, 6, 8 weeks, 6 and 12 months intervals for all patients. At each visit is taken standard X-rays. Medical conditions of the patients are recorded.

The clinical outcome was rated by a scale used by Price et al. (13). It was considered an excellent result that patients did not complain about exhausting physical activity and loss of the forearm rotation of less than 10°. A mild complaints with exhausting physical activity or an 11° to 30° loss of forearm rotation or both, was considered good result. A mild subjective complaint during daily activities or a loss of 31° to -90° forearm rotation, or both, was considered fair result. All other results were accepted poor.

According to the closed reduction technique, fluoroscopy was used in group 2, but in group 1 it was used 1 to 3 times only to look at the intramedullary placement of the K wires. Dose area product (DAP) is a value used to evaluate the radiation risk from diagnostic X-ray examinations and interventional procedures. DAP not only reflects the dose in the radiation field, but also reflects the irradiated tissue area. DAP and the general fluoroscopic screening time (ET) (minutes) were recorded postoperatively.

We could not directly calculate the radiation concentration stored in the organs and the effective dose (E) (14) that measures the radiation hazard potential in organs. We accepted for every patient that the effective dose equals to the DAP value.  $E = (\epsilon_{AP} \times DAP)$ . International Commission on Radiological Protection (ICRP) publication 103(15), the risk for radiation induced cancers (RC) and detrimental hereditary disorders (RH) could be calculated by the following formulae:  $RC = 0.055 \times E$  (Sv),  $RH = 0.002 \times E$  (Sv).

We performed analysis using standard statistical compute software, that is, Statistical Package for Social Sciences (SPSS, version 24). We used Mann-Whitney test exact to compare categorical data. Data were compared by using P-value of  $<0.05$  was considered to be statistically significant.

## RESULTS

A total number of 62 patients were studied. 28 patients (22 males and 6 females) treated group 1 ((MOIK) pinning) and 34 patients (22 males and 12 females) treated group 2 ((CRIE) nailing ( $p = 0.32$ ). In group 1, eight patients presented with type 1, four patient presented with type 2 and in group 2, ten patients presented with type 1 open fracture. Patient demography and AO classification are given in Table 1.

	Group I	Group II	P value
Age	14 $\pm$ 0.4 years	13 $\pm$ 0.5	0.26
Gender	22m-6f	22m-12f	0.32
AO classification			0.27
22-D/4.1	18	26	
22-D/5.1	6	8	
22-D/5.2	4	0	

Average follow-up time was 54 months (range, 14-76 months). Recorded operative time was on average of group 1 63.5  $\pm$  5.4 minutes, group 2 76.4  $\pm$  4.9 minutes ( $p = 0.07$ ). In group 2 twenty eight patients required open reduction due to a failure in closed reduction and soft tissue interposition. All patients were discharged 1 day after surgery. Mean time to union for all fractures was 8.1 weeks (range, 6-10 weeks) ( $p = 0.49$ ). All fractures healed without delayed union.

According to Price CT et al. (13) criteria, 56 patients (90.4%) had excellent results and 6 patients (9.6%) had good results. None of the patients had fair or poor results ( $p = 0.57$ ) (Table 2). In group 1, K wires were removed in a minor outpatient procedure room (on average of 4.4  $\pm$  0.3 weeks). In group 2, nail implant removed in the operating room in all patients (on average 5.2  $\pm$  0.4 months) ( $p < 0.001$ ). In both groups, splint was applied for 2 weeks after removal of implants. In group 1, joint stiffness occurred because K wires passed through the joint. The patients underwent a

physical therapy program and ROM improved at a mean of 2.1 weeks (1-4 weeks). In group 2, 5 patients were re-fractured after removal of the nail implant. The fractures were treated with closed reduction and plaster without any operation.

Price CT et al. criteria	Group I	Group II	P :0.57
Excellent	26	30	
Good	2	4	

In group 1, fluoroscopy time was on average 0.9  $\pm$  0.4 seconds, DAP was on average 5.2  $\pm$  1.1 cGy  $\times$  cm<sup>2</sup>, Rc was on average 0.2  $\pm$  0.9 Sv, RH was on average 0.02  $\pm$  0.01 Sv. In group 2, fluoroscopy time was on average 46.1  $\pm$  19.3 seconds, DAP was on average 80.2  $\pm$  33.6 cGy  $\times$  cm<sup>2</sup>, RC was on average 4.4  $\pm$  1.8 Sv, RH was on average 0.13  $\pm$  0.7 Sv ( $P < 0.001$ ).

There were twelve pin-tract infection complications which successfully treated with antibiotics in group 1. In group 2, 3 patients had transient anterior interosseous nerve palsy that healed with medical therapy. There was no significant loss of forearm motion. We did not observe any case of compartment syndrome, non-union, rotational deformity, infection, growth-plate arrest.

## DISCUSSION

Mini open reduction and intramedullary K-wire pinning and close reduction and intramedullary elastic nailing are methods of treatment of diaphysis forearm in children. Each method has its own complications. The literature has compared operative outcomes in of diaphyseal forearm fractures in the skeletally immature child but to our knowledge, this study was the first study to compare radiation risk for (MOIK) pinning and (CRIE) nailing techniques in treatment of diaphyseal forearm fractures in children age of 6 to 16 years. Our outcomes were same to our a hypothesis. The results of two methods of fixation was same at 1 year. Repeated fluoroscopic scanning during surgery increases radiation exposure in children. If the surgeries are made according to the surgical technique, if it is not a pathological fracture, fractures in children usually union. When surgeons choose the surgical method, they should not forget the damage of radiation.

Recently, the increasing use of radiation-containing diagnostic and therapeutic medical procedures has raised concerns about the risks of linear low-dose exposure to cancer formation, in particular (16). In intraoperative imaging, ionized radiation causes cellular damage through the stimulation of direct or indirect DNA lesions and the production of reactive oxygen species (7). The linear no-threshold model predicts that 1% of the population will develop cancer or leukemia related to low-level radiation exposure ( $< 100$  mGy) (17). In general, during the use of fluoroscopy, the surgeon and surgical team become anxious about radiation and try to protect

themselves from radiation. The patient cannot escape the harmful effects of radiation. Some studies have shown that the risk of developing malignancy in children is 3-4 times higher than in adults for the same radiation dose (18, 19). Previous studies have shown that children have a high risk of cancer in the first 10 years after exposure (19), and this risk persists for 50 years and longer after exposure (20). Thyroid gland, breast, bone marrow, brain and skin are the most sensitive organs against radiation in children. Minimally invasive surgical techniques are not harmless techniques. The linear dose of carcinogenic effect of radiation in children is 0.1 Gy for thyroid gland, 0.3 Gy for breast, 0.3 Gy for bone marrow, 1.5 Gy for brain, 4.3 Gy for skin (21). In our study, in group 2 the mean DAP was 0.8 Gy and was higher than the thyroid and breast linear dose. If the surgeon's experience is insufficient, the duration of CRIE nailing operation time and the number of fluoroscopic imaging will increase. This will increase the radiation exposure and the risks associated with radiation for the patient and surgical team. Orthopedics surgeons must protect himself, his personnel and the patient from radiation exposure. This requires understanding the principles of ionizing radiation for minimizing exposure risk. In our opinion, surgeons who do not have enough surgical experience should use open reduction technique to avoid using too much fluoroscopic imaging.

Risk factors for post-traumatic growth arrest were showed to be high energy injury, deep infection, multiple reduction attempts, late manipulation at more than 1 weeks post trauma, and over 10 years of age (22,23). Boyden said that in the early closure of physis was related to pin size, its position in physis, angulation in physis, use of grooved pins and time of pinning (24). Hitherto, it has not been clearly shown that transphyseal pins cause growth disruption. Cannata et al. (22) showed that if the difference in length between the forearm bones after forearm fracture was less than 1 cm, it was asymptomatic. In his MRI study, Jeremy showed that fixing the fractures with a transient K-wire through an open physeal will not necessarily lead to a stopping of physiological growth (25). Growth plate arrest was not seen in our study. According to us, standard transphyseal pinning (a single threaded pin) used in epiphysis fractures in children such as supracondylar humerus, distal radius, distal tibia does not cause growth plate arrest.

Fracture union completed in normal biological process without delayed union (26). In their studies, Heare (27) and Calder (28) showed that there was no difference in outcome children forearm fractures between elastic nail and K-wires. Qidwai (29) and Yung (30) showed that fixation with K wire is effective in the treatment of forearm fractures in children. But all of them used fluoroscopy for fixation with K wire. We had 56 patients (90.4%) had excellent results and 6 patients (9.6%) had good results according to Price et al criteria (13). We did not find any significant difference in the union time of fractures, rate of postoperative complications, range of motion of the elbow and wrist between both surgical procedures.

Nail removal recommended in the literature should not be fulfilled before 4 to 6 months after operation, not before complete integration of the fracture occurred (31). We removed the nail implant and the K wire implant at the appropriate time for the literature and there were no complications.

This study has several limitations. First, it is retrospective study, which introduces several potential of bias. For example; standardization was missing. Only the differences between open and closed treatments are compared. However, variables between groups, such as transphyseal / extraphyseal access and the use of different implants, were not excluded. Second, the sample size of 62 patient's remains small, which may have limited the ability of our analysis to demonstrate the relationship between patients, injury, or implant characteristics. Another limitation, several hypotheses were made to estimate the effective dose and disease risk of radiation exposure. Finally, this study had ignored many potentially personal, mechanical, and environmental factors that can affect the effective dose in the course of surgical procedures.

## CONCLUSION

If the surgeon's experience is insufficient, the duration of close reduction and intramedullary nailing operation time and the number of fluoroscopic imaging will increase. This will increase the radiation exposure and the risks associated with radiation for the patient and surgical team. In our opinion, surgeons who do not have enough surgical experience should use open reduction technique to avoid using too much fluoroscopic imaging. Orthopaedics surgeons must protect himself, his personnel and the patient from radiation exposure.

*Competing interests: The authors declare that they have no competing interest.*

*Financial Disclosure: There are no financial supports.*

*Ethical approval: The approval number 135 / 07.05.2020 was approved by the Dicle University Ethics Committee.*

## REFERENCES

1. Parajuli NP, Shrestha D, Dhoju D, et al. Intramedullary nailing for pediatric diaphyseal forearm bone fracture. Kathmandu Univ Med J 2011;9:198-202.
2. Cheng JC, Ng BK, Ying SY, Lam PK. A 10-year study of the changes in the pattern and treatment of 6493 fractures. J Paediatr Orthop 1999;19:344-50.
3. Flynn JM, Kristofer JJ, Matthew RG, Goebel J. Eleven years experience in the operative management of pediatric forearm fractures. J Pediatr Orthop 2010; 30:313-9.
4. O'Rourke PJ, Crerand S, Harrington P, Casey M, Quinlan W. Risks of radiation exposure to orthopaedic surgeons. J R Coll Surg Edinb 1996;41:40-3.
5. JK Jain, RK Sen, SC Bansal. Image intensifier and the orthopedic surgeon. Ind J Orthop 2001;35:13-9.

6. Rajesh KB, Sharon G, Meghann O, et al. Surgeon and patient radiation exposure in minimally invasive transforaminal lumbar interbody fusion. *J Neurosurg Spine* 2008;9:570-3.
7. William FM, Joseph PD, Mark IK, et al. Genomic instability induced by ionizing radiation. *Radiat Res* 1996;146:247-58.
8. Amit Y, Salai M, Chechik A, et al. Closing intramedullary nailing for the treatment of diaphyseal forearm fractures in adolescence: a preliminary report. *J Pediatr Orthop* 1985;5:143146.
9. Austin H , Dawn GI, Matthew B, et al. Intramedullary Implant Choice and Cost in the Treatment of Pediatric Diaphyseal Forearm Fractures. *J Orthop Trauma* 2017; 31:334-8.
10. Slongo TF, Audigé L, AO. Pediatric Classification Group Fracture and dislocation classification compendium for children: the AO pediatric comprehensive classification of long bone fractures (PCCF) *J Orthop Trauma* 2007;21:135-60.
11. Joost WC , Jan HA , Max R , et al. Which factors affect limitation of pronation/supination after forearm fractures in children? A prospective multicentre study. *Injury* 2014;45:696-700.
12. Gustilo RB, Simpson L, Nixon R, Ruiz A, Indeck W. Analysis of 511 open fractures. *Clin Orthop Relat Res* 1969;66:148-54.
13. Price CT , Scott DS, Kurzner ME, Flynn JC. Malunited forearm fractures in children. *J Pediatr Orthop* 1990; 10:705-12.
14. Reza F , Harlan MK, Yongfei W, et al. Exposure to low-dose ionizing radiation from medical imaging procedures. *N Engl J Med* 2009;36:849-57.
15. The 2007 recommendations of the International Commission on Radiological Protection. ICRP publication 103. *Ann ICRP* 2007;37:1-332.
16. United Nations Scientific Committee on the Effects of Atomic Radiation Sources and Effects of Ionizing Radiation, UNSCEAR 2013 Report to the General Assembly, with Scientific Annexes. New York, NY: United Nations Publications 2013.
17. Huda W. Kerma-area product in diagnostic radiology. *AJR* 2014;203:565-9.
18. Andreassi MG, Ait-Ali L, Botto N, et al. Cardiac catheterization and long-term chromosomal damage in children with congenital heart disease. *Eur Heart J*. 2006;27:2703-8.
19. Committee to Assess Health Risks from Exposure to Low Levels of Ionizing Radiation. Nuclear and Radiation Studies Board, Division on Earth and Life Studies. National Research Council of the National Academies. Health Risks from Exposure to Low Levels of Ionizing Radiation: BEIR VII Phase 2. The National Academies Press; Washington, DC: 2006.
20. Veiga LH, Holmberg E, Anderson H, et al. Thyroid cancer after childhood exposure to external radiation: an updated pooled analysis of 12 studies. *Radiat Res* 2016;185:473-84.
21. Kleinerman RA. Cancer risks following diagnostic and therapeutic radiation exposure in children. *Pediatr Radiol* 2006;36:121-5.
22. Giuseppe C , Fernando DM, Federico M, et al. Physeal fractures of the distal radius and ulna: long-term prognosis. *J. Orthop. Trauma* 2003;17:172-9.
23. Shirzad H , Anette KH, Morten SL, et al. Remodeling of Salter-Harris type II epiphyseal plate injury of the distal radius. *J Pediatr Orthop* 2004;24:472-6.
24. Boyden EM, Peterson HA. Partial premature closure of the distal radial physis associated with Kirschner wire fixation. *Orthopedics* 1991;14:585-8.
25. Jeremy TS, James R, Waters PM. The Effect of Pinning Across the Physis for Stabilization of Fractures in Children: An MRI Evaluation <https://pdfs.semanticscholar>.
26. Dokmeci MO, Kalender AM, Sevimli R, et al. The effect of ibandronate on fracture healing in rat tibia model. *SM J Orthop* 2016; 2:1041.
27. Heare A, Dawn G, Matthew B, Corey Beebe, et al. Intramedullary Implant Choice and Cost in the Treatment of Pediatric Diaphyseal Forearm Fractures. *J Orthop Trauma* 2017; 31:334-8.
28. Calder PR, P Achan, M Barry. Diaphyseal Forearm Fractures in Children Treated With Intramedullary Fixation: Outcome of K-wire Versus Elastic Stable Intramedullary Nail. *Injury* 2003;34:278-82.
29. Qidwai SA. Treatment of Diaphyseal Forearm Fractures in Children by Intramedullary Kirschner Wires. *J Trauma* 2001;50:303-7.
30. Yung PS, Lam CY, Ng BK, et al. Percutaneous transphyseal intramedullary Kirschner wire pinning: a safe and effective procedure for treatment of displaced diaphyseal forearm fracture in children. *J Pediatr Orthop*. 2004;24:7-12.
31. Makki D, Kheiran A, Gadiyar R, et al. Refractures following removal of plates and elastic nails from paediatric forearms. *J Pediatr Orthop B*. 2014;23:221-6.