




A case of gliosarcoma in a child with neurofibromatosis type 1

 Gulec Mert Dogan¹,  Ahmet Sigirci¹,  Aslinur Cengiz¹,  Mehmet Fatih Erbay²,  Hasan Gokce³

¹Department of Pediatric Radiology, Faculty of Medicine, Inonu University, Malatya, Turkey

²Department of Radiology, Faculty of Medicine, Inonu University, Malatya, Turkey

³Department of Patology, Faculty of Medicine, Inonu University, Malatya, Turkey

Copyright © 2020 by authors and Annals of Medical Research Publishing Inc.

Abstract

Gliosarcoma (GS) is a rarely seen form of glioblastoma. These tumors are mostly seen in males older than 60 years of age. It is extremely rare in pediatric central nervous system (CNS) tumors. In this case report, we present a 3-year-old boy with a giant gliosarcoma. Magnetic resonance (MR) imaging and histopathologic findings are discussed. A 3 year-old boy with a clinically diagnosed NF-1 was admitted to the emergency department with a complaint of intractable vomiting. Magnetic resonance imaging (MRI) of the brain was suggestive of a large lobulated mass lesion in the left parietal lobe extending to the vertex and slightly compressing the left lateral ventricle. The final histopathologic diagnosis of the tumor was considered as gliosarcoma. To our knowledge, this case constitutes the first youngest case with neurofibromatosis type 1 reported in the literature in all pediatric cases of GS.

Keywords: Gliosarcoma; magnetic resonance imaging; neurofibromatosis 1

INTRODUCTION

Gliosarcoma (GS) is a rarely seen form of glioblastoma, containing gliomatous and sarcomatous elements (1). It is considered as a variant of glioblastoma and as a grade 4 tumor according to World Health Organisation (WHO) classification (2). Gliosarcomas are extremely rare in pediatric population. These tumors are mostly seen in males older than 60 years of age (1). Although the relative frequency of pediatric GS among glioblastoma is 1.9%, it is extremely rare in pediatric central nervous system (CNS) tumors with a relative frequency 0.5% (3).

In this case report, we present a 3-year-old boy with a giant gliosarcoma. Magnetic resonance (MR) imaging and histopathologic findings are discussed.

To our knowledge, this case constitutes the first youngest case with neurofibromatosis type 1 reported in the literature in all pediatric cases of GS.

CASE REPORT

A 3 year-old boy with a clinically diagnosed NF-1, who had been under control since he was 5 months old because of multiple café au lait lesions was admitted to the emergency

department with a complaint of intractable vomiting. He had no other complaints such as weight loss or fever. The neurologic examination of the patient was normal. There were no pathological findings in his brain MRI 1 year ago. His sister had died because of a renal tumor.

Magnetic resonance imaging (MRI) of the brain was suggestive of a large lobulated mass lesion measuring 6 × 5,5 × 5 cm in the left parietal lobe extending to the vertex and slightly compressing the left lateral ventricle. The lesion was mildly hypointense compared to gray matter in T1 weighted images and heterogeneous hyperintense in T2 weighted images (figure 1). There were T1 hyperintense, T2 hypointense focuses at the central part of the lesion suggesting hemorrhage (figure 1). Following administration of intravenous contrast there was significant enhancement of the lesion except the central portion (figure 2). On diffusion weighted images (DWI), the central part of the tumor was hypointense whereas the periphery of the tumor was hyperintense (Figure 3). On apparent diffusion coefficient (ADC) images the periphery of the lesion was hypointense indicating diffusion restriction (figure 3). The mean (SD) ADC value calculated from the periphery of the lesion was 0.84 × 10⁻³ mm²/s (Figure 4).

Received: 11.02.2020 **Accepted:** 24.03.2020 **Available online:** 26.08.2020

Corresponding Author: Gulec Mert Dogan, Department of Pediatric Radiology, Faculty of Medicine, Inonu University, Malatya, Turkey

E-mail: asigirci@gmail.com

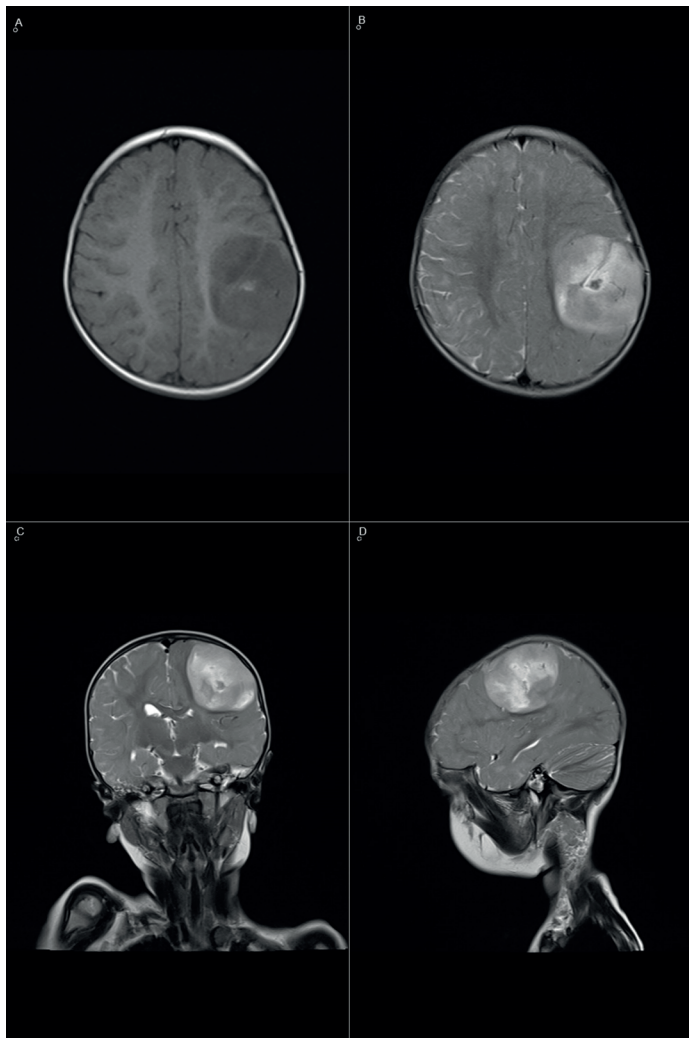


Figure 1 A. Axial T1-weighted image B. Axial T2-weighted image C. Coronal T2-weighted image D. Sagittal T2-weighted image. A 6 × 5.5 × 5 cm lesion in the left parietal lobe, mildly hypointense in T1 weighted images and heterogeneous hyperintense in T2 weighted images. T1 hyperintense, T2 hypointense focuses at the central part of lesion

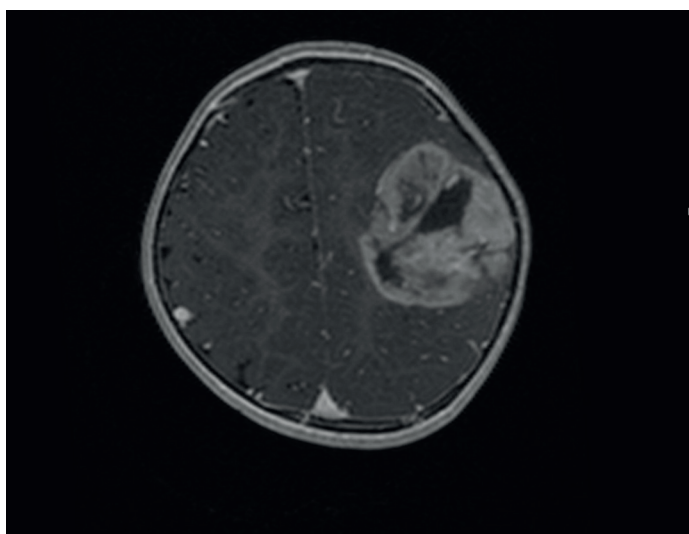


Figure 2. Axial postcontrast T1-weighted image
Significant enhancement of the lesion except the central portion

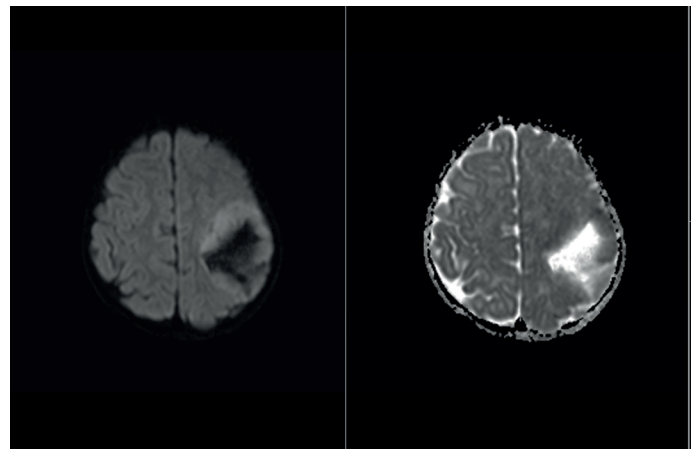


Figure 3. Diffusion-weighted image (DWI).
There is a diffusion restriction at the periphery of the lesion

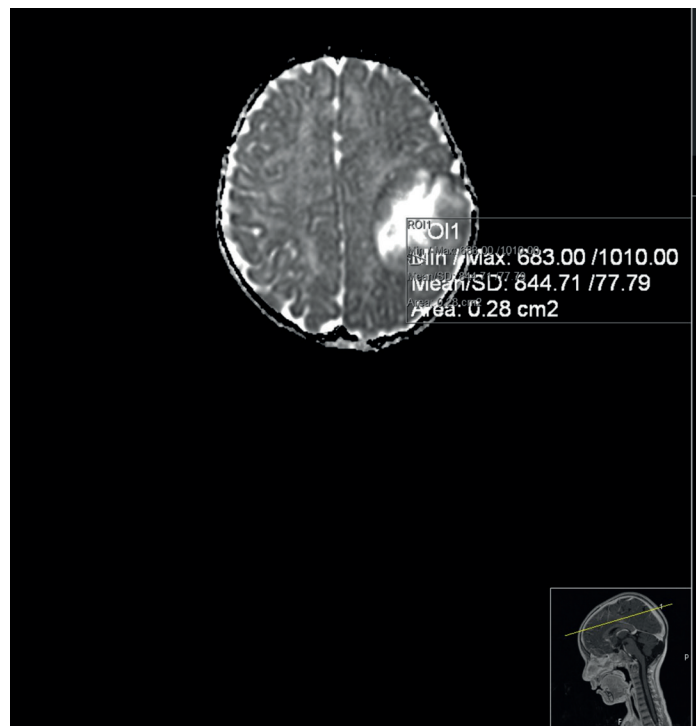


Figure 4. Apparent diffusion coefficient (ADC) images

After palliative surgical resection of the tumor, a highly cellular tumor containing neoplastic cells with neurophylic stroma, narrow cytoplasm and big vesicular hyperchromatic nuclei was seen in histopathologic examination (Figure 5a). There were cells with gemistocytic nature and prominent atypical multinucleated cells in the tumor (Figure 5b). Necrotic areas and atypical mitotic figures were also seen (figure 5 c). There were tumor cells with relatively more elongated cytoplasm aligning like fascicles, suggesting mesenchymal differentiation. GFAP (Figure 6a), smooth muscle actin (50%) (figure 6 b), INI-1, S-100 were stained positive and Myogenin, chromogranin A, NSE, PanCK were stained negative in immunohistochemical staining. The Ki-67 proliferation index was approximately 80% (Figure 6c). The final histopathologic diagnosis of the tumor was considered as gliosarcoma.

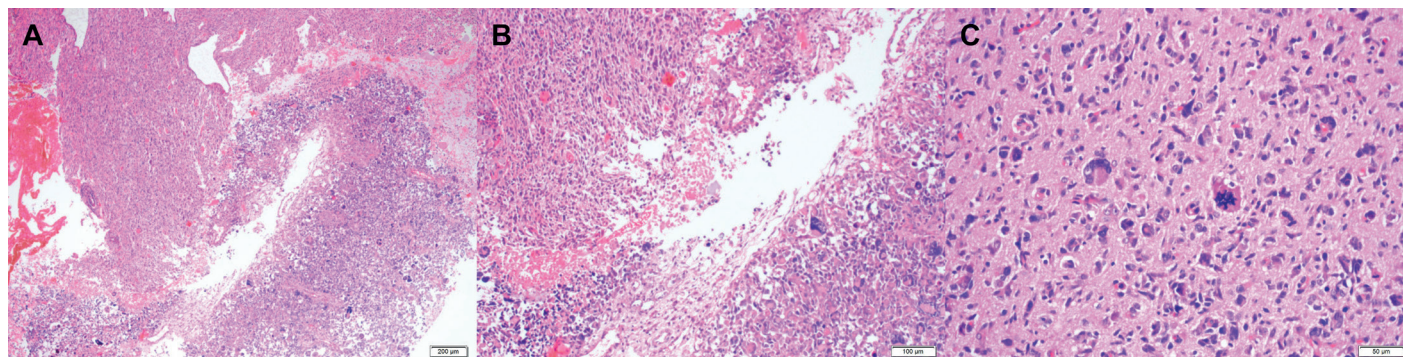


Figure 5. A. H&Ex40; Neoplastic cells with neurophylic stroma, narrow cytoplasm and big vesicular hyperchromatic nuclei, B. H&Ex100; Cells with gemistocytic nature and atypical multinucleated cells, C. H&Ex200; Necrotic areas and atypical mitotic figures

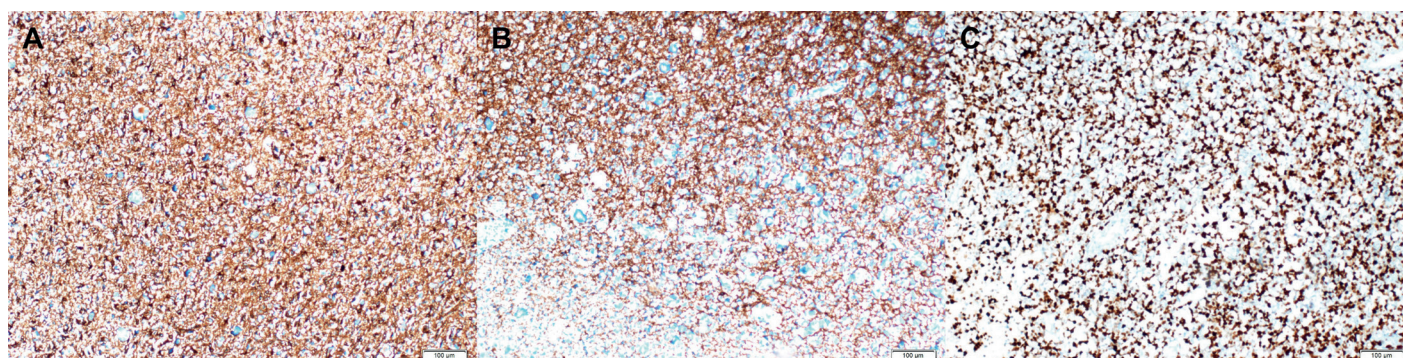


Figure 6. Immunohistochemical staining A; GFAPx100, B; SMAx100, C; Ki-67x100

Chemoradiotherapy was planned for the further treatment. The family of the patient had given an informed consent for participation in this study.

DISCUSSION

Gliosarcoma is a mixed tumor consisting of gliomatous and sarcomatous elements, which was formerly considered sarcomatous form of glioblastoma (1). After the introduction of the new WHO classification (4) it is now classified as gliosarcoma. This tumor usually occurs in adults and older age and also very rare in children (1). When we searched the literature, we found only 25 pediatric cases and the average age of these cases was eleven (5). As a result of our research, we saw that this case constitutes one of the two youngest cases reported in all pediatric cases of GS. The former case reported was also a 3 year old child with GS in suprasellar localization (6).

On the other hand, CNS neoplasms can be seen in patients with neurofibromatosis type 1 (NF 1) which is a relatively common hereditary syndrome. The most common tumors accompanying NF 1 are the pilocytic astrocytomas (7). Gliosarcomas with NF-1 have rarely been reported. To date, 4 cases have been reported in the English written literature (8). Our patient is the youngest reported patient with NF-1 accompanying gliosarcoma in the literature.

Reported MR imaging characteristics of gliosarcoma in cerebral hemispheres are variable (9). In T2 weighted

images, these tumors are generally isointense with graymatter. Because of the necrosis and the hemorrhage, in T1 and T2 weighted images heterogeneous appearance can also be observed. The tumor in our patient was heterogeneous hyperintense in T2 weighted sequences due to hemorrhage. In high-grade gliomas and metastases, the apparent diffusion coefficient values range between $0.82 \times 10^{-3} \text{ mm}^2/\text{s}$ and $1.4 \times 10^{-3} \text{ mm}^2/\text{s}$ (10). The calculated mean ADC value from the peripheric region of the tumor was $0.84 \times 10^{-3} \text{ mm}^2/\text{s}$ in our case suggesting a high-grade tumor.

CONCLUSION

In conclusion, we can say that, if the brain tumors are radiologically high-grade in children with neurofibromatosis type 1, gliosarcoma should be considered.

Conflict of interest: The authors declare that they have no competing interest.

Financial Disclosure: There are no financial supports.

Patient informed consent : The family of the patient had given an informed consent for participation in this study.

REFERENCES

1. Salvati M, Caroli E, Raco A, et al. Gliosarcomas: analysis of 11 cases: do two subtypes exist? J Neurooncol 2005;74:59-63.
2. Louis DN, Ohgaki H, Wiestler OD, et al. The 2007 WHO classification of tumors of the central nervous system.

- Acta Neuropathol 2007;114:97-109.
3. Ravisankar S, Chander RV, Devadoss PK, et al. Pediatric gliosarcoma with fibrosarcomatous differentiation: Report of a rare case. Indian J Pathol Microbiol 2012;55:521-4.
 4. Jaffe ES, Harris NL, Stein H, Vardiman JW, eds. World Health Organization Classification of Tumours: Pathology and Genetics of Tumours of Haematopoietic and Lymphoid Tissues. Lyon, France: IARC Press; 2001. P. 439.
 5. Savant HV, Balasubramaniam S, Mahajan V. Giant parietal lobe infantile gliosarcoma in a 5-year-old child. J Pediatr Neurosci 2015;10:159-61.
 6. Sanal HT, Bulakbasi N, Kocaoglu M, et al. Giant infantile gliosarcoma: magnetic resonance imaging findings. J Child Neurol 2008;23:926-9.
 7. Mario Jr FJ, Ramsby G. Magnetic resonance imaging lesion analysis in neurofibromatosis type 1. Arch Neurol 1998;55:500-5.
 8. Elmaci L, Kurtkaya O, Boran B, et al. Gliosarcoma associated with neurofibromatosis type I: a case report. Tumori 2001;87:60-3.
 9. Alatakis S, Stuckey S, Siu K, et al. Gliosarcoma with osteosarcomatous differentiation: review of radiological and pathological features. J Clin Neurosci 2004;11:650-6.
 10. Bulakbas, N, Onguru O, Erdogan E, et al. Magnetic resonance imaging characteristics of a gliosarcoma. Riv Neuroradiologia 2005;18:59-63.