

Current considerations and criticism for childhood abdominal tuberculosis with our seven cases experiences

 Ozgur Caglar¹,  Kutlug Sinmaz²,  Mustafa Ozcatal²,  Binali Firinci¹,  Taylan Celik³,
 Huriye Gozde Muhafiz Ozsu⁴,  Semsi Guliz Yilmaz⁵

¹Ataturk University, Faculty of Medicine, Department of Pediatric Surgery, Erzurum, Turkey

²Kayseri Research and Training Hospital, Clinic of Pediatric Surgery, Kayseri, Turkey

³Kayseri Research and Training Hospital, Clinic of Pediatric Infectious Diseases, Kayseri, Turkey

⁴Bodrum State Hospital, Clinic of Pathology, Mugla, Turkey

⁵Yeni Yuzuil University, Faculty of Medicine, Gaziosmanpasa Hospital, Department of Radiology, Istanbul, Turkey

Copyright © 2020 by authors and Annals of Medical Research Publishing Inc.

Abstract

Aim: Childhood abdominal tuberculosis is frequently diagnosed as an acute abdomen and operate in veiny. Milky way, like appearance on X-ray/computerized tomography get, should be thanked for tuberculosis. Direct microscopic and consecutive histopathologic examination of endoscopic aspiration material is to be the first approach of such patients.

Materials and Methods: We retrospectively examined primary abdominal tuberculosis owned seven cases diagnosed with clinical, radiological, microbiological, and evenly histopathological methods in five years duration. All of them examined with laparotomy to direct visualization, lymph node biopsy, culture material, appendectomy, and clean of pathologic materials. Antituberculous treatment was begun following surgery.

Results: Historical examination knowledge as that one of the patient's mother treated for active tuberculosis, the others have abdominal lymphadenitis. Mesenteric lymphadenomegaly and peritoneal fluid collection detected all patients; but appendicitis (n=1) and mesenteric inflammation (n=1) diagnosed additional pathologies by ultrasonography and computed tomography. None of them have thoracic involvement. The peritoneal culture was positive in one patient. Lymph node biopsy proved caseification necrosis. Specific whitish tubercles and lymph nodes observed during surgery of six patients. Histopathological diagnosis was tuberculosis of all patients. All patients completely healed with surgery plus anti-tuberculosis therapy without complications.

Conclusion: Effective radiological, microbiological, and histopathological examinations are essential for current diagnosis for abdominal tuberculosis, although it is very rare. Laparotomy/laparoscopy should be done for urgent, complicated, and undiagnosed cases for early treatment to reduce of morbidity, mortality, and complications.

Keywords: Abdominal tuberculosis; tuberculosis in a child; tuberculous lymphadenitis

INTRODUCTION

Tuberculosis (TB) has continued to be a significant cause of morbidity and mortality in the modern era, although it has been considered as an eradicated disease (1). TB had higher prevalence in Greece and Egypt before the advent of antituberculous therapy in 1946 (2). Unfortunately, nobody aware of the silent attack of tuberculosis responsible for 1 to 3 million deaths per year until the World Health Organization declaration in 2013 (3). Many organs affected in slow progression and mortality are inevitable if TB diagnosed and treated with timely (4). TB bacilli enter either hematogenous from lungs or direct intestinal way (1). TB bacilli mostly infect the peritoneum, mesenteric lymphatic system, intestine, and solid visceral organs (5). Although abdominal TB mostly presented with an

acute abdomen (6). TB should be suspected with positive family history, Milky Way abdomen appearance in current radiological, microbiological and histopathological and also laparoscopic examinations. Although TB treatment should be ordered as medical, surgery could be required for complicated cases. We presented and discussed under the current literature with seven difficult childhood cases with abdominal TB

MATERIAL and METHODS

The study was approved by the ethics committee of Ataturk University Faculty of Medicine (07.06.2018/05-20). Informed consent was obtained from all the patients. Seven patient's information was collected from our hospitals documents retrospectively between 2012 and

Received: 16.01.2020 Accepted: 14.02.2020 Available online: 23.05.2020

Corresponding Author: Ozgur Caglar, Ataturk University, Faculty of Medicine, Department of Pediatric Surgery, Erzurum, Turkey

E-mail: drozgurcaglar@gmail.com

2017. Historical, physical examination findings, laboratory-radiological-histopathological results were recorded and analyzed. Patients with chronic diseases were excluded from the study. The diagnosis was confirmed with collected data. Polymerase Chain Reaction (PCR) examination was not performed in all patients, because TB was not the first pathology in the differential diagnosis options; however, all patients underwent a TB culture examination and were treated with quadruple anti-TB therapy in the department of pediatric infectious diseases. In what follows, the data are expressed as mean \pm SD.

RESULTS

Seven patients had typical peritoneal TB: five girls and two boys with a mean age of 11.5 years (range 7 to 17 years). Although abdominal pain and weight loss were the most common complaints of all patients (100%), four patients (44%) have acute abdominal discomfort, one (11%) have fever resistant to medical therapy, one of them (11%) suffered from chronic abdominal pain and the last patient's mother (11%) treated with anti-TB therapy for active TB. The mean duration of symptoms was 12.6 \pm 11.3 (0.3–30) days. Thoracic involvement was not detected in patients (Table 1).

On admission, six of the patients had Bacillus Calmette–Guérin (BCG) scars; the remaining patient, a refugee from Syria, did not have the scar and had no positive family history of TB. The tuberculin skin test (TST) was negative in six patients; the patient who tested positive had an induration measuring 21 \times 25 mm. None of the seven patients had a cough or concomitant thoracic involvement. The most common abdominal ultrasonography (USG) finding was peritoneal fluid and lymphadenopathy. The appearance of lymphadenopathy was cystic in one patient, calcified in two patients, and hypoechoic in the remaining four patients. Lymph node lengths were between 1 cm and 3.5 cm. In addition, USG showed appendicitis in one patient and mesenteric inflammation in another patient. Computed tomography (CT) was performed on Patients 2, 6, and 7 for differential diagnosis. The CT reports revealed calcified, conglomerated, and/or necrotic lymph nodes and fluid (Figure 1).

The mean white blood cell level of all patients on admission was $10.6 \times 10^3/L$ (ranging from $5.6 \times 10^3/L$ to $28,550 \times 10^3/L$), and the mean platelet count was $454.571 \times 10^3/L$ (ranging from $281 \times 10^3/L$ to $593 \times 10^3/L$). Serum biochemistry was checked in five of the patients, four of whom were found

Table 1. Demographic data and clinical presentation of 7 children

Patients	Age/Sex	Period/ Complaints (Days)	Complaints	Physical Examination	Contact with Tbc	USG	CT	Surgery
1	17/M	1D	Pain Vomiting Weightloss Fever	Acute abdomen	No	LAP Peritoneal fluid	Not Performed	Appendectomy LN Bx
2	17/M	7D	Pain Vomiting Weightloss Fever	Acute abdomen	No	LAP Peritoneal fluid	LAP Peritoneal fluid	Appendectomy LN Bx
3	9/F	10D	Pain Vomiting Weightloss Fever	Acute abdomen	No	LAP Peritoneal fluid Mesentery inflammation	Not Performed	Appendectomy LN Bx
4	8/F	20D	Pain Weightloss	Non specific	Yes/mother	LAP Peritoneal fluid	Not Performed	Appendectomy LN Bx
5	7/F	21D	Pain Weightloss Fever	Non specific	No	LAP Peritoneal fluid	Not Performed	Appendectomy LN Bx
6	9/F	1D	Pain Vomiting Weightloss Fever	Acute abdomen	No	LAP Peritoneal fluid Appendicitis	LAP Peritoneal fluid	Appendectomy LN Bx
7	14/F	30D	Pain Weightloss	Non specific	No	LAP Peritoneal fluid	LAP Peritoneal fluid	LN Bx

LAP: Lymphadenopathy, LN Bx: Lymph Node Biopsy

to be within normal parameters. Total bilirubin of 2.0 mg/L and direct bilirubin of 0.6 mg/L were found in one patient, who developed hypoalbuminemia and hypoproteinemia in the early postoperative period. Serum C-reactive protein concentration was checked in five cases and found to be 121 mg/L, 4.6 mg/L, 18 mg/L, 3.17 mg/L, and 10.5 mg/L.

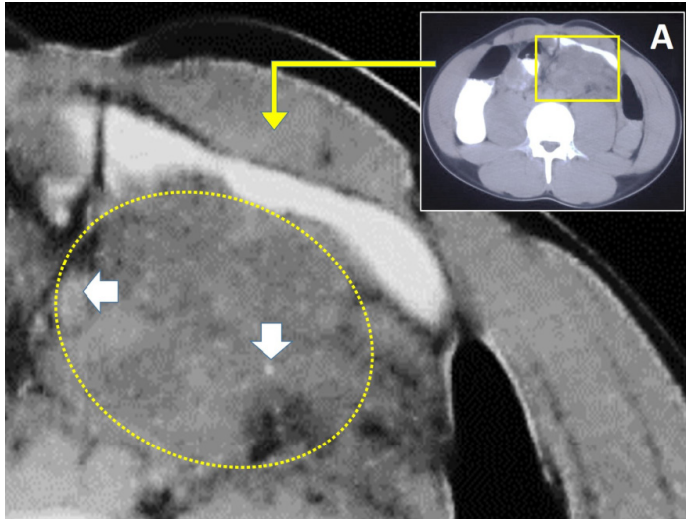


Figure 1. Computed tomography view, calcified, conglomerated, lymph nodes (A), and magnified form (Base)

The peritoneal fluid examination was performed in all seven patients. Acid fast staining (AFS) was positive in Patient 3, whose observations from clinical and surgical exploration were suspicious. The Mycobacterium tuberculosis culture was also positive in this patient's drain fluid, although it could not be incubated or generated in other cultures.

Laparotomy was performed on all seven patients. The most common finding consisted of whitish tubercles in conglomerated lymph nodes (Figure 2/Base). Four patients were operated on for acute abdomen conditions, including abdominal lymphadenopathy and fluid and inflammation and thickening of the peritoneum and omentum. At surgery, appendixes appeared inflamed, except in those patients who were operated on for chronic abdominal pain. In addition to mesenteric lymphadenomegaly, 6 patients with omental adhesions and inflammation in the appendix underwent an appendectomy. Since a patient who was followed up due to nonspecific abdominal pain could not be diagnosed with laboratory tests, an operation decision was made for diagnostic lymph node biopsy. This patient did not undergo appendectomy.

On the third day after surgery, Patient 3 deteriorated clinically and was transferred to an intensive care unit. The amount of ascitic drain fluid in her abdomen increased, with dehiscence of the surgical incisions as a result.

Biopsy samples obtained from the seven patients revealed caseating granulomatous lymphadenitis, and the definitive diagnosis of peritoneal TB was confirmed histopathologically in all seven (Figure 2/A).

All patients were started on quadruple anti-TB therapy consisting of isoniazid 10–15 mg/kg 1 × 1, rifampicin

30–40 mg/kg 1 × 1, pyrazinamide 30–40 mg/kg 1 × 1, and ethambutol 15–25 mg/kg 1 × 1. The pyrazinamide and ethambutol therapies were completed in the second month, and the isoniazid and rifampicin therapies were completed at the end of the first year of medical treatment. Five patients completed the therapy, recovered without any complications, and were in good health at the follow-up; the other two patients received the same medication and responded well after six months. All patients successfully completed the therapy without any complications, and all were found to be healthy at their routine polyclinic controls.

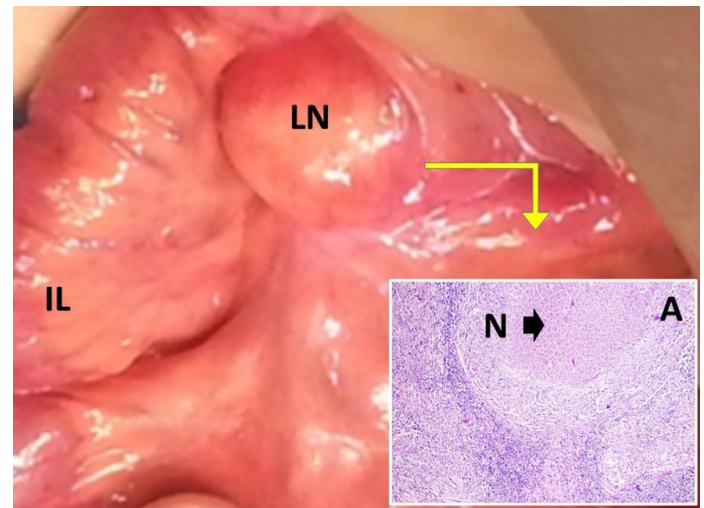


Figure 2. Laparotomy view of ileum (IL), caseified lymph node (LN) (Base), central caseification necrosis (N) in lymph node (A)

DISCUSSION

No matter how medicine develops, tuberculosis will present with different insidious attacks. Indeed, WHO has reported a significant increase in 2013 in recent years (3). TB is a slowly progressing multiorgan disease and sometimes can be fatal if not treated in a timely manner (4). A multicenter study reported that the prevalence of abdominal TB as 4.3% in Turkey (5). Since tuberculosis is interpreted as a lung disease, we think that abdominal tuberculosis is frequently missed especially from this perspective. Interestingly incidence of TB peritonitis is 0.1% to 3.5% with pulmonary TB and 4% to 10% in extrapulmonary TB (6).

TB bacilli enter to body via respiratory and alimentary tract invade, especially lung, intestinal tract, and also all organs. The peritoneum, mesenteric lymph nodes, genitourinary tract or other solid organs are frequently invaded by TB bacilli in the abdomen (7-9). The clinical presentation of abdominal TB can be presented with acute, chronic, or acute on chronic abdominal discomfort (10). Generalized TB peritonitis may be subclinical presentation originated from local or generalized hematogenous dissemination (11).

Although pulmonary and pleural involvement has been thought as the main source of abdominal TB (12) chest X-rays were normal limits in our seven patients. TB

peritonitis mostly affect young men, especially children with uncommon presentation. When TB may be a subclinical status, generalized peritonitis may occur as a result of miliary hematogenous dissemination (11). The most common presentations of tuberculous peritonitis are fever, abdominal pain, and/or discomfort, distension, and weight loss (13). Colic pain owing to luminal compromise or dull and continuous pain originated from mesenteric lymph nodes involvement (10).

The frequent cause of localized peritonitis is simple dissemination from abdominal lymph nodes or genitourinary tract with the triad of abdominal pain such as abdominal swelling/ascites, and fever (14). Detailed family histories should be obtained if patients suffered from chronic abdominal discomfort, especially in endemic areas, because 60% of children with tuberculous peritonitis have positive family history of TB (1).

Chest X-ray, USG, and CT are essential for when abdominal TB is suspected. The most common USG and CT findings are abdominal ascites (79%), lymphadenopathy (35%), thickened omentum (29%), and intestinal loops (25%) (2). A diagnosis of abdominal TB classically requires microbiological and culture confirmation of the presence of *M. tuberculosis*; the presence of acid-fast bacilli is another diagnostic criterion. Unfortunately, microbiological isolation of the agent is very rare for patients with abdominal TB. Rates have remained under 50% in all reported studies (10,15,16).

As a result of this difficulty in determining the presence of *M. tuberculosis*, many clinicians need correct histopathologic diagnosis (2). In the current study, the diagnosis was made histopathologically in all (100%) patients; however, pediatricians need histopathological results for differential and definitive diagnosis of our three patients (42%). A patient presented with acute abdomen signs was undergone appendectomy, but surgeons noticed that TB could be possible diagnosis and lymph node biopsy results proved their intraoperative diagnosis after surgery (Case 3), although clinical, physical, and laboratory findings indicated perforated appendicitis. The patient condition deteriorated after surgery despite empiric acute abdomen treatment until histopathological diagnosis confirmed of abdominal TB. As soon as the diagnosis of tuberculosis became clear, anti-tuberculosis treatment was started, and the patient rapidly recovered.

Although laparoscopy is the first advised method, it should be confirmed by urgent biopsy results (17,18). However, laparoscopy should be done experienced by surgeons in complicated patients. In the meantime, laboratory examinations are time-consuming and have low sensitivity; clinical and radiological diagnosis gain more importance in urgent cases to reduce morbidity and mortality (11).

In our study, abdominal TB was pre-diagnosed in surgery in all patients. After histopathological confirmation of the diagnosis, anti-TB therapy was started as soon as possible. This led to rapid recovery, with decreased

mortality and morbidity. TB was suspected at surgery in Case 1,2 and 3 because of the presence of large calcified lymph nodes.

Abdominal TB can mimic other diseases, both common and rare; despite recent advances, diagnosis may be difficult and time-consuming (11). The clinician must make a differential diagnosis between TB and gastrointestinal diseases such as Crohn's disease, abdominal lymphoma, malignancies of the abdominal viscera, and inflammatory pathologies of the abdomen (10,19). Four patients in our study were referred by emergency clinicians or pediatricians for the diagnosis of acute abdominal conditions. The other three patients presented with chronic abdominal symptoms and this caused diagnostic difficulties for the pediatricians. Our study shows that these difficulties led to misdiagnosis in the acute abdomen group and diagnostic confusion and delay in the chronic abdomen group.

Criticism of Our Treatment Regiments in The Light of Current Literature

Historical-Clinical-Physical Examinations

Family history was positive in only one patient; this rate was so low in comparison to the literature that it caused us diagnostic difficulty. The mean duration of symptoms before hospitalization was 12.5 days. Only four patients suffered from specific acute abdomen triad which pain, abdominal swelling/ascites, and fever, but the others have nonspecific findings. However, three patients have chronic abdominal complaints. All patients (100%) have pain/discomfort and weight loss; however, five patients (77%) have a fever. Five patients complained of abdominal pain for last week, and the remaining for two days. Although physical examination corrected acute abdomen in four patients, there were no specific findings for TB. In contrast to the literature, we insight that the historical examination of patients would not be important because nobody lives in their country.

Radiological Laboratory and Histopathological Findings

Chest X-ray was normal, but ascites (100%) and mesenteric lymphadenomegaly (100%) was detected the most common findings on abdominal USG of all patients, and only three patients were diagnosed on CT together with USG according to radiologist and surgeons conviction. Most of the patients have diagnosed abdominal TB triad classified as lymphadenomegaly, abdominal ascites, and localized peritonitis by USG and CT. Intestinal obstruction or distention was not detected. The culture test and AFS for TB were positive in only one patient (Case 3). Although a positive TST result supports a diagnosis of abdominal TB, a negative result does not exclude the disease. Six of the patients in our study had a BCG scar, which indicates that they had been vaccinated for TB. One patient, a refugee from Syria, did not have the scar. The TST was positive in only one patient. We anterospectively advised that current diagnostic methods will not be adequate because most of the patients have no specific diagnostic findings owing to TB bacilli silent evolution.

Surgical Procedures

All of the patients operated with laparotomy because of laparoscopic device unavailabilities. Four patients urgently were operated owing to acute abdominal findings, and the remaining three patients operated with elective surgery. Appendectomy and lymph node biopsy was performed on six patients. We observed generalized tuberculous peritonitis like appearance, enlarged lymph nodes, and inflamed omentum during surgery. Excised lymph nodes for histopathologic examination were calcified and larger than 1 cm in diameter. The appendixes were found more inflamed and omental adhesions detected in chronic abdominal pain owned patients. However, simple lymph node biopsy was done from only one patient with chronic abdominal complaints which her laparotomic examination was nearly normal except for enlarged mesenteric lymph nodes.

Medical Treatment Regimen

All patients treated with current anti-TB drugs summarized in the results section and healed with uncomplicated.

CONCLUSION

Laparoscopic examination has primary importance for abdominal visualization and biopsy, which TB suspected cases which profoundly positive signs showing modern radiological methods if surgery is inevitable.

****Future Insight: No physician should ignore TB in the differential diagnoses of acute abdomen with the belief that TB has come to an end. Competing interests: The authors declare that they have no competing interest.*

Financial Disclosure: There are no financial supports.

Ethical approval: The requested approval was done Ethics Committee of Ataturk University Faculty of Medicine (07.06.2018/05-20).

REFERENCES

1. Avcu G, Sensoy G, Karli A, et al. A case of tuberculous peritonitis in childhood. *J Infect Public Health* 2015;8:369-72.
2. Uygur-Bayramicli O, Dabak G, Dabak R. A clinical dilemma: abdominal tuberculosis. *World J Gastroenterol* 2003;9:1098-101.
3. Zumla A, George A, Sharma V, et al. The WHO 2014 global tuberculosis report--further to go. *The Lancet Global Health* 2015;3:10-2.
4. Acer T, Karnak I, Ekinci S, et al. Multiple jejunoileal perforations because of intestinal involvement of miliary tuberculosis in an infant. *J Pediatr Surg* 2008;43:17-21.
5. Pekcan S, Tana Aslan A, Kiper N, et al. Multicentric analysis of childhood tuberculosis in Turkey. *Turk J Pediatr* 2013;55:121-9.
6. Dinler G, Sensoy G, Helek D, et al. Tuberculous peritonitis in children: report of nine patients and review of the literature. *World J Gastroenterol* 2008;14:7235-9.
7. Sharma SK, Mohan A. Extrapulmonary tuberculosis. *Indian J Med Res* 2004;120:316-53.
8. Khan R, Abid S, Jafri W, et al. Diagnostic dilemma of abdominal tuberculosis in non-HIV patients: an ongoing challenge for physicians. *World J Gastroenterol* 2006;12:6371-5.
9. Golden MP, Vikram HR. Extrapulmonary tuberculosis: an overview. *American Family Physician* 2005;72:1761-8.
10. Kilic O, Somer A, Hancerli Torun S, et al. Assessment of 35 children with abdominal tuberculosis. *J Turkish Society of Gastroenterology* 2015;26:128-32.
11. Akcam M, Artan R, Yilmaz A, et al. Abdominal tuberculosis in adolescents. Difficulties in diagnosis. *Saudi Med J* 2005;26:122-6.
12. al-Fadel Saleh M, al-Quorain A, Larbi E, et al. Tuberculous peritonitis in children: report of two cases and literature review. *J Pediatr Gastroenterol Nutr* 1997;24:222-5.
13. Lin YS, Huang YC, Lin TY. Abdominal tuberculosis in children: a diagnostic challenge. *J Microbiol Immunol Infect* 2010;43:188-93.
14. Chow KM, Chow VC, Szeto CC. Indication for peritoneal biopsy in tuberculous peritonitis. *Am J Surg* 2003;185:567-73.
15. Shah S, Thomas V, Mathan M, et al. Colonoscopic study of 50 patients with colonic tuberculosis. *Gut* 1992;33:347-51.
16. Singh V, Kumar P, Kamal J, et al. Clinicocolonoscopy profile of colonic tuberculosis. *Am J Gastroenterol* 1996;91:565-8.
17. Hossain J, Kinirons M, Lewis RR. Laparoscopy does have a role in tuberculous peritonitis. *BMJ (Clinical research ed)*. 1996;313:1145-6.
18. Gurkan F, Ozates M, Bosnak M, et al. Tuberculous peritonitis in 11 children: clinical features and diagnostic approach. *Pediatrics international : J Japan Pediatric Society* 1999;41:510-3.
19. Aston NO. Abdominal tuberculosis. *World J Surg* 1997;21:492-9.