

Hydatid cyst disease in children: 10-years experience at two tertiary centers from Northeast Anatolia of Turkey

 Ebru Sener¹,  Ali Kurt²

¹Ataturk University, Faculty of Medicine, Department of Pathology, Erzurum, Turkey

²Erzurum Regional Training and Research Hospital, Clinic of Pathology, Erzurum, Turkey

Copyright © 2020 by authors and Annals of Medical Research Publishing Inc.

Abstract

Aim: Hydatid cyst remains a significant health problem in endemic regions such as Turkey. It can be observed at any age, but the diagnosis is usually made at adulthood. The aim of this study was to investigate the epidemiological findings of hydatid cyst cases in the pediatric age group in Turkey.

Material and Methods: The records of the patients who received the diagnosis of hydatid cyst in the pathology departments of Ataturk University Faculty of Medicine and Erzurum Regional Training and Research Hospital between 2009–2019 were analyzed retrospectively. Data such as age, sex, location, size and number of cysts of the cases diagnosed with hydatid cyst between 0–16 years of age were analyzed statistically.

Results: Of the 1072 cases diagnosed with hydatid cyst, 32.7% (n=351) were within the age range of 0–16 years, 57.8% (n=203) were male and 42.2% (n=148) were female, with a mean age of 10.8 years (SD: ± 3.5; min: 1, max: 16). In 86.3% (n=303) of the cases, the cyst was found to be located in a single organ, whereas it was located in two different organs in 13.7% (n=48) of the cases. Involvement of the liver and lung was observed in 54.4% (n=191) and 50.4% (n=177) of the cases, respectively. Less involvement was observed in brain (n=10), kidney (n=9), spleen (n=5), retroperitoneal region (n=4), omentum (n=2), nasal cavity (n=1), thoracolumbar region (n=1), tail of the pancreas (n=1) and ulna diaphysis (n=1). In all cases, the mean cyst size was measured to be 7.4 cm (SD: ± 2.9; min: 1.5, max: 17) based on the largest cyst size.

Conclusion: Hydatid cyst is also common in the pediatric age group. Hydatid cyst has been found to be more common in males in the pediatric age group in Turkey, with its most common localization being in the liver and lung.

Keywords: Children; hydatid cyst; liver; lung

INTRODUCTION

Hydatid cyst that is a parasitic infection caused by *Echinococcus granulosus* (EG) is a serious public health problem with significant global economic impacts. It is more common in regions where rural life and animal husbandry are widespread and where environmental health measures are insufficient. The disease, which is usually transmitted by accidental ingestion of EG eggs after close contact with dogs, or by vegetables and fruits eaten without being cooked or washed, or by drinking water, begins in the childhood and adolescence period. Parasite eggs enter the body usually through digestion and hatching embryos can cause disease in all organs, most commonly in the liver and lungs (1). Good results can be obtained in general with the proper treatment. However, the prognosis of cysts that develop in areas, where the surgery is difficult to be performed, such as

the heart and spine is worse. Recurrence, spontaneous or traumatic cyst rupture in the cystic region or other regions may cause complications and sudden death specific to the region (2,3).

The number of infected people around the world has been reported to be around 65 million, and the incidence in some regions has been reported to be 15 in 100,000 (4,5). It is particularly seen in the rural areas in endemic regions such as the Middle East, Central Asia, South America, Australia, and New Zealand (6). Turkey is one of the endemic areas for hydatid cyst disease (7,8).

Hydatid cyst is most common in adults aged 19–64. It is relatively rare in the pediatric age group (1,9,10). Cystic lesions that can be seen in many different parts of the body are more commonly localized in the liver and lungs (11). Compared to adults, there might be differences in the location of the hydatid cyst and the number of

Received: 17.02.2020 **Accepted:** 30.03.2020 **Available online:** 16.04.2020

Corresponding Author: Ebru Sener, Ataturk University, Faculty of Medicine, Department of Pathology, Erzurum, Turkey

E-mail: ebruomerogullari@gmail.com

foci in children (12-14). The aim of this study was to epidemiologically investigate the children aged 0–16 who were histopathologically diagnosed with a hydatid cyst.

MATERIAL and METHODS

Ten-year archive records of the patients who received the diagnosis of hydatid cyst in the pathology clinic of Ataturk University Faculty of Medicine and Erzurum Regional Training and Research Hospital between 2009-2019 were analyzed retrospectively. Both hospitals are tertiary health care facilities located in the northeast region of Turkey, providing health services to approximately 4.5 million people, including those living in the surrounding provinces.

Diagnosis of hydatid cyst is relatively less in childhood. In the literature, there are many studies investigating cases of hydatid cyst in children between 0-16 years of age (15,16). In this study, 32.7% (n=351) of a total of 1072 patients, who were found to receive the diagnosis of hydatid cysts histopathologically, were aged 0–16 years.

The histopathologic diagnosis of hydatid disease was made by both macroscopic and microscopic examination. On macroscopic examination, the cyst was white and unilocular and if intact, usually filled with clear fluid (Figure 1). The microscopic diagnosis was made by examination of the cyst wall. The cyst wall was made up of a laminated membrane which was lined by germinal epithelium produces daughter cysts, each of which contains scolices with numerous hooklets (Figure 2).

Data such as age, sex, location, size, and the number of cysts of these cases were analyzed. Cysts sized ≥ 10 cm is defined as giant cysts (17,8). The cysts were also evaluated whether they were giant or not.

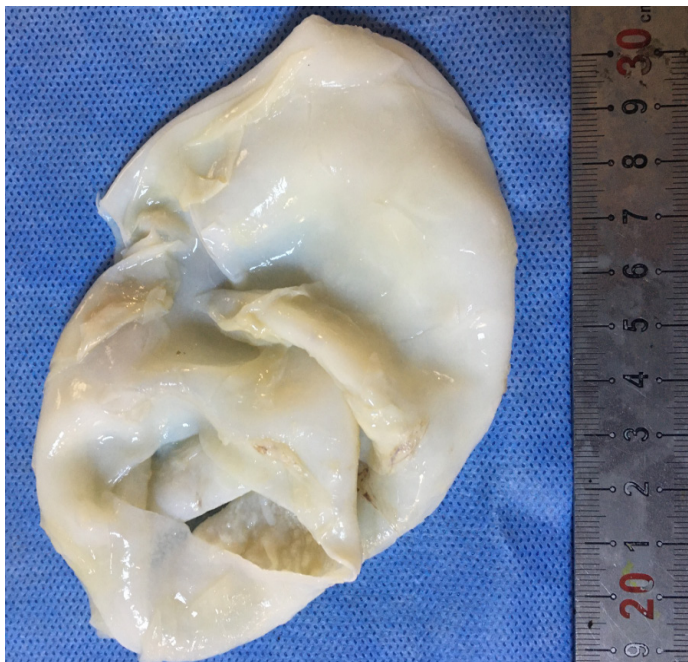


Figure 1. Macroscopic appearance of hydatid cyst.

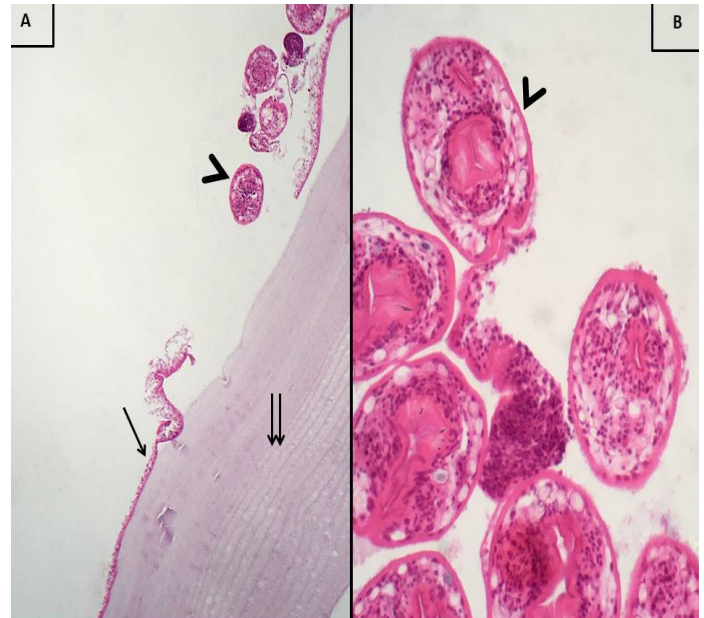


Figure 2. A photomicrograph of an *E. granulosus* cyst section stained with hematoxylin and eosin (H&E). Hydatid cyst wall is composed of a laminated membrane (double arrow), covered by germinal epithelium (single arrow). In the cyst cavity, there are numerous scolices (arrowhead). (Figure 1A: H&E x100, Figure 1B: H&E x400)

Statistical analysis was carried out by using SPSS for Windows version 20.0. The normality test of the data was evaluated by values of skewness and kurtosis. The z-scores were obtained by dividing the skew values or excess kurtosis by their standard errors (19). Chi-square test was used to analyze the comparisons between groups and Student's t-test was used for paired comparisons. A p-value of <0.05 was considered statistically significant.

RESULTS

Of the 351 cases diagnosed with hydatid cysts, who were aged 0–16 years, 57.8% (n=203) were male, and 42.2% (n=148) were female. The mean age of the patients was 10.8 (SD: ± 3.5). The youngest patient was a one-year-old male with a cyst located in the liver (size: 4.5 cm).

Liver and lung involvement was observed in 54.4% (n=191) and 50.4% (n=177) of all cases, respectively. Furthermore, the cyst was found to be located in a single organ in 86.3% (n=303) of the cases, whereas it was located in multiple organs in 13.7% (n=48) of the cases.

The cyst was found to be located in the liver in 47.9% (n=145) of the 303 cases with hydatid cyst located in a single organ whereas it was found to be located in the lung in 46.2% (n=140) and in the brain in 3% (n= 9) of the cases. Of 48 cases with hydatid cysts located in multiple organs, 72.9% (n=35) had the coexistence of lung and liver. Table 1 shows detailed information on the organ involvement of all cases.

The most common localization of the cysts was in the liver and lungs, which was followed by brain, kidney, spleen,

retroperitoneal region, omentum, nasal cavity, thoracic-lumbar region, the tail of pancreas, and ulna diaphysis. Rare localizations other than lung and liver are shown in Table 2.

Table 1. Distribution of cases according to organs involved

Organs involved	Organ	%	n	
Solitary	Lung	39.9	140	
	Liver	41.3	145	
	Brain	2.5	9	
	Kidney	0.8	3	
	Retroperitoneal region	0.3	1	
	Spleen	0.3	1	
	Left syphenoid sinus	0.3	1	
	Thoracic 7- lumbar 4 regions	0.3	1	
	Pancreas tail	0.3	1	
	Ulna diaphysis	0.3	1	
	Multiple	Lung, liver	9.4	33
		Lung, liver, spleen	0.6	2
		Lung, brain	0.3	1
Lung, spleen		0.3	1	
Liver, kidney		1.3	5	
Liver, retroperitoneal region		0.9	3	
Liver, omentum		0.6	2	
Liver, spleen, kidney		0.3	1	
Total		100	351	

In all cases, the mean cyst size was measured to be 7.4 cm (SD: \pm 2.9; min: 1, max: 17) based on the largest cyst size and the giant cyst was detected in 27.1% (n=95) of the cases. However, no giant cyst was detected in cases under five years of age. A giant lung cyst was observed in two five-year-old patients.

When the focal numbers of hydatid cysts in each organ were examined, 65.8% (n=231) of the cases had a single focus, and 34.2% (n=102) had two or more foci.

When the hydatid cyst diameters were examined by their location, the mean diameter of the hydatid cysts located in the lung was found to be 6.7 cm (SD: \pm 2.7; min: 1, max: 15) and the mean diameter of the cysts located in the liver was found to be 7.3 cm (SD: \pm 3.1; min: 1, max: 15).

Giant cysts were detected in 30.4% (n=58) of the cases with liver cysts and in 14.7% (n=26) of the cases with lung cysts. Giant cysts were found to be more common in the liver when compared with the lung (p=0.003). Giant cysts were detected in 50% (n=5) of brain cysts, 11.1% (n=1) of renal cysts and 40% (n=2) of splenic cysts.

When the hydatid cyst cases with lung and liver involvement were compared in terms of sex, age, size of the cyst, presence of a giant cyst, and the number of focus, no difference was observed in terms of sex (p>0.05) (Except for 38 cases where lung and liver held together). Liver involvement was found to be more common in children aged eight years and older, whereas lung involvement was more common in children younger than eight years of age (p=0.026). Cyst size was found to be greater, and the number of the giant cyst and focus was found to be higher in patients with isolated liver involvement (p<0.05) (Table 3).

Table 2. Distribution of organs rarely involved other than lung and liver

Cases	Gender	Age	Uncommon locations	Diameter (cm)	The other organs involved
Case 1	Female	10	Left kidney	13	Liver
Case 2	Male	10	Omentum	8	Liver
Case 3	Female	11	Right frontal lobe	10	
Case 4	Female	9	Omentum	10	Liver
Case 5	Male	15	Right kidney	4	Liver
Case 6	Female	13	Spleen	3	Left lung
Case 7	Female	4	Spleen	3	Lung, liver
Case 8	Male	5	Right kidney	7	
Case 9	Female	6	Retroperitoneal region	11	Liver
Case 10	Male	6	Left syphenoid sinus	2.5	
Case 11	Male	6	Right parietal lobe	9.5	
Case 12	Female	7	Right frontal lobe	11	
Case 13	Male	9	Left frontoparietotemporal lobe	10.1	
Case 14	Female	8	Spleen	12	
Case 15	Female	9	Right kidney	8	Liver
Case 16	Male	9	Right frontoparietal lobe	4.2	

Case 17	Female	10	Retroperitoneal region	14	
Case 18	Female	10	Thoracic 7- lumbar 4 regions	5	
Case 19	Male	10	Left frontoparietal lobe	6.3	
Case 20	Male	10	Spleen	10	Right lung, liver
Case 21	Female	11	Left kidney, spleen	3.4 and 6.5	Liver
Case 22	Female	12	Retroperitoneal region	17	Liver
Case 23	Male	13	Right and left kidney	7.4	Liver
Case 24	Female	13	Right kidney	4	
Case 25	Female	14	Left kidney	5	
Case 26	Female	14	Right parietal lobe	6	
Case 27	Female	15	Retroperitoneal region	10	Liver
Case 28	Male	15	Left temporoparietal lobe	12.5	
Case 29	Female	15	Right parietal lobe	5	
Case 30	Female	16	Pancreas tail	5.5	
Case 31	Male	16	Right kidney	9.5	Liver
Case 32	Male	16	Right ulna diaphysis	3	
Case 33	Female	16	Right frontotemporal lobe	5	Lung

Table 3. Comparison of patients with lung or liver cysts in terms of sex, age, diameter and number of foci *

		Lung n (%)	Liver n (%)	p value
Gender	Male	89 (50.9)	86 (49.1)	>0.05
	Female	53 (43.1)	70 (56.9)	
Age	8 >	31 (62)	19 (38)	0.026
	8 ≤	111 (44.8)	137 (55.2)	
Diameter	Mean (sd)	6.9 (2.6)	7.7 (3)	0.013
Giant cyst	Yes	22 (27.5)	58 (72.5)	<0.001
	No	120 (55)	98 (45)	
Number of focus	Solitary	105 (53.6)	91 (46.4)	0.005
	Multiple	37 (36.3)	65 (63.7)	

*: Thirty-five cases in which lung and liver held together were not included

DISCUSSION

Hydatid cyst, which can be seen in all age groups, is mostly diagnosed in the adult population (1,20). Although most hydatid cyst infections are acquired in childhood, no symptoms may occur for five to 20 years, and clinical symptoms vary according to the location of the cyst (21,22). Approximately 10–20% of hydatid cysts are diagnosed in childhood (23). In the present study, 32.7% of patients diagnosed with hydatid cyst were found to be in the age range of 0–16 years. The rate of cases diagnosed with hydatid cyst in childhood is higher in this study than in the literature. This may be attributed to the fact that patients in the surrounding provinces, particularly pediatric patients, are referred to tertiary health care facilities for treatment.

The mean age of the cases in the present study was 10.8, with the youngest patient aged one year old. In similar studies investigating hydatid cysts in the pediatric population, hydatid cysts have been reported in all age groups, including one year of age (1,6,12,24-26). Our findings were found to be similar to the mean age of hydatid cysts in the pediatric population (10).

In studies examining both adults and children, hydatid cyst has been reported to be more common in women in general, and this has been attributed to the fact that women work more intensively in agriculture and animal husbandry (9,14,27-29). In studies examining only pediatric patients, the hydatid cyst has been reported to be more common in boys (12,15,24,26). Similarly, in the present study, hydatid cysts were more common in boys among the patients aged 0–16. The reason for the disease being more common in boys may be that boys living in rural areas meet the outside environment at a younger age and they are involved in risky and precautionary behaviours that will cause them to be exposed to infection more.

EG eggs enter the body usually through digestion. Although embryos taken via the digestive system and hatching can cause disease in all organs, the disease is most commonly seen in the liver and lungs (29,30). The larvae first attach to the liver through the portal flow. If they cannot attach here, they migrate to the lungs. The most common location site of the larvae is the liver in adults, whereas it is lungs in children. The incidence of larvae in the lungs in children decreases with advancing age (1,12-14,24,25,31). The higher incidence of pulmonary hydatid cysts in children is attributed to the elastic structure of the lung (25,32). In the present study, isolated lung involvement was found to be more common in children younger than eight years of age. In contrast, isolated liver involvement was more common in children aged eight years and older.

Multiorgan localization can be seen in 6–34.8% of pediatric hydatid cysts cases (14). In the literature, the most common multiorgan involvement in children has been reported to be the coexistence of liver and lung (12). Multiorgan involvement was found to be present in 13.7% of our cases. The coexistence of lung and liver cysts was observed in 35 of 48 patients with multiorgan involvement. In other cases, brain or spleen involvement was observed along with lung involvement whereas liver, renal, spleen or retroperitoneal involvement was detected along with liver involvement.

Although hydatid cysts are most commonly located in the liver and lung, they can also be found in many different parts of the body, such as heart, kidney, bone, muscle and nervous system, through hematogenic spread (1,24,26,30,33,34). In the present study, cysts were found to be located less frequently in the brain, kidney, spleen, retroperitoneal region and omentum other than liver and lung. Furthermore, the nasal cavity, thoracic-lumbar region, tail of the pancreas and ulna diaphyseal involvement were found to be rare involvement sites.

A single organ was involved in 85–90% of cases with hydatid cyst and more than 70% of cases have only one cyst. Pulmonary hydatid cyst cases often present with solitary involvement (35). Similar to the literature, solitary involvement was seen in 86.3% of our cases. When the isolated liver and lung involvement were examined, solitary involvement was more common in the lung, whereas multiple involvements were more common in the liver.

Hydatid cysts grow on average 1–5 cm per year, which may change depending on the location (35). Compared to the hepatic hydatid cyst, pulmonary hydatid cysts in children have been reported to grow faster due to the elastic structure of the lung (12,36). Giant cysts are reported to be more common in the lung in pediatric patients (14,17,18). In the present study, no giant cyst was detected in patients under five years of age; however, when compared with the lung, giant cysts were found to be more common in the liver. This may be related to the higher number of cases.

CONCLUSION

In conclusion, according to our findings, the liver and lung are the most commonly involved organs in hydatid cyst cases within the age group of 0–16 years. The diagnosis of 32.7% of all hydatid cysts has been made in the pediatric population. Hydatid cyst disease is not rare in endemic areas. Therefore, raising public awareness about this disease and performing screening programs are important for early diagnosis and treatment of the disease.

Competing interests: The authors declare that they have no competing interest.

Financial Disclosure: There are no financial supports.

Ethical approval: This study was approved by the Ethics Committee (Ethics Nr: 2019/11-118).

Ebru Sener ORCID: 0000-0002-0632-3527

Ali Kurt ORCID: 0000-0003-0394-8609

REFERENCES

- Jairajpuri ZS, Jetley S, Hassan MJ, et al. Hydatid disease in childhood: revisited report of an interesting case. *J Parasit Dis* 2012;36:265-8.
- Wen H, Vuitton L, Tuxun T, et al. Echinococcosis: Advances in the 21st Century. *Clin Microbiol Rev* 2019;32:75-18.
- Sahpaz A, Irez A, Gulbeyaz H, et al. Non-thrombotic Pulmonary Embolism Due to Liver Hydatid Cyst: A Case Report. *Balkan Med J* 2017;34:275-7.
- Craig PS, McManus DP, Lightowlers MW, et al. Prevention and control of cystic echinococcosis. *Lancet Infect Dis* 2007;7:385-94.
- Mandal S, Mandal MD. Human cystic echinococcosis: epidemiologic, zoonotic, clinical, diagnostic and therapeutic aspects. *Asian Pac J Trop Med* 2012;5:253-60.
- Akther J, Khanam N, Rao S. Clinico epidemiological profile of hydatid diseases in central India, a retrospective and prospective study. *Int J Biol Med Res* 2011;2:603-6.
- Ozyurtkan MO, Balci AE. Surgical treatment of intrathoracic hydatid disease: a 5-year experience in an endemic region. *Surg Today* 2010;40:31-7.
- Sadjjadi SM. Present situation of echinococcosis in the Middle East and Arabic North Africa. *Parasitol Int* 2006;55:197-202.
- Ndlovu M, Thule S, Mphahlele R, et al. Pulmonary hydatidosis: Still unrecognised in endemic regions—a 10-year review. *S Afr J Child Health* 2018;12:48-51.
- Gupta R, Sharma SB, Prabhakar G, et al. Hydatid disease in children: our experience. *Formos J Surg* 2014;47:211-20.
- Grosso G, Gruttadauria S, Biondi A, et al. Worldwide epidemiology of liver hydatidosis including the Mediterranean area. *World J Gastroenterol* 2012;18:1425-37.
- Bakal U, Simsek S, Kazez A. Surgical and molecular evaluation of pediatric hydatid cyst cases in eastern Turkey. *Korean J Parasitol* 2015;53:785-8.
- Mirshemirani A, Khaleghnejad A, Kouranloo J, et al. Liver hydatid cyst in children (a 14-year review). *Iran J Pediatr* 2011;21:385-9.
- Ozekinci S, Bakir S, Uzunlar AK, et al. Pulmonary hydatid disease in southeastern Anatolia, Turkey. *Turk J Med Sci* 2010;40:637-41.
- Onal O, Demir OF. The relation between the location and the perforation rate of lung hydatid cysts in children. *Asian J Surg* 2018;41:422-6.
- Topcu S, Kurul IC, Tastepe I, et al. Surgical treatment of pulmonary hydatid cysts in children. *J Thorac Cardiovasc Surg* 2000;120:1097-101.
- Karaoglanoglu N, Kurkcuoglu IC, Gorguner M, et al. Giant hydatid lung cysts. *Eur J Cardiothorac Surg* 2001;19:914-7.

18. Findikcioglu A, Kilic D, Canpolat T, et al. Necessity of lung resection in neglected cases of pulmonary hydatidosis. *Ann Thorac Cardiovasc Surg* 2010;16:187-9.
19. Kim H-Y. Statistical notes for clinical researchers: assessing normal distribution (2) using skewness and kurtosis. *Restor Dent Endod* 2013;38:52-4.
20. Sanli A, Onen A, Karapolat S, et al. Social factors associated with pulmonary hydatid cyst in Aegean, Turkey. *Afr Health Sci* 2011;11:82-5.
21. Lv H, Jiang Y, Liu G, et al. Surgical treatment of multiple hydatid cysts in the liver of a pediatric patient. *Am J Trop Med Hyg* 2015;92:595-8.
22. Zargar-Shoshtari M, Shadpour P, Robat-Moradi N, et al. Hydatid cyst of urinary tract: 11 cases at a single center. *J Urol* 2009;4:41-5.
23. Turgut AT, Altın L, Topçu S, et al. Unusual imaging characteristics of complicated hydatid disease. *Eur J Radiol* 2007;63:84-93.
24. Fahimzad A, Karimi A, Tabatabaei SR, et al. Overview of hydatid disease in Iranian children. *Arch Pediatr Infect Dis* 2015;3:30084.
25. Tantawy IM. Hydatid cysts in children. *Ann Pediatr Surg* 2010;6:98-104.
26. Berberian G, Rosanova MT, Inda L, et al. Echinococcosis in children: Experience in a tertiary care hospital outside the endemic area. *Arch Argent Pediatr* 2017;115:282-6.
27. Gun E, Etit D, Buyuktalanci DO, et al. Unusual locations of hydatid disease: A 10-year experience from a tertiary reference center in Western Turkey. *Ann Diagn Pathol* 2017;29:37-40.
28. Vlad DC, Neghina AM, Dumitrascu V, et al. Cystic echinococcosis in children and adults: a seven-year comparative study in western Romania. *Foodborne Pathog Dis* 2013;10:189-95.
29. Velasco-Tirado V, Romero-Alegria A, Belhassen-Garcia M, et al. Recurrence of cystic echinococcosis in an endemic area: a retrospective study. *BMC Infectious Diseases* 2017;17:455.
30. Parikh F. Echinococcosis cut to cure but what about control. *J Assoc Physicians India* 2012;60:9-10.
31. Chaouachi B, Ben Salah S, et al. Hydatid cysts in children. Diagnostic and therapeutic aspects. Apropos of 1195 cases. *Ann Pediatr (Paris)* 1989;36:441-4, 447-9.
32. Halezeroglu S, Celik M, Uysal A, et al. Giant hydatid cysts of the lung. *J Thorac Cardiovasc Surg* 1997;113:712-7.
33. Kizilca O, Altas M, Senol U, et al. Hydatid disease located in the cerebellomedullary cistern. *Case Rep Med* 2014;2014:271365.
34. Imperato A, Consales A, Ravegnani M, Castagnola E, Bandettini R, Rossi A. Primary Hydatid cyst of the brain in a child: A case report. *Pol J Radiol* 2016;81:578-82.
35. Tilkan OK, Uysal S, Gokçe M. Hydatid Cysts Disease. *Med J West Black Sea* 2018;2:153-9.
36. Aslanabadi S, Zarrintan S, Abdoli-Oskouei S, et al. Hydatid cyst in children: A 10-year experience from Iran. *Afr J Paediatr Surg* 2013;10:140-4.