

Kounis syndrome in a patient with secondary mast cell activation syndrome after a bee sting

 Gokhan Aytekin¹,  Fatih Colkesen¹,  Eray Yildiz¹,  Sevket Arslan¹,  Pembe Oltulu²

¹Necmettin Erbakan University, Meram Faculty of Medicine, Department of Internal Medicine, Division of Clinical Immunology and Allergy, Konya, Turkey

²Necmettin Erbakan University, Meram Faculty of Medicine, Department of Pathology, Konya, Turkey

Copyright © 2020 by authors and Annals of Medical Research Publishing Inc.

Abstract

A 64-year-old male patient was admitted to our clinic with complaints of hot flashes all over the body, fainting and loss of consciousness after a bee sting. The patient who had no history of coronary artery disease was fitted with a stent in the LAD coronary artery with a percutaneous coronary angioplasty by complaints of chest pain and shortness of breath after the bee sting. I3 *Vespula* spp (yellow jacket) in serum was positive at 0.39 kUA / L-class 1. Tryptase levels were elevated at 19.5/g/L during the asymptomatic period. After the tryptase levels remained elevated at 49.2/g/L during the asymptomatic period after 4 weeks. The bone marrow biopsy revealed a mast cell ratio of 2%. Based on the patient's history, physical examination and laboratory findings, the patient was considered to have Kounis syndrome, mast cell activation syndrome and a venom allergy.

Keywords: Hymenoptera venom allergy; kounis syndrome; mast cell activation syndrome; omalizumab

INTRODUCTION

Mast cell activation syndrome (MCAS) is an umbrella term used to describe clinical presentations rather than a clinical diagnosis (1). This syndrome is common in adults, and patients present with signs of episodic mast cell activation, such as hot flashes, abdominal cramps, hypotension and anaphylaxis, similar to patients with systemic mastocytosis (SM) (2). However, urticaria pigmentosa or maculopapular mastocytosis is not observed in these patients. Fewer mast cell aggregates are expected in the bone marrow than with systemic mastocytosis. Serum tryptase levels are also normal or slightly elevated. Patients with mast cell activation syndrome meet one or two minor diagnostic criteria of systemic mastocytosis, but do not meet all criteria for systemic mastocytosis (3). In these patients, symptoms associated with mast cell activation may be mild or life-threatening. Acute coronary syndrome is one of the life-threatening symptoms. Kounis syndrome is a specific name for a coronary syndrome caused by mediators secreted by mast cells present in coronary arteries due

to allergic reaction (4). In this case, we aimed to present a patient who developed acute coronary syndrome after a bee sting and in which we detected mast cell activation syndrome following further investigation.

CASE REPORT

A 64-year-old male patient was admitted to our clinic with complaints of hot flashes all over the body, fainting and loss of consciousness after a bee sting. The patient's history revealed that they had been previously brought to the emergency department three times by paramedics due to fainting and loss of consciousness after bee stings. The patient who had no history of coronary artery disease was fitted with a stent in the left anterior descending artery with a percutaneous coronary angioplasty upon findings from an electrocardiogram, laboratory tests and physical examination consistent with acute coronary syndrome accompanied by complaints of chest pain and shortness of breath after the bee sting in November 2018 (Figure 1).

Received: 26.10.2019 **Accepted:** 10.12.2019 **Available online:** 02.04.2020

Corresponding Author: Gokhan Aytekin, Necmettin Erbakan University, Meram Faculty of Medicine, Department of Internal Medicine, Division of Clinical Immunology and Allergy, Konya, Turkey **E-mail:** ayteking@gmail.com

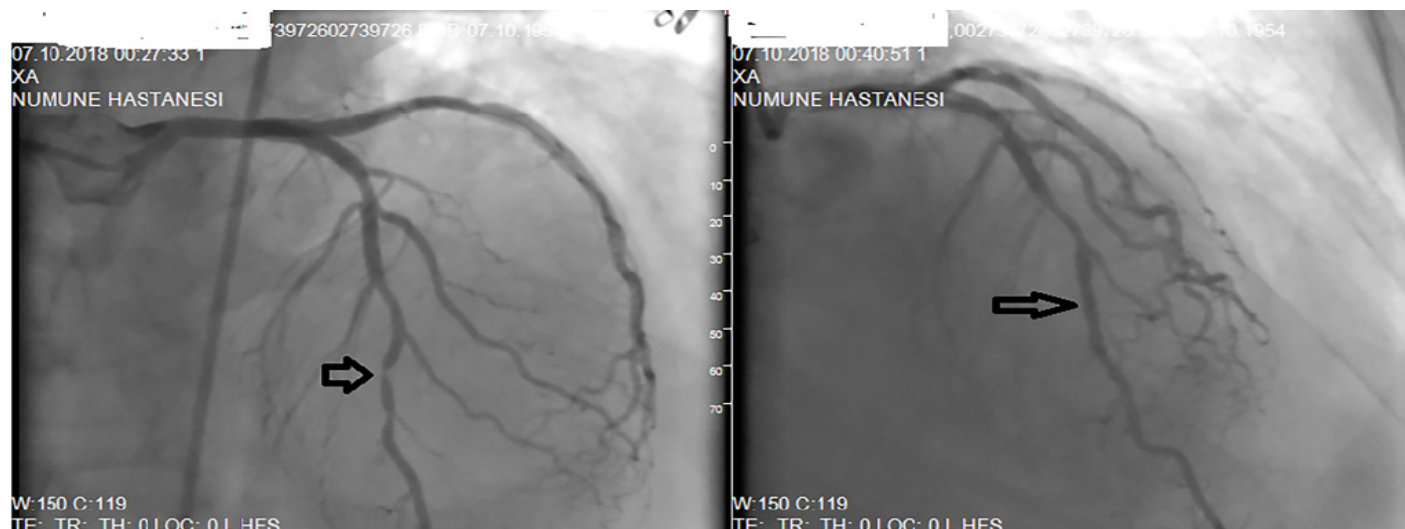

Figure 1. Coronary angiography at the time of his presentation at the outline hospital. (a) Severe stenosis at mid left anterior descending artery (LAD). (b) Repeat angiography after stent deployment at LAD

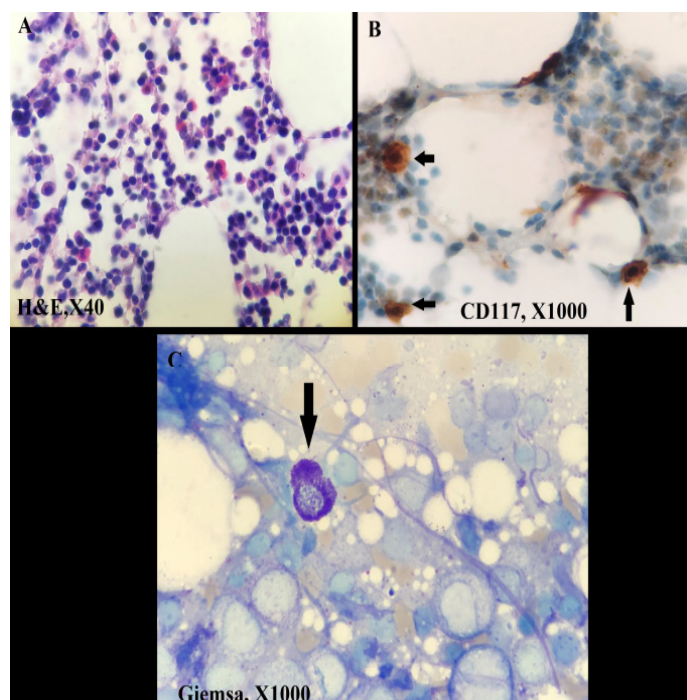


Figure 2. A) Bone marrow biopsy overview, mast cells cannot be clearly recognized by Hematoxylin and eosin stain B) Cluster of differentiation (CD) 117 immune histochemical staining shows 2-3% mast cells (black arrow) C) Bone marrow aspirate shows mast cell (Black arrow)

DISCUSSION

Mast cells are effector cells of many inflammatory and allergic conditions (5). These cells have high affinity receptors for IgE and secrete various vasoactive and inflammatory mediators such as histamine, serotonin, dopamine, leukotrienes, thromboxane and bradykinin once activated (6). These mediators may cause symptoms such as itching, redness, shortness of breath, nausea, stomach cramps, hypotension, as well as life-threatening

conditions such as anaphylaxis (7). Mast cell activation syndrome (MCAS) refers to the presence of typical clinical symptoms resulting from the release of mast cell mediators, a transient elevation in the release of total tryptase and other mast cell mediators, and a good clinical response to drugs that inhibit the release of these mediators (2). This syndrome can be classified into three groups as primary, secondary and idiopathic MCAS. Secondary MCAS refers to the presence of an underlying allergy or a condition that causes mast cell activation. In the present case, the patient was thought to have MCAS due to recurrent episodes of anaphylaxis; high serum tryptase levels, yet not as much mast cell infiltration as expected in systemic mastocytosis in the bone marrow; and the regression of patient complaints with levocetirizine/montelukast treatment. It was also regarded as secondary MCAS due to an underlying vesperula allergy.

Whereas, Kounis syndrome (allergic angina and allergic myocardial infarction) refers to the clinical presentation leading to coronary spasms, atheroma plaque erosion or rupture and acute myocardial infarction by mediators released from mast cells. (8-10) Bee stings are one of the triggers of this condition (11).

Hymenoptera venom allergy (HVA) is an IgE-mediated reaction responsible for 1.5 to 34% of all cases of anaphylaxis (12). Patients with an underlying mast cell disease have an increased susceptibility to anaphylaxis to Hymenoptera stings (13). Bonadonna et al. detected elevated serum tryptase levels in 44 patients (11.6%) in a study with 379 patients who developed systemic reactions after Hymenoptera stings and 34 of these patients underwent a bone marrow biopsy. Bone marrow examinations revealed systemic mastocytosis in 21 patients (61.7%) and MCAS in 9 patients (26.5%). (14) In another study, mast cell disease was detected in 4 (1.5%) of 274 patients who developed a systemic reaction due to a Hymenoptera sting (15).

Although venom immunotherapy is a safe and effective treatment modality in patients without mast cell disease and who have a history of anaphylactic reaction after a Hymenoptera sting, there are doubts regarding its safety and efficacy in patients with mast cell disease (12,16). Based on data obtained from case reports and small case series, lifelong venom immunotherapy is recommended in the presence of an underlying mast cell disease (12,17,18). However, it is not clear how long, at what doses and how often anti IgE treatment will continue during immunotherapy. In one study, a single dose omalizumab injection was found to be sufficient prior to ultra-rush venom immunotherapy, whereas 30 doses of a 150-mg injection was required in another patient who received ultra-rush immunotherapy (19,20). In another study, Da Silva et al. administered 300 mg omalizumab 10 weeks, 6 weeks and 2 weeks before ultra-rush venom immunotherapy in a patient with MCAS. A total of 9 injections were required for monthly omalizumab injections for 6 months in the early maintenance period following venom immunotherapy (18).

Adrenaline may be insufficient in preventing anaphylaxis in patients under long-term beta-blocker therapy. Therefore, these patients should be prescribed a glucagon kit in addition to an adrenaline auto-injector (21). Javeed et al. reported that anaphylaxis due to a contrast agent in a patient using atenolol for coronary artery disease did not respond to repeated doses of adrenaline, but the clinical response improved very rapidly with a bolus of 1 mg glucagon (22). Another study reported that the hypotension in a patient in anaphylactic shock improved with glucagon (23).

CONCLUSION

In conclusion, HVA is a condition which can cause life-threatening clinical presentations, such as acute coronary syndrome. An underlying mast cell disease should be considered in patients with a consistent history and elevated tryptase levels, particularly in the asymptomatic period. Venom immunotherapy should be administered with caution in patients with mast cell disease and HVA, and it should be kept in mind that anti-IgE therapy can be used in addition to anti-histamines and leukotriene modifiers before and during immunotherapy. Furthermore, glucagon should be prescribed in addition to an adrenaline auto-injector in some patients requiring B-blocker therapy.

Competing interests: The authors declare that they have no competing interest.

Financial Disclosure: There are no financial supports.

Gokhan Aytekin ORCID: 0000-0002-9089-5914

Fatih Colkesen ORCID: 0000-0002-6595-1267

Eray Yildiz ORCID: 0000-0002-9596-1773

Sevket Arslan ORCID: 0000-0002-0343-0159

Pembe Oltulu ORCID: 0000-0003-3273-671X

REFERENCES

1. Akin C, Valent P, Metcalfe DD. Mast cell activation syndrome: Proposed diagnostic criteria. *J Allergy Clin Immunol Pract* 2010;126:1099-104.
2. Valent P, Akin C, Arock M, et al. Definitions, criteria and global classification of mast cell disorders with special reference to mast cell activation syndromes: A consensus proposal. *Int Arch Allergy Immunol* 2012;157:215-25.
3. Valent P. Mast cell activation syndromes: definition and classification. *Allergy* 2013;68:417-24.
4. Bongo AS, Fornaro G, Sansa M, et al. [Acute myocardial infarction after wasp sting without anaphylactic reaction]. *Italian heart journal Supplement : Official J the Italian Federation of Cardiology* 2005;6:178-82.
5. Metcalfe DD. Mast cells and mastocytosis. *Blood* 2008;112:946-56.
6. Rivera J, Gilfillan AM. Molecular regulation of mast cell activation. *J Allergy Clin Immunol Pract* 2006;117:1214-25.
7. Webb LM, Lieberman P. Anaphylaxis: a review of 601 cases. *Annals of allergy, asthma & immunology : official publication of the American College of Allergy, Asthma, & Immunology* 2006;97:39-43.
8. Kounis NG. Kounis syndrome (allergic angina and allergic myocardial infarction): A natural paradigm? *Int J Cardiol* 2006;110:7-14.
9. Biteker M, Duran N, Biteker F, et al. Kounis syndrome: First series in Turkish patients. *Anadolu kardiyoloji dergisi : Akd = The Anatolian J Cardiology* 2009;9:59-60.
10. Kartal Ö, Güleç M, Çalışkaner AZ, Kounis Syndrome: Allergic Angina and Allergic Myocardial Infarction: Review. *Türkiye Klinikleri Cardiovascular Sciences* 2010;22:253-61.
11. Aminiahidashti H, Laali A, Samakoosh AK, et al. Myocardial infarction following a bee sting: A case report of Kounis syndrome. *Annals of Cardiac Anaesthesia* 2016;19:375-8.
12. Niedoszytko M, Bonadonna P, Oude Elberink JN. Epidemiology, diagnosis, and treatment of Hymenoptera venom allergy in mastocytosis patients. *Immunology and Allergy Clinics of North America* 2014;34:365-81.
13. Brockow K, Jofer C, Behrendt H, et al. Anaphylaxis in patients with mastocytosis: a study on history, clinical features and risk factors in 120 patients. *Allergy* 2008;63:226-32.
14. Bonadonna P, Perbellini O, Passalacqua G, et al. Clonal mast cell disorders in patients with systemic reactions to Hymenoptera stings and increased serum tryptase levels. *J Allergy Clin Immunol Pract* 2009;123:680-6.
15. Guenova E, Volz T, Eichner M, et al. Basal serum tryptase as risk assessment for severe Hymenoptera sting reactions in elderly. *Allergy* 2010;65:919-23.

16. Yilmaz I, Bahcecioglu SN, Turk M. Combination of omalizumab and bee venom immunotherapy: does it work? *Asia Pacific allergy* 2018;8:2.
17. Castells MC, Hornick JL, Akin C. Anaphylaxis after hymenoptera sting: is it venom allergy, a clonal disorder, or both? *J Allergy Clin Immunol Pract* 2015;3:350-5.
18. da Silva EN, Randall KL. Omalizumab mitigates anaphylaxis during ultrarush honey bee venom immunotherapy in monoclonal mast cell activation syndrome. *J Allergy Clin Immunol Pract* 2013;1:687-8.
19. Kontou-Fili K. High omalizumab dose controls recurrent reactions to venom immunotherapy in indolent systemic mastocytosis. *Allergy* 2008;63:376-8.
20. Galera C, Soohun N, Zankar N, et al. Severe anaphylaxis to bee venom immunotherapy: efficacy of pretreatment and concurrent treatment with omalizumab. *Journal Of Investigational Allergology & Clinical Immunology*. 2009;19:225-9.
21. Welzel T, Ziesenitz VC, Seitz S, et al. Management of anaphylaxis and allergies in patients with long QT syndrome: A review of the current evidence. *Annals of allergy, asthma & immunology : official publication of the American College of Allergy, Asthma, & Immunology* 2018;121:545-51.
22. Javeed N, Javeed H, Javeed S, et al. Refractory anaphylactoid shock potentiated by beta-blockers. *Catheterization and Cardiovascular Diagnosis* 1996;39:383-4.
23. Zaloga GP, DeLacey W, Holmboe E, et al. Glucagon reversal of hypotension in a case of anaphylactoid shock. *Annals of Internal Med* 1986;105:65-6.