

Primary low grade chondrosarcoma of the toe; an atypical localization

Mahmut Nedim Aytekin¹, Baris Kafa¹, Bulent Celasun¹, Enes Uluyardimci¹, Temel Oguz¹, Nihat Tosun¹, Recep Ozturk³

¹Ankara Yildirim Beyazit University, Atatürk Training and Research Hospital, Department of Orthopaedics and Traumatology, Ankara, Turkey

²Goren Laboratory of Pathology, Ankara, Turkey

³Dr. Abdurrahman Yurtaslan Ankara Oncology Training and Research Hospital, Department of Orthopaedics and Traumatology, Ankara, Turkey

Copyright © 2020 by authors and Annals of Medical Research Publishing Inc.

Abstract

Chondrosarcoma is one of the bone primary malign tumors. After myeloma and osteosarcoma it is the third primary malignant tumor of the bone. The most common locations are long bones, pelvis and ribs. Chondrosarcoma of the feet is an uncommon location. In this study, we present a 45-year-old female patient with chondrosarcoma of the right foot. We applied a marginal excision. No complication occur and no recurrence has not been seen during the patient's 3-year postoperative follow-up.

Keywords: Chondrosarcoma; toe; feet; malignant; tumors; atypical localization

INTRODUCTION

Chondrosarcoma is one of the bone primary malign tumors. After myeloma and osteosarcoma it is the third primary malignant tumor of the bone. The most common locations are long bones, pelvis and ribs. It is usually seen in older patients (40-75 ages) and hands and feet are uncommon locations (1). There are three grades of primary chondrosarcomas; low-grade, high-grade and dedifferentiated. Also subtypes of chondrosarcomas are clear cell and mesenchymal chondrosarcoma. 85% of primary chondrosarcoma is grade 1-2 and 15% of them is grade 3 lesions (2). Tumor location is important for prognosis. Although hands and feet chondrosarcomas has the same histology with long bones chondrosarcomas, they are more benign lesions (3). Especially phalangeal chondrosarcoma metastasis is rare (1).

CASE REPORT

Our case is 45-year-old man. He admitted our clinic

with his right foot first finger's swelling, deformity and pain for 5 years (Figure 1). Especially night pain increased in the last 6 months. Initially, the patient who unaware complaints and he was very unhappy because of the difficulty in wearing shoes. Patient has no other known disease. Written informed consent was obtained from the patient's legal custodian or first-degree relatives for publishing the individual medical records.

The patient's x-ray shows us an expansile lesion the distal phalanx with calcification and osteolytic structures like popcorn. The patient has also a congenital 4th brachimetatarsia deformity shown in Figure 2.

On the other hand, there is an expansile, lytic, and MRI shows T1-weighted images lesion is isointense with muscles and T2-weighted images hyperintense with muscles and there was no significant findings in other laboratory results (Figure 4). Bone scintigraphy, thorax CT and abdominal ultrasonography have been performed for possible metastases of this patient. There was no metastasis.

Received: 18.11.2019 Accepted: 10.02.2020 Available online: 13.03.2020

Corresponding Author: Recep Ozturk, Dr. Abdurrahman Yurtaslan Ankara Oncology Training and Research Hospital, Department of Orthopaedics and Traumatology, Ankara, Turkey

E-mail: ozturk_recep@windowslive.com

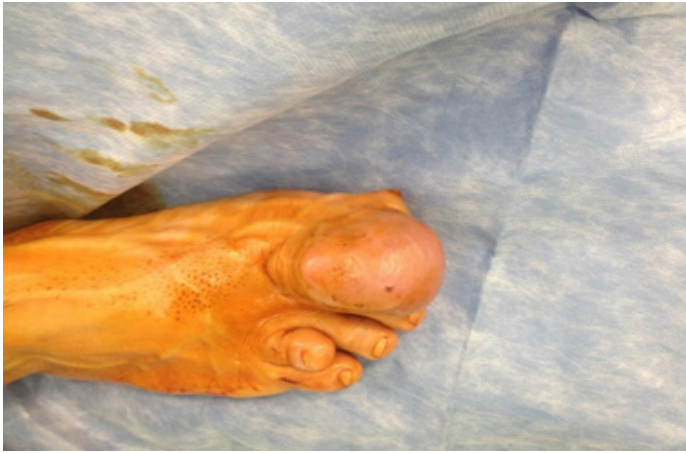

Figure 1. Pre-operative photograph of the patient to multiloculated lesion about 65x36x39 mm with calcifications around distal phalanx and extending laterally in computed tomography scan (Figure 3).

The patient underwent a needle biopsy, in order to make a certain diagnosis. Biopsy results were reported as a low-grade chondrosarcoma. Although the treatment of low-grade chondrosarcoma may vary between intralesional excision to wide excision, we applied a marginal excision because of patient's intractable claim (3) (Figure 5).

Pathologic examination revealed tumor has basophilic cartilage matrix comprising cells with lobules and moderate cellular atypia. Tumor surrounded by the perioste where it invading cortical bone.

No complication occurred and there was no recurrence during the patient's 3-year postoperative follow-up.

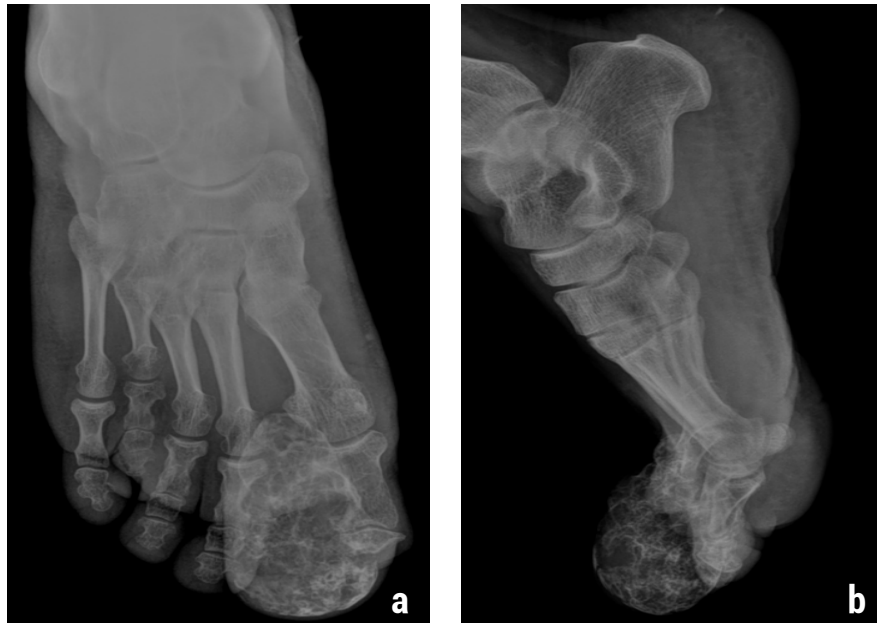

Figure 2. a) Antero-posterior X-ray of the right foot. b) Lateral X-ray of the right foot.

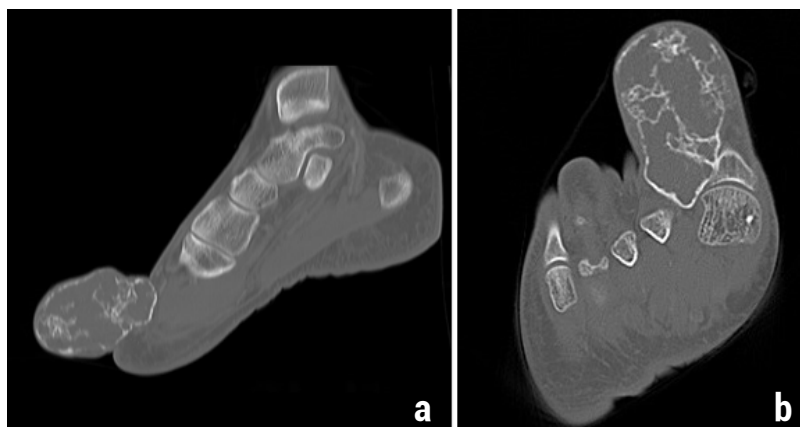


Figure 3. Expansile, lytic, multiloculated lesion around distal phalanx in computed tomography scan. a) antero-posterior view, b) lateral view

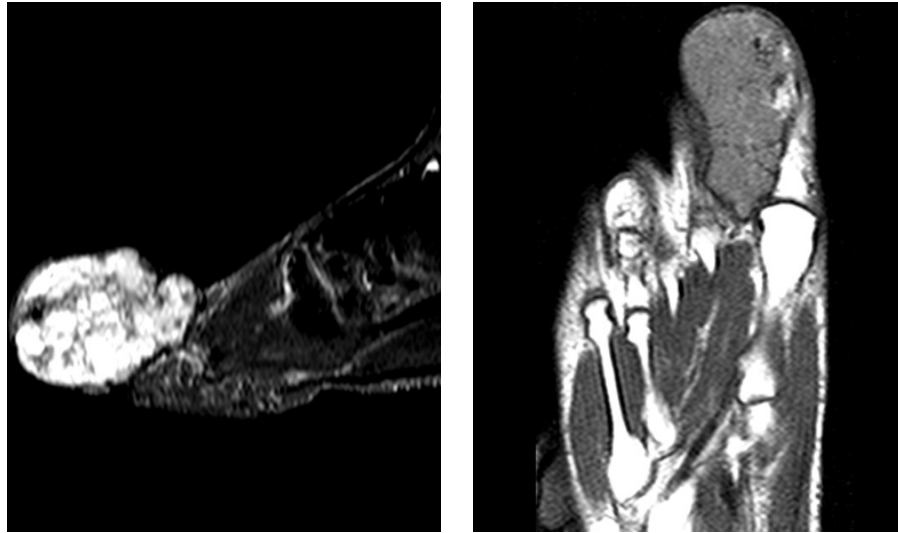


Figure 4. MRI of the lesion shows T1-weighted images lesion is isointense with muscles and T2-weighted images hyperintense with muscles

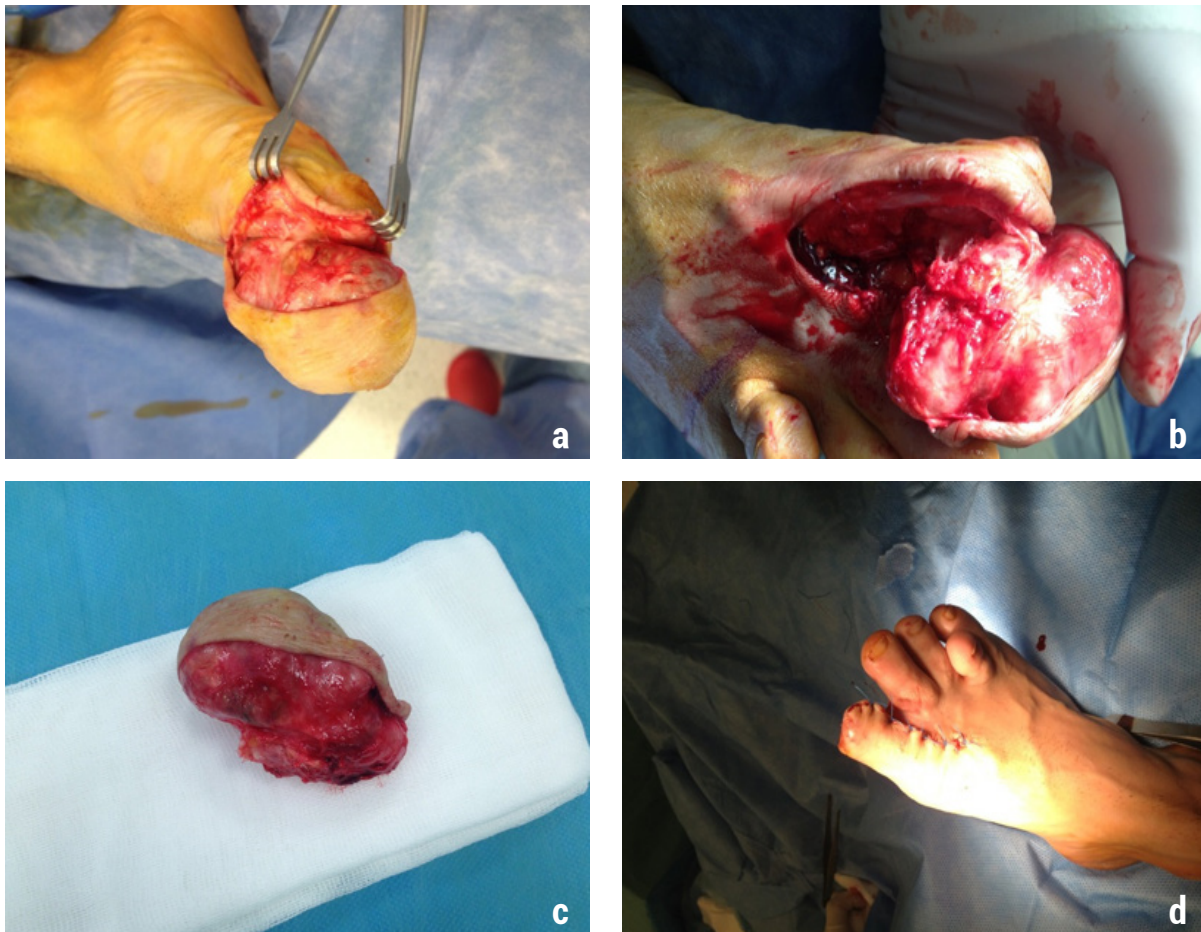


Figure 5. a-b) Intraoperative photos. c) Macroscopic photo of the excised tumor. d) Postoperative photo of the patient's foot.

DISCUSSION

Chondrosarcoma of the feet is an uncommon location. Primary conventional intramedullary chondrosarcoma is most often associated with long bones. While femur and humerus chondrosarcoma rate is 65% of all

chondrosarcomas, hands and feet chondrosarcoma rate is only 1-4% (2, 4,5). Ogose et al. reviewed that only 75 (7%) feet chondrosarcoma diagnosed in 1030 bone chondrosarcoma (6). Bone tumor registry in Japan reported 991 cases of bone chondrosarcoma including only 26 (2.6%) feet chondrosarcoma. Of those

26 feet chondrosarcoma included only 7 (0.7 %) phalanx chondrosarcoma (7).

The prognosis is determined by tumor location. Especially hands and feet are more benign tumors than seen in other long bone chondrosarcomas. Ogose et al. follow up 75 feet and 88 hands chondrosarcoma. 116 of these chondrosarcomas are grade-1, 44 tumors are grade-2, only 3 of them grade-3 lesions. Only 12 tumors distant metastases and 7 patients died. Calcaneus and talus lesions often metastases (6). Phalangeal chondrosarcomas usually behave like local aggressive lesions but another location chondrosarcoma distant metastases (1).

Treatment of low-grade chondrosarcoma is complete excision with clear margins. These tumors can be treated by curettage, local resection or amputation. In this case we offered to the patient phalanx amputation but he did not accept and we operated him with marginal excision. Ogose et al. treated their patients by curettage, local resection or amputation. They reported that patients who treated by amputation have least recurrence (2.2%) rate (6-11). In this case we did not have any local recurrence for 3 years. Bovee et al reviewed 28 phalanx chondrosarcoma. Ten patients treated by recurrent surgery. After these 10 patients recurrent surgery 4 of them treated by another second local recurrent surgery. None of 28 patients had metastasis (1).

CONCLUSION

In conclusion, chondrosarcoma of the toe is so rare and even marginal excision may be enough for low grade.

Competing interests: The authors declare that they have no competing interest.

Financial Disclosure: There are no financial supports.

Mahmut Nedim Aytekin ORCID: 0000-0003-4344-6742

Baris Kafa ORCID: 0000-0003-1367-5683

Bulent Celasun ORCID: 0000-0002-2794-4568

Enes Uluyardimci ORCID: 0000-0002-0068-2852

Temel Oguz ORCID: 0000-0001-7930-9462

Nihat Tosun ORCID: 0000-0002-8120-4640

Recep Ozturk ORCID: 0000-0002-6753-9321

REFERENCES

1. Bovee JV, van der Heul RO, Taminiau AH, et al. Chondrosarcoma of the phalanx: a locally aggressive lesion with minimal metastatic potential: a report of 35 cases and a review of the literature. *Cancer*
2. Marco RA, Gitelis S, Brebach GT, et al. Cartilage tumors: evaluation and treatment. *J Am Acad Orthop Surg* 2000;8:292-304.
3. Springfield DS, Gebhardt MC, McGuire MH. Chondrosarcoma: a review. *Instr Course Lect* 1996;45: 417-24.
4. Murphey MD, Walker EA, Wilson AJ, et al. From the archives of the AFIP: imaging of primary chondrosarcoma: radiologic-pathologic correlation. *Radiographics* 2003;23:1245-78.
5. Mittermayer F, Dominkus M, Krepler P, et al. Chondrosarcoma of the hand: is a wide surgical resection necessary? *Clin Orthop Relat Res* 2004;424:211-5.
6. Ogose A, Unni KK, Swee RG, et al. Chondrosarcoma of small bones of the hands and feet. *Cancer* 1997; 80: 50-9.
7. Masuda T, Otuka T, Yonezawa M, et al. Chondrosarcoma of the distal phalanx of the second toe: a case report. *J Foot Ankle Surg* 2004;43:110-2.
8. Öztürk R, Arıkan ŞM, Özanlağan E, et al. Management of chondrosarcomas localized to phalanges. *Ann Clin Anal Med* 2020;11:171-4.
9. Kalem M, Sevimli R, Ünlü A, et al. Isolated Sessile Chondrosarcoma Arising in Osteochondroma: A Case Report. *Acta Oncol Tur* 2014;47:16-8.
10. Atalay İB, Yılmaz S, Şimşek MA, et al. Chondrosarcomas of the phalanges of the hand. *Eklem Hastalik Cerrahisi* 2018;29:34-9.
11. Sevimli R. Distribution and evaluation of primary bone and soft tissue tumors admitted from Malatya province and surrounding provinces. *Med Sci* 2017;6:546-50.