

The comparison of saline infusion sonography and transvaginal sonography for the intracavitary lesions in infertile women

Vehbi Yavuz Tokgoz¹, Tufan Oge¹, Engin Korkmazer², Ahmet Basar Tekin¹

¹Eskisehir Osmangazi University, Faculty of Medicine, Department of Obstetrics and Gynecology, Eskisehir, Turkey

²Private Esentepe Hospital, Clinic of Obstetrics and Gynecology, Bursa, Turkey

Copyright © 2020 by authors and Annals of Medical Research Publishing Inc.

Abstract

Aim: The aim of this study is to compare the diagnostic accuracy of transvaginal sonography and saline infusion sonography in the detection of intracavitary space-occupying lesions (endometrial polyp and submucous fibroid) in infertile women.

Material and Methods: Three hundred and twenty-three women with infertility were involved in this retrospective study. The diagnostic accuracy of transvaginal sonography and saline infusion sonography were compared with respect to evaluation by diagnostic hysteroscopy results. The sensitivity, specificity, predictive values and ROC curves were used to determine the efficacy of methods for detecting the intracavitary space-occupying lesions in infertile patients.

Results: The incidence of intracavitary space-occupying lesions was 82.1% infertile women. The endometrial polyp and submucous fibroid were established in 56 (17.3%) and 5(1.5%) patients, respectively. The sensitivity and specificity of transvaginal sonography were 50.8% and 98.1%, respectively. These values were 80.3% and 98.5% for saline infusion sonography, respectively. Saline infusion sonography was found superior to transvaginal sonography for evaluating the intracavitary space-occupying lesions.

Conclusion: Saline infusion sonography was more accurate diagnostic modality than transvaginal sonography to assess the intracavitary space-occupying lesions in the infertility population. Therefore the addition of saline infusion sonography to the infertility workup may prevent unnecessary invasive procedures to evaluate the uterine cavity.

Keywords: Transvaginal sonography; saline infusion sonography; hysteroscopy; infertility; endometrial polyp; submucosal fibroid

INTRODUCTION

An optimal intrauterine environment is required to obtain a successful pregnancy. It is known that a reasonable endometrial cavity contributes to this process and the favorable cross-talk between embryo and endometrium improves the implantation rate. Any intrauterine pathologies may impact the implantation in subfertile women negatively (1). The evaluation of the intrauterine cavity is one of the main parts of the diagnostic workup for infertile women. A variety of tools are used in the diagnosis of endometrial pathology, the most commonly used method is transvaginal sonography (TVS) universally preferred as initial and non-invasive evaluation of the uterine cavity in the patients with abnormal uterine bleeding or infertility (2,3). However, saline infusion sonography (SIS) enhances

visualization of the endometrium and shows better results to demonstrate the intracavitary lesions. SIS is a minimally invasive and cost-effective procedure, moreover, it has higher diagnostic accuracy to detect the intracavitary abnormalities (4,5). In a diagnostic algorithm, the choice of one test over another will depend primarily on its diagnostic accuracy. TVS and SIS are non-invasive diagnostic tests and it is thought that SIS is a more accurate method to determine the intracavitary lesions based on the addition of contrast agents. Hysteroscopy is widely accepted as the gold standard method for direct visualization of the uterine cavity in particular intracavitary masses with an simple, fast and accurate way of examining intrauterine abnormalities and it is suggested in the basic infertility assessment (6-8). The aim of the study was to compare the diagnostic accuracy of TVS and SIS for detecting

Received: 26.11.2019 Accepted: 07.01.2020 Available online: 20.02.2020

Corresponding Author: Vehbi Yavuz Tokgoz, Eskisehir Osmangazi University, Faculty of Medicine, Department of Obstetrics and Gynecology, Eskisehir, Turkey E-mail: mdtokgoz@hotmail.com

intracavitary space-occupying lesions (endometrial polyp and submucous fibroid) with the reference of DH as the gold standard method.

MATERIAL and METHODS

This retrospective observational study was conducted at Eskisehir University Faculty of Medicine, Infertility Unit in two years period. The study was approved by the institutional review board and the study protocol was in agreement with the Helsinki Declaration for Ethical Medical Research (Ref. No: 25403353-050.99-E137). The women with a diagnosis of infertility were involved the study population. These women were evaluated for infertility work-up and the selected patients firstly underwent transvaginal sonography (TVS) and then saline infusion sonography(SIS) was performed during the early-mid proliferative phase. The patients' age, body mass index (BMI), duration of infertility, diagnosis of infertility and findings of TVS, SIS and diagnostic hysteroscopy were recorded. Taken the office hysteroscopy as a gold standard method for the detection of the intracavitary lesions; sensitivity, specificity, positive and negative predictive values and likelihood ratios(LR) of TVS and SIS were documented. The inclusion criteria were women who presented with infertility, underwent TVS, SIS, and diagnostic hysteroscopy, the diagnosis of normal or intracavitary space-occupying lesions (polyp or fibroid) on the diagnostic hysteroscopy and no previous operative hysteroscopy procedure. Exclusion criteria were; the premenopausal women who were not infertile, the possible pregnancy, the presence of pelvic inflammatory disease, other endometrial structural pathologies (hyperplasia, uterine anomalies, suspicion of malignancy) on the diagnostic hysteroscopy. During initial transvaginal ultrasonography, the maximum endometrial thickness and the presence or absence of the intracavitary lesions (endometrial polyps and submucous fibroids) were recorded. During SIS, an 8 F Foley catheter with 2 cm width and 15 cm in length was inserted through the cervical canal and 5–10 mL of 0.9% saline solution instilled into the endometrial cavity. The cervix was not dilated and local anesthesia was not used. Similar to the conventional ultrasonography, the presence of the intracavitary abnormalities were recorded. Diagnostic hysteroscopy was carried out by the most experienced operators for the vaginoscopic technique. Diagnostic hysteroscopy was performed without tenaculum, speculum, and antiseptic solution using a Storz 5-mm telescope with a 30° fore-oblique lens (Karl Storz GmbH, Tuttlingen, Germany). In addition, there was no use of sedation or local anesthetics. The patient was placed in the lithotomy position, a gynecologic exploration was carried out to determine the size and position of the uterus as well as the characteristics of the cervix. The uterine cavity was distended with a 0.9% saline solution (HysteRo-Purator, WISAP, Munchen, Germany pressure at a flow rate of 30-450 ml / min using intraluminal pressure about 50-100 mmHg). The endometrial surface

was inspected systematically, and the tubal ostia were identified. If any intracavitary pathology was determined, the operative hysteroscopy procedure was planned to resect the abnormality and endometrial biopsy was taken under direct visualization in another session. The findings obtained from TVS and SIS were compared with those of diagnostic hysteroscopy. The intracavitary space-occupying lesions were; endometrial polyp (hyperechogenic complete intracavitary lesions, motile during fluid injection) and submucous fibroid(hypo- or hyperechogenicity and continuity with the myometrium). Figure 1A shows the endometrial polyp on transvaginal sonography as hyperechogenic endometrial thickness and Figure 1B also shows SIS finding of the same patient as endometrial polyp. Figure 1D demonstrated the submucous fibroid lesion as hypo-echogenic intracavitary mass that have continuity with myometrium. Figure 2A shows the endometrial polyp with stalked, and Figure 2B demonstrates the submucous fibroid with round structure and protruding to the uterine cavity that observed on the diagnostic hysteroscopy.

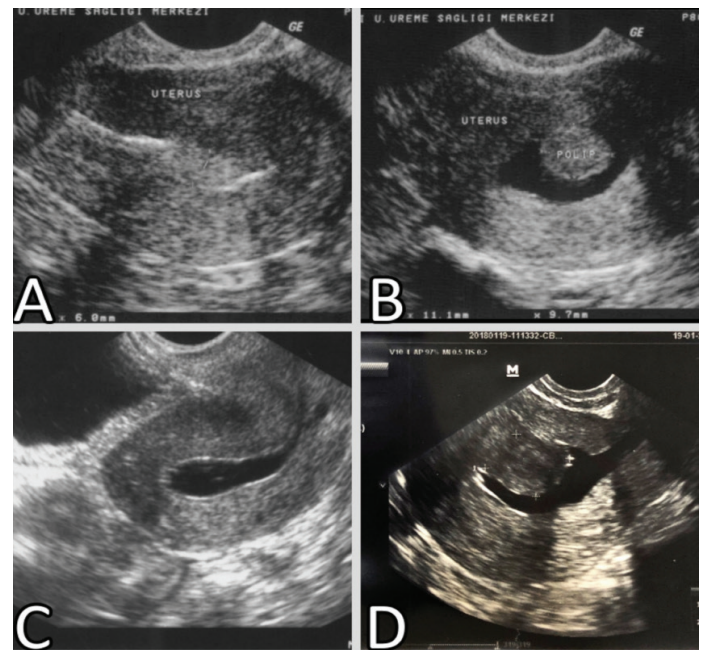


Figure 1. Transvaginal and saline infusion sonography of lesions. A. Endometrial polyp on transvaginal sonography B. Endometrial polyp on saline infusion sonography (A and B belongs to the same patient) C. Normal appearance on saline infusion sonography D. Submucous fibroid on saline infusion sonography

Statistical Analysis

The data were analyzed with the statistical program (SPSS, version 20; SPSS Inc., Chicago, IL, USA). The ROC(receiver operating characteristic) curves were obtained to compare the efficacy of TVS and SIS to determine the intracavitary space-occupying lesions. The ROC curves were compared and differences between their areas under the curve(AUC) were calculated and analyzed. A p value<0.05 was considered as statistical significant.

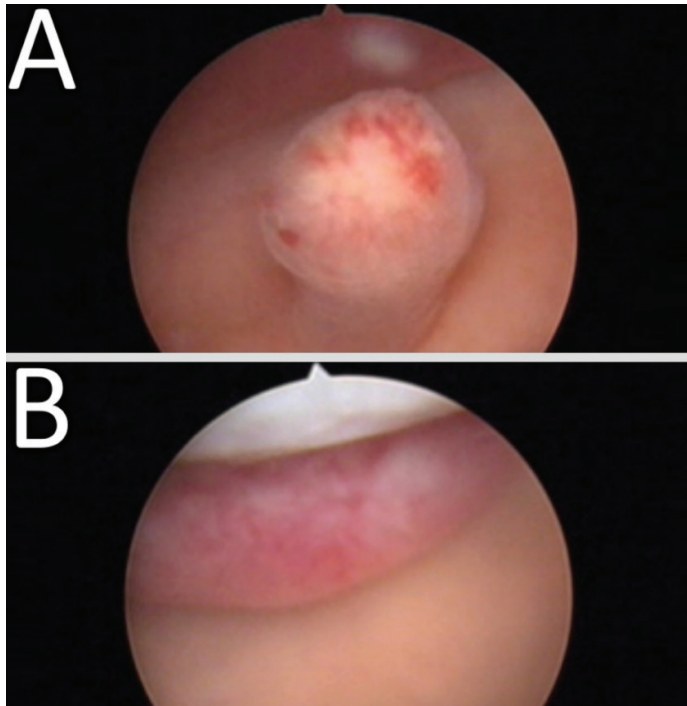


Figure 2. Hysteroscopic views of lesions. A. Endometrial polyp on hysteroscopy B. Submucous fibroid on hysteroscopy

RESULTS

A total of 413 infertile patients were evaluated retrospectively. The patients who did not tolerate the diagnostic hysteroscopy procedure were excluded (15 patients). The women who did not undergo all three procedures (5 patients) were also excluded from the study population. We have determined endometrial hyperplasia and uterine structural abnormalities in 70 patients and they were excluded because we aimed to determine the exact efficacy of TVS and SIS on the intracavitary space-occupying lesion evaluation.

Totally 100 patients were excluded and 323 patients

have consisted of the study population (Figure 3). The patients' characteristics are shown in Table 1. The mean age of patients was 30.0 ± 5.5 years and 86.5% was primary infertility. The prevalence of intracavitary space-occupying lesions was 18.89% and the prevalence of endometrial polyp and submucous fibroid were 17.34% and 1.55%, respectively.

Table 1. Demographic and clinical parameters of the patients

	Mean (SD)
Age(years)	30.0 (5.5)
Gravidity	0.2 (0.6)
BMI(kg/m ²)	25.1 (4.3)
Duration of infertility (years)	7.6 (4.3)
Infertility n (%)	
Primary	279 (86.5)
Secondary	44 (13.5)

SD, standard deviation BMI, boy mass index

We summarized the diagnosis of TVS, SIS, and diagnostic hysteroscopy in Figure 3. We assigned diagnostic hysteroscopy as a gold standard procedure and performed to all patients. The sensitivity, specificity, positive and negative predictive value and likelihood ratios of TVS and SIS are shown in Table 2. Interestingly, the specificity of TVS was higher than SIS for evaluating the endometrial polyp because TVS established endometrial polyp in 23 patients and all of them was true diagnosis. On the other hand; SIS established endometrial polyp in 41 patients with correct diagnosis but it also diagnosed 4 cases as false positive. The sensitivity and specificity calculation does not immediately compare each procedure with the others, so the evaluation of each method's diagnosis was studied using ROC analysis. The ROC curves of TVS and SIS for the diagnosis of the intracavitary lesions were shown in Figure 4.

Table 2. The diagnostic accuracy parameters of TVS and SIS for intracavitary lesions with respect to evaluation by DH

	Sensitivity (%)	Specificity (%)	PPV (%)	NPV (%)	LR(+)	LR(-)
Overall						
TVS	50.8	98.1	86.1	89.5	26.6	0.5
SIS	80.3	98.5	92.5	95.6	52.6	0.2
Polyp						
TVS	41.7	100.0	100.0	89.0	N/A	0.6
SIS	73.2	98.5	91.1	94.6	48.8	0.3
Fibroid						
TVS	100.0	97.5	38.5	100.0	39.7	0.0
SIS	100.0	99.1	62.5	100.0	106.0	0.0

TVS, transvaginal sonography SIS, saline infusion sonography DH, diagnostic hysteroscopy
PPV, positive predictive value NPV, negative predictive value LR, likelihood ratio

We have also performed analysis for each intracavitary lesion (endometrial polyps and fibroid) to determine the differences between TVS and SIS (Figure 4B and 4C), but only 5 submucosal fibroid cases were observed in the diagnostic hysteroscopy. Hence, we primarily aimed to evaluate the diagnostic accuracy of TVS and SIS for overall intracavitary space-occupying lesions. The pairwise comparison of AUC determined which method was the most accurate diagnostic procedure. The AUCs showed that SIS had statistically significantly higher diagnostic reliability compared to TVS in the diagnosis of the only endometrial polyp (AUC=0.859 and AUC=0.705,

respectively; $p < 0.0001$) (Figure 4B). Although there were only 5 cases for submucous fibroid, both of the two procedures had similar AUCs for the detection of submucous fibroid (AUC=0.987 and AUC=0.995 for TVS and SIS, respectively; $p = 0.02$) (Figure 4C). In general, saline infusion sonography yielded better results compared to TVS in the diagnosis of the intracavitary space-occupying lesions (AUC=0.894 and AUC=0.745, respectively; $p < 0.0001$) (Figure 4A). The accuracy rates of TVS and SIS were 89.16% and 95.05% for the diagnosis of intracavitary space-occupying lesions, respectively.

Table 3. The sensitivity, specificity, PPV and NPV of the reference studies evaluating the intracavitary lesions for TVS and SIS

Reference	Study Population	Endometrial Lesions	Sensitivity/Specificity(%)		PPV/NPV(%)	
			TVS	SIS	TVS	SIS
Ragni et al. 2005	Infertile patients (n=98) - Analyzed overall endometrial lesions	Overall	91 / 83	98 / 94	85.4 / 90	95 / 98
		Overall	56.3 / 72	81.3 / 100	56.3 / 72	100 / 88.9
Kelekci et al. 2005	Reproductive women (n=41)	Polyp	100 / 96.8	70 / 100	50 / 76.9	100 / 90.9
		Fibroid	-	100 / 100	-	100 / 100
		Overall	93 / 60	98 / 83	87 / 64	96 / 91
Bingol et al. 2011	Infertile patients (n=346)	Polyp	87 / 80	100 / 93	73 / 91	90 / 100
		Fibroid	95 / 96	99 / 98	92 / 97	96 / 99
Seshadri et al. 2014	Infertile patients prior to assisted reproductive techniques (Meta-analysis of 20 studies)	Overall	-	88 / 94	-	-
		Polyp	-	82 / 96	-	-
		Fibroid	-	82 / 100	-	-
Reda et al. 2016	Subfertile women with a history of repeated implantation failure (n=60)	Polyp	-	100 / 100	-	100 / 100
		Fibroid	-	100 / 100	-	100 / 100

TVS, transvaginal sonography SIS, saline infusion sonography
PPV, positive predictive value NPV, negative predictive value

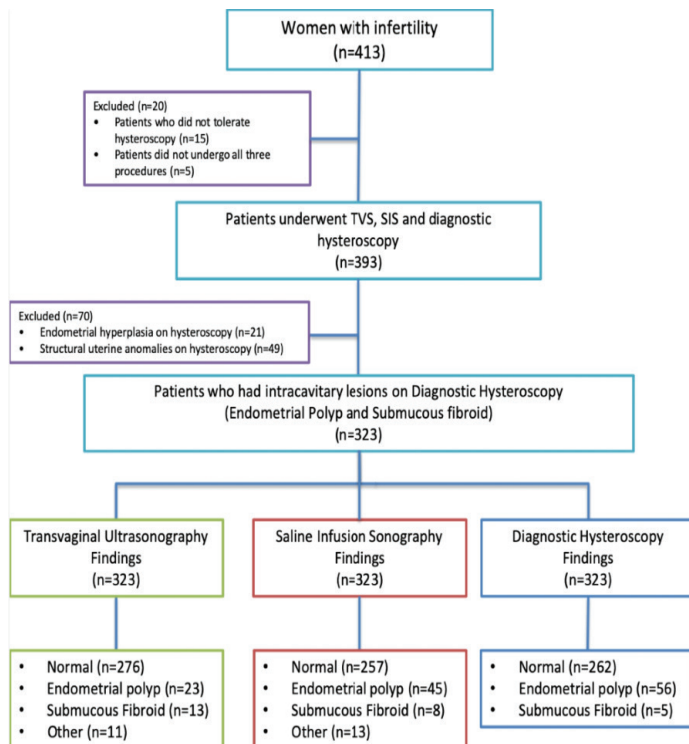


Figure 3. The flow-diagram of the study population




Figure 4. The comparison of ROC curve of TVS and SIS for intracavitary lesions; A. Overall B. Endometrial polyp C. Submucous fibroid

DISCUSSION

Based on the results of the current investigation, taken the office hysteroscopy as a gold standard diagnostic test, SIS had better sensitivity, specificity and predictive values for the detection of intracavitary space-occupying lesions (endometrial polyp and submucous fibroid) in comparison with TVS. It seems that SIS may be the first-line preference to evaluate the uterine cavity in the infertile population.

Uterine abnormalities associated with infertility were observed as 10-15% in couples who require diagnostic and therapeutic approaches(9). Another study established that endometrial polyps and submucous myomas were detected in the endometrial cavity of infertile women as 31.5% and 29.5%, respectively (10). Tokmak et al. demonstrated that infertility was established as 65.6% in younger patients who had endometrial polyp (11). We determined the overall intracavitary space-occupying lesions as 18.9% and the data regarding the categorization of the abnormalities were 17.4% and 1.5% for endometrial polyps and submucous fibroid, respectively. Our results were lower according to the literature, it might be based on the small sample size. It is substantial that to diagnose the uterine abnormalities accurately, because surgical correction of the pathologies may improve the treatment success of the infertile women (12,13). TVS is a simple and non-invasive tool to diagnose the uterine cavity abnormalities and it has good accuracy in some studies (2,14). Although TVS is generally used to evaluate the uterine pathologies in gynecology practice, the diagnostic efficiency of TVS is poor with especially intracavitary masses (15). Some studies have demonstrated poor diagnostic accuracy, sensitivity and positive predictive values in the detection of endometrial polyps (10,16). In our study, we established a higher accuracy rate (89.8%) for polypoid lesions compared to the literature findings. We have also observed that SIS had a sensitivity and specificity of 80.3% and 98.5%, respectively. In the literature, there were similar results for SIS on the intracavitary abnormalities. The sensitivity and specificity of SIS for diagnosing the uterine cavity abnormalities varies from 81% to 100% and from 70% to 100%, respectively (10, 16-18) (Table 3). SIS is an effective and safe method to assess the uterine cavity and it is also a minimally invasive and less expensive method (19). We can perform SIS in any phase of the menstrual cycle, but it is preferred in the follicular phase especially between 5 and 14 days, before the ovulation. SIS was found to be a sensitive tool to detect intracavitary lesions (17). Seshadri et al. have performed a meta-analysis and they demonstrated that SIS was a highly sensitive method to detect the polypoid lesions and submucous fibroid especially in infertile patients prior to IVF treatment (15). They also reported that the sensitivity and specificity of SIS were 82% and 96%, 82% and 100% for diagnosing the endometrial polyp and submucous fibroid, respectively (15). Kelekçi et al. showed higher sensitivity, specificity, PPV, and NPV of SIS compared to TVS in premenopausal women with or without abnormal uterine bleeding (18). Ragni et al.

compared the TVS and SIS to evaluate the intracavitary abnormalities in the infertile patient workup and they also showed higher sensitivity, specificity and predictive values for SIS(16). It was found that the diagnostic accuracy of SIS was significantly higher than TVS in the detection of endometrial polyp (95.8% and 70.8%, $p < 0.05$, respectively). Similar to Ragni et al., we have performed the current study to determine the effectiveness of SIS and TVS with the gold standard of DH and also observed higher values for SIS than TVS. Grimbizis et al. have performed a prospective comparative study in patients with abnormal uterine bleeding, postmenopausal bleeding, and infertility (20). The AUCs for TVS and SIS in the diagnosis of any intracavitary masses were 0.612 and 0.782, respectively. SIS has been found to be a much more reliable method for determining intracavitary masses than TVS ($p = 0.01$). Similar to our study, they compared the diagnostic efficacy of TVS and SIS for endometrial polyps and submucous fibroids, separately. SIS was again superior to those TVS findings in diagnosing the endometrial polyp and submucous fibroid ($p = 0.005$ and $p = 0.003$, respectively) (20). Our data concerning the accuracy of SIS in the detection of intracavitary space-occupying lesions (polyp and fibroid) were similar to literature findings and the AUC was significantly higher for SIS compared to TVS in the assessment of any intracavitary lesions (0.894 and 0.745; $p < 0.0001$, respectively). We have also found the higher diagnostic accuracies for SIS than TVS in diagnosing endometrial polyp and submucous fibroid when we analyze the abnormalities separately.

Hysteroscopy is considered as the "gold standard" for evaluating the uterine cavity in premenopause, postmenopause and infertility. Numerous studies have compared hysteroscopy to sonography, with or without saline solution infusion, all indicating that hysteroscopy is more accurate, with fewer false-positive and false-negative results (10,20,21). Hysteroscopy allows the clinicians to perform the diagnosis and treatment in one procedure concurrently and this ability may be a preference for patients(22). The sensitivity of diagnostic hysteroscopy is interpreted as almost 100% in the literature (10,23,24). Ogutcuoglu et al. reported that diagnostic hysteroscopy indicated an intracavitary mass in all patients whose histopathology results were endometrial polyp and/or submucous fibroid (25). Although the diagnostic hysteroscopy is a gold standard procedure to assess the intracavitary abnormalities, it is an invasive and relatively expensive procedure as well. The diagnostic hysteroscopy may detect most of the intracavitary pathologies, on the contrary, it has a disadvantage for assessment of myometrium concurrently (18,26). SIS is very effective especially for evaluating the submucous myomas. Kelekçi et al. demonstrated that SIS had very close diagnostic accuracy with the diagnostic hysteroscopy in detecting the submucous fibroid and it also could determine the intramural component of the myomas (18). In this study, the authors did not find any significant improvement by using the diagnostic hysteroscopy in comparison with

SIS. In a prospective study, SIS had sensitivity, specificity, and PPV of 95.7%, 100% and 100% in the evaluation of submucous myomas (27). It was also found that SIS was a more accurate method than TVS for evaluating the endometrial polyp ($p < 0.05$) (27). When TVS was combined with saline contrast in the uterine cavity, the diagnostic accuracy was markedly improved and was found to equal that of hysteroscopy when performed by skilled investigators. Milingo et al. established that SIS was an important screening modality for the diagnosis of focal intracavitary masses compared to the diagnostic hysteroscopy (28). Although the diagnostic hysteroscopy determined the structural anomalies and intrauterine adhesions with the sensitivity of 100 %, it was revealed that SIS and diagnostic hysteroscopy were equivalent efficacy tools for the detection of submucous myomas and endometrial polyps (18). The present study revealed the AUC value of SIS was high (0.894), and we demonstrated that SIS is almost as accurate as diagnostic hysteroscopy for infertile patients. Moreover, SIS is a more comfortable method for patients, therefore the diagnostic hysteroscopy should not be recommended for a patient who did not show any significant intracavitary pathology (16,29). In an observational study, the addition of SIS to TVS decreased the performing of the diagnostic hysteroscopy in 12% of cases (30). Grimbizis et al. also suggested performing SIS when an intracavitary mass suspicion was present in TVS (20). This approach may avoid performing an unnecessary diagnostic hysteroscopy. Otherwise, the clinician may decide whether diagnostic hysteroscopy is the most appropriate method for patients and prepare for a further hysteroscopy procedure properly. Ogutcuoglu et al. also recommended that unnecessary invasive procedures may be prevented by performing SIS before hysteroscopy (25). Reda et al. emphasized the important role of SIS in repeated implantation failure and they concluded that SIS might save the invasive procedure for selected cases (17). SIS may be an effective choice to evaluate the endometrial cavity in infertile patients as it is of higher accuracy, better tolerability, cost-effective and decreases the necessity of invasive procedures. However, SIS could be used in gynecology clinics that do not have enough opportunity as the first-line screening tool especially in developing countries.

Our study has some limitations. First, it was a retrospective study. One of the main limitations of the present study was the lack of histopathologic data which should verify each endometrial morphological changes noted by TVS, SIS, and diagnostic hysteroscopy. We did not include pathologies except endometrial polyp and submucous myomas such as hyperplasia and endometrial proliferation. We aimed to observe the impact of TVS and SIS regarding only the evaluation of endometrial polyp and submucous fibroid.

CONCLUSION

In conclusion; SIS is more effective than TVS because of its high sensitivity in the diagnosis of intracavitary space-

occupying lesions in infertile women. In the present investigation, two methods had comparable specificity and predictive values for the detection of intrauterine lesions when diagnostic hysteroscopy was taken as a gold standard diagnostic test. SIS is a reasonable alternative to the diagnostic hysteroscopy as an easy, safe and tolerable method for evaluating the uterine cavity in infertile women and the diagnostic hysteroscopy could be reserved for selected patients. Further studies have to be accomplished to assess the diagnostic efficacy of SIS as well as diagnostic hysteroscopy with related histopathological results in the infertile patient workup.

Competing interests: The authors declare that they have no competing interest.

Financial Disclosure: There are no financial supports.

Ethical approval: The study was approved by the institutional review board and the study protocol was in agreement with the Helsinki Declaration for Ethical Medical Research.

Vehbi Yavuz Tokgoz ORCID: 0000-0002-4113-385X

Tufan Oge ORCID: 0000-0002-6955-3717

Engin Korkmazer ORCID: 0000-0001-8318-2329

Ahmet Basar Tekin ORCID: 0000-0001-5856-7833

REFERENCES

1. Cakmak H, Taylor HS. Implantation failure: molecular mechanisms and clinical treatment. *Hum Reprod Update* 2011;17:242-53.
2. Shalev J, Meizner I, Bar-Hava I, et al. Predictive value of transvaginal sonography performed before routine diagnostic hysteroscopy for evaluation of infertility. *Fertil Steril* 2000;73:412-7.
3. Dubinsky TJ. Value of sonography in the diagnosis of abnormal vaginal bleeding. *J Clin Ultrasound* 2004;32:348-53.
4. Hajishaiha M, Ghasemi-Rad M, Karimpour N, et al. Transvaginal sonographic evaluation at different menstrual cycle phases in diagnosis of uterine lesions. *Int J Womens Health* 2011;3:353-7.
5. Yauger BJ, Feinberg EC, Levens ED, et al. Pre-cycle saline infusion sonography minimizes assisted reproductive technologies cycle cancellation due to endometrial polyps. *Fertil Steril* 2008;90:1324-6.
6. Shushan A, Rojansky N. Should hysteroscopy be a part of the basic infertility workup? *Hum Reprod* 2000;15:1650.
7. Lo KW, Yuen PM. The role of outpatient diagnostic hysteroscopy in identifying anatomic pathology and histopathology in the endometrial cavity. *J Am Assoc Gynecol Laparosc* 2000;7:381-5.
8. Nayak PK, Mahapatra PC, Mallick J, et al. Role of diagnostic hystero-laparoscopy in the evaluation of infertility: A retrospective study of 300 patients. *J Hum Reprod Sci* 2013;6:32-4.
9. Brown SE, Coddington CC, Schnorr J, et al. Evaluation of outpatient hysteroscopy, saline infusion hysterosonography, and hysterosalpingography in infertile women: a prospective, randomized study.

- Fertil Steril 2000;74:1029-34.
10. Bingol B, Gunenc Z, Gedikbasi A, et al. Comparison of diagnostic accuracy of saline infusion sonohysterography, transvaginal sonography and hysteroscopy. *J Obstet Gynaecol* 2011;31:54-8.
 11. Tokmak A, Ersoy E, Ersoy AO, et al. The Effect of Age on Clinical and Laboratory Parameters in Reproductive Age Women with Endometrial Polyps. *Gynecol Obstet Reprod Med* 2016;20:154-8.
 12. Mollo A, DeFranciscis P, Colacurci N, et al. Hysteroscopic resection of the septum improves the pregnancy rate of women with unexplained infertility: a prospective controlled trial. *Fertil Steril* 2009;91:2628-31.
 13. Pritts EA, Parker WH, Olive DL. Fibroids and infertility: an updated systematic review of the evidence. *Fertil Steril* 2009;91:1215-23.
 14. Vercellini P, Cortesi I, Oldani S, et al. The role of transvaginal ultrasonography and outpatient diagnostic hysteroscopy in the evaluation of patients with menorrhagia. *Hum Reprod* 1997;12:1768-71.
 15. Seshadri S, El-Toukhy T, Douiri A, et al. Diagnostic accuracy of saline infusion sonography in the evaluation of uterine cavity abnormalities prior to assisted reproductive techniques: a systematic review and meta-analyses. *Hum Reprod Update* 2015;21:262-74.
 16. Ragni G, Diaferia D, Vegetti W, et al. Effectiveness of sonohysterography in infertile patient work-up: a comparison with transvaginal ultrasonography and hysteroscopy. *Gynecol Obstet Invest* 2005;59:184-8.
 17. Reda A, Hamid AS, Mostafa R, et al. Comparison between findings of saline infusion sonohysterography and office hysteroscopy in patients with recurrent implantation failure. *J Hum Reprod Sci* 2016;9:236-40.
 18. Kelekci S, Kaya E, Alan M, et al. Comparison of transvaginal sonography, saline infusion sonography, and office hysteroscopy in reproductive-aged women with or without abnormal uterine bleeding. *Fertil Steril* 2005;84:682-6.
 19. de Kroon CD, de Bock GH, Dieben SW, et al. Saline contrast hysterosonography in abnormal uterine bleeding: a systematic review and meta-analysis. *BJOG* 2003;110:938-47.
 20. Grimbizis GF, Tsolakidis D, Mikos T, et al. A prospective comparison of transvaginal ultrasound, saline infusion sonohysterography, and diagnostic hysteroscopy in the evaluation of endometrial pathology. *Fertil Steril* 2010;94:2720-5.
 21. Yenigul N, Yazici Yilmaz Y, Bahat N, et al. The comparison of transvaginal ultrasonography and hysteroscopy in women with abnormal uterine bleeding: A single center experience. *Annals of Medical Research* 2019;26:1112-7.
 22. van Dongen H, Timmermans A, Jacobi CE, et al. Diagnostic hysteroscopy and saline infusion sonography in the diagnosis of intrauterine abnormalities: an assessment of patient preference. *Gynecol Surg* 2011;8:65-70.
 23. Almog B, Shalom-Paz E, Shehata F, et al. Saline instillation sonohysterography test after normal baseline transvaginal sonography results in infertility patients. Is it justified? *Gynecol Endocrinol* 2011;27:286-9.
 24. van Dongen H, de Kroon CD, Jacobi CE, et al. Diagnostic hysteroscopy in abnormal uterine bleeding: a systematic review and meta-analysis. *BJOG* 2007;114:664-75.
 25. Ogutcuoglu B, Karadag C, Inan C, et al. Diagnostic utility of saline infusion doppler sonohysterography in endometrial mass lesions. *Pak J Med Sci* 2016;32:284-8.
 26. Pasrija S, Trivedi SS, Narula MK. Prospective study of saline infusion sonohysterography in evaluation of perimenopausal and postmenopausal women with abnormal uterine bleeding. *J Obstet Gynaecol Res* 2004;30:27-33.
 27. Erdem M, Bilgin U, Bozkurt N, et al. Comparison of transvaginal ultrasonography and saline infusion sonohysterography in evaluating the endometrial cavity in pre- and postmenopausal women with abnormal uterine bleeding. *Menopause* 2007;14:846-52.
 28. Milingos S, Kallipolitis G, Stefanidis K, et al. Saline contrast hysterosonography in infertile patients and in women with abnormal uterine bleeding. *Eur J Gynaecol Oncol* 2005;26:564-7.
 29. van Dongen H, de Kroon CD, van den Tillaart SA, et al. A randomised comparison of vaginoscopic office hysteroscopy and saline infusion sonography: a patient compliance study. *BJOG* 2008;115:1232-7.
 30. Short J, Sharp B, Elliot N, et al. Does the addition of saline infusion sonohysterography to transvaginal ultrasonography prevent unnecessary hysteroscopy in premenopausal women with abnormal uterine bleeding? *Aust N Z J Obstet Gynaecol* 2016;56:432-5.