

Inverstigation of corneal and lens densitometry in eyes of patients with primary myelofibrosis

Ugur Yilmaz, Gulsum Akgun Cagliyan, Burak Akbay

Department of Ophthalmology, Faculty of Medicine, Pamukkale University, Denizli, Turkey

Copyright@Author(s) - Available online at www.annalsmedres.org

Content of this journal is licensed under a Creative Commons Attribution-NonCommercial 4.0 International License.



Abstract

Aim: To investigate the corneal-lens densitometry and endothelial cells of Primary myelofibrosis patients.

Materials and Methods: We evaluated 49 eyes of 49 primary myelofibrosis patients on follow up in hematology clinic and compared to 46 eyes of 46 age and sex-matched control group. The Scheimpflug images of 90–270 degrees by Pentacam HR (Oculus Optikgeräte GmbH, Wetzlar, Germany) were used for measurement. After pupil dilatation, the corneal apex was marked by pentacam automatically and the diameter of central 6 mm around marked point was analyzed. PNS (Pentacam Nuclear Staging) software was used for densitometric analysis of the lens from a cylindrical region in the nucleus center. Specular Microscope CEM-530 (Nidek, Japan) was used for endothelial cell analysis.

Results: There was no statistically significant difference between groups for age and gender (Table 1). Corneal density and corneal volume were higher in the patient group but it was not statistically significant (respectively $p=0.390$, $p=0.078$). Lens density was found as statistically significantly higher in the patient group compared to the control group ($p<0.001$). For the corneal endothelial analysis by specular microscopy, there was no statistically significant difference for cell density, the coefficient of variant and endothelial hexagonality (respectively, $p=0.546$, 0.671 , 0.103).

Conclusion: Primary myelofibrosis does not affect corneal densitometry and corneal endothelial cells. However, there is a higher lens densitometric measurement in Primary myelofibrosis compared to the control healthy group.

Keywords: Corneal densitometry; lens densitometry; primary myelofibrosis; specular microscopy

INTRODUCTION

Primary myelofibrosis (PMF) is a chronic clonal myeloid disorder characterized by anemia, splenomegaly, immature granulocytes, increased CD34 positive cells, erythroblasts and tear-drop shaped red cells in the blood, marrow fibrosis, and osteosclerosis (1). Fibrotic reaction develops in a different parts of the body than the bone marrow (2,3). The megakaryocytes are crucial in PMF pathogenesis due to the generating profibrotic, angiogenic and proinflammatory cytokines. Megakaryocyte derived, PDGF is associated with bone marrow fibrosis (4).

Collagen types that the fibrous network contains are type I, III, IV, and V in PMF. Microvessel density and marrow blood flow is increased in these patients. The changes may be related to an increased level of circulating endothelial cell progenitors like thrombopoietin, IL-1, and IL-11 elevated in the serum. Fibroblasts differentiate hematopoietic neoplastic stem cell in PMF and that fibroblast proliferation and enhanced collagen synthesis are secondary results of abnormal hematopoiesis (5).

Inflammatory cytokines including IL-1, IL-6, IL-8, TNF- α and C reactive protein are also markedly elevated and play a role in the constitutional symptoms seen in patients with progressive disease. Increased inflammatory cytokines levels can affect the fibroblastic activity and collagen structure. Disruption of the collagen structure of the cornea and lens causes opacity and increased density in these structures.

Cornea and lens densitometry is a noninvasive and quantitative measurement giving information about corneal and lens clarity. It can be measured by the Pentacam HR (Oculus, Wetzlar, Germany) using a rotating Scheimpflug camera that gives images of the anterior segment of the eye from the corneal surface to posterior lens epithelium. Corneal endothelium has an important role in regulating the fluid balance of the cornea. In endothelial dysfunction, the transparent structure of the cornea is disrupted and its density increases. Specular microscopy gives information about corneal endothelial cells such as cell counts and morphological features.

Received: 27.04.2020 **Accepted:** 12.08.2020 **Available online:** 25.05.2021

Corresponding Author: Ugur Yilmaz, Department of Ophthalmology, Faculty of Medicine, Pamukkale University, Denizli, Turkey

E-mail: druguryilmaz1982@gmail.com

In our study, it is aimed to investigate whether corneal endothelial cells, corneal and lens densitometry are affected by increased inflammatory cytokines in PMF. So corneal-lens densitometry and endothelial cells of the patients group were compared to the healthy control group.

MATERIALS and METHODS

Patients and Study Design

We evaluated 49 eyes of 49 PMF patients on follow up in hematology clinic and compared to 46 eyes of 46 age and sex-matched control group. Patients with corneal pathology including previous trauma, corneal ectasia like keratoconus, keratitis, previous corneal and intraocular surgery, glaucoma, cataract, diabetic retinopathy were excluded. Forty-one patients were receiving hydroxiurea and eight patients were receiving ruxolitinib therapies at the time of examination. The study was approved by the Review Board of Pamukkale University Medical School and conducted in accordance with Helsinki Declaration. Protocol number is 60116787-0208333.

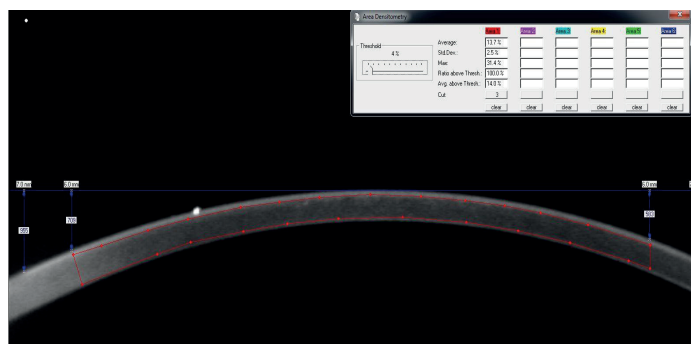


Figure 1. Corneal densitometry measurement

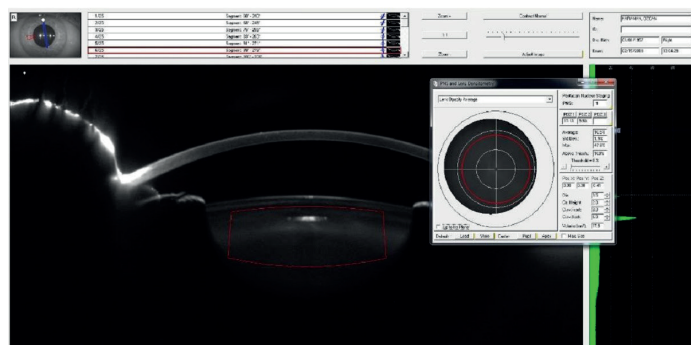

Figure 2. Lens densitometry measurement

Measurement

The Scheimpflug images by Pentacam HR (Oculus Optikgeräte GmbH, Wetzlar, Germany) was used for corneal-lens densitometry and corneal volume. The Scheimpflug images of 90–270 degrees were used for measurement. After pupil dilatation, the corneal apex was marked by pentacam automatically and the diameter of central 6 mm around marked point was analyzed (Figure 1). PNS (Pentacam Nuclear Staging) software was used for densitometric analysis of the lens from a cylindrical region in the nucleus center (Figure 2). Specular Microscope CEM-530 (Nidek, Japan) was used for endothelial cell analysis.

Statistical Analysis

All statistical analyses were performed by SPSS21 software (IBM Corporation, Armonk, NY, USA). Independent sample T-test was used for comparison of age, corneal-lens densitometry and corneal endothelial parameters between groups. Chi-Square test was used to compare groups for gender. Values less than 0.05 was accepted as statistically significant.

RESULTS

There was no statistically significant difference between groups for age and gender (Table 1). The numbers (the ratio) of systemic diseases in the groups were similar instead of Diabetes Mellitus (DM) (Table 2). DM was more common in the control group.

Table 1. Demographic characteristics of groups

	Groups		P
	Patient n(%)	Control n(%)	
Age (Average)	56.34	54.50	0.346
Gender			
Male	19 (%38.8)	17 (%37.0)	0.512
Female	30 (%61.2)	29 (%63.0)	
Total	49 (%100)	46 (%100)	

Table 2. Comparison of systemic diseases of two groups

Systemic Diseases	Groups	
	Patient n(%)	Control n(%)
No disease	22 (%44,9)	15 (%32,6)
Diabetes Mellitus	1(%2)	9 (19,6)
Hypertension	10 (%20,4)	11 (%23,9)
Coronary Artery Disease	3 (%6,1)	1 (%2,2)
More than one diseases	13 (%26,5)	10 (%21,7)
Total	49(%100)	46(%100)

Table 3. Corneal, lens density and corneal endothelial parametres

	Groups		P
	Patient n(%)	Control n(%)	
Corneal density	12.84 ± 1.52	12.33 ± 1.28	0.078
Lens density	9.61 ± 1.76	8.48 ± 0.69	0.000
Corneal Volume	421.04 ± 80.97	409.15 ± 47.93	0.390
Specular Microscopy			
CD	2444	2484 ± 281	0.546
CV	30.75 ± 6.05	30.21 ± 6.05	0.671
HEX	68.83 ± 5.30	67.00 ± 5.48	0.103

CD: Cell Density CV: Coefficient of Variant HEX: Hexagonality

Corneal density and corneal volume were higher in the patients with primary myelofibrosis group but it was not statistically significant (respectively $p=0.390$, $p=0.078$). Lens density was found as statistically significantly higher in the patient group compared to the control group ($p<0.001$) (Table 3). For the corneal endothelial analysis by

specular microscopy, there was no statistically significant difference for cell density, the coefficient of variant and endothelial hexagonality(respectively, $p=0.546$, 0.671 , 0.103) (Table 3).

DISCUSSION

There are some case reports, related to ocular involvement in PMF disease(6-9). Kim and Yu reported bilateral retinal neovascularization secondary to ischemia-induced by vaso-occlusive retinopathy like sickle retinopathy in a myelofibrosis patient. They concluded that increased levels of fibroblast growth factor and vascular endothelial growth factor lead to neovascularization(6). Neufeld et al. described upper eyelid ptosis secondary to massive tarsal thickening secondary to myelofibrosis. The pathologic evaluation showed thickening and sclerosis of the connective tissue between the orbicularis oculi muscle and the tarsal plate and a thickened tarsal plate due to meibomian gland hyperplasia(7). Also, the patient had cataract surgery at the age of 35. Haskes and Gagnon reported vitreous hemorrhage in a myelofibrosis patient. They thought retinal changes are the result of inefficiency and irregularity of blood cell production(8). Lin et al. reported serous retinal detachments, choroidal effusion and angle closure glaucoma secondary to tumoral invasion in a myelofibrosis patient. They showed that ocular tumoral invasion may be present in myelofibrosis(9).

Ocular complications of PMF are mostly related to hypercoagulation and increased fibrotic activity. So we investigated whether increased fibroblastic activity in PMF affects optical transparency of cornea and lens.

To our best knowledge, there is no study in the literature on this topic. Our results show that PMF does not affect the corneal densitometric analysis and corneal endothelial cells. Besides, we found higher densitometric analysis for the lens in the patient group.

Increased levels of IL-6 in the aqueous found to be associated with lens opacity and cataract(10, 11). Dudek et al. found that increased TNF alfa levels may contribute to cataract development by affecting an oxidant-sensitive transcription factor(12). Increased cytokines leading to sclerosis and fibrosis are well known in myelofibrosis. One of them is platelet-derived growth factor(PDGF), derived from megakaryocyte causes marrow fibrosis in Myelofibrosis(4). PDGF promotes myofibroblast proliferation, chemotaxis and induces collagen synthesis. PDGF-D is localized to iris and ciliary body in the anterior segment of the eye. It induces lens epithelial cells migration and differentiation(13). Ray et al. found that antibody to PDGF-D is able to reduce lens epithelial cell proliferation in intact rat eye anterior segments in organ culture(14). Increased levels of inflammatory cytokines and PDGF-D secondary to induced inflammatory cytokines may be the reason for higher lens densitometry in the patient group compared to the control group.

After cataract surgery, residual lens epithelial cells can lead to posterior capsular fibrosis by transforming to profibrotic myofibroblasts(13). TGF beta has a key role

in this fibrotic activity. Capsular fibrosis affects optical transparency and densitometry.

On the other hand, excessive reactive oxygen species secondary to increased inflammation and ischemia is seen in the myeloproliferative neoplasms(15). Oxidative stress in the anterior segment causes cataracts in the lens(16). Protein oxidation, DNA damage, and lipid peroxidation are responsible for lens cell damage by oxidative stress in cataractogenesis(17). Increased oxidative stress may be the other reason for high lens densitometry in the patient group according to our study.

LIMITATIONS

We did not measure PDGF-D isoform and reactive oxygen species. If we were able to do so, our hypothesis would be stronger with laboratory data.

CONCLUSION

In conclusion, PMF does not affect corneal densitometry and corneal endothelial cells. However, there is a higher lens densitometric measurement in PMF compared to the control healthy group. High lens densitometry is an early sign of cataractogenesis. Increased inflammatory cytokines, oxidative stress and PDGF levels may be the reason for higher lens densitometry in the patient group. Further studies should be done on this topic.

Competing interests: The authors declare that they have no competing interest.

Financial Disclosure: There are no financial supports.

Ethical approval: The study was approved by the Institutional Review Board of Pamukkale University (60116787-020 / 8333).

REFERENCES

1. K Kaushansky, MA Lichtman, E Beutler, et al. Primary Myelofibrosis. Williams Hematology 8th Edition. 2010;1381-99.
2. Fontenay-Roupie M, Dupuy E, Berrou E, et al. Increased proliferation of bone marrow-derived fibroblasts in primitive hypertrophic osteoarthropathy with severe myelofibrosis. Blood 1995;85:3229-38.
3. Tanaka H, Maehama S, Imanaka F, et al. Pachydermoperiostosis with myelofibrosis and anemia: report of a case of anemia of multifactorial causes and its improvement with steroid pulse and iron therapy. Jpn J Med 1991;30:73-80.
4. Bonner JC. Regulation of PDGF and its receptors in fibrotic diseases. Cytokine Growth F R 2004;15:255-73.
5. Barosi G. Essential thrombocythemia vs early/prefibrotic myelofibrosis: why does it matter. Best Pract Res Clin Haematol 2014;27:129-140.
6. Kim MJ, Yu HG. Case of bilateral retinal neovascularization associated with chronic idiopathic myelofibrosis. Korean J Ophthalmol 2010;24:131-3.
7. Neufeld KR, Price K, Woodward JA. Massive eyelid thickening in pachydermoperiostosis with myelofibrosis. Ophthalmic Plast Reconstr Surg 2009;25:316-8.

8. Haskes C, Gagnon K. Retinal manifestations of idiopathic myelofibrosis, a hematologic disorder. *J Am Optom Assoc* 1998;69:319-28.
9. Lin AL, Burnham JM, Pang V, et al. Ocular manifestations of primary myelofibrosis. *Retin Cases Brief Rep* 2016;10:364-7.
10. Nishi O, Nishi K, Ohmoto Y. Synthesis of interleukin-1, interleukin-6, and basic fibroblast growth factor by human cataract lens epithelial cells *J Cataract Refr Surg* 1996;22: 852-8
11. Klein EKB, Klein R, Lee KE, et al. Markers of inflammation, vascular endothelial dysfunction, and age-related cataract *Am J Ophthalmol* 2006;141:116-22.
12. Dudek EJ , Shang F, Taylor A. H₂O₂-mediated oxidative stress activates NF- κ B in lens epithelial cells *Free Radic Biol Med* 2001;31:651-8.
13. Wormstone IM, Wang L, Liu CS. Posterior capsule opacification. *Exp Eye Res* 2009;88:257-69.
14. Ray S, Gao C, Wyatt K, et al. Platelet-derived growth factor D, tissue-specific expression in the eye, and a key role in control of lens epithelial cell proliferation. *J Biol Chem* 2005;280:8494-502.
15. Mads Emil Bjørn and Hans Carl Hasselbalch. The Role of Reactive Oxygen Species in Myelofibrosis and Related Neoplasms. *Mediators Inflamm* 2015;648090.
16. Brennan LA1, Kantorow M. Mitochondrial function and redox control in the aging eye: role of MsrA and other repair systems in cataract and macular degenerations. *Exp Eye Res* 2009;88:195-203.
17. Babizhayev MA1, Deyev AI, Yermakova VN, et al. Lipid peroxidation and cataracts: N-acetylcarnosine as a therapeutic tool to manage age-related cataracts in human and in canine eyes. *Drugs R D* 2004;5:125-39.