



The first uniportal VATS sleeve lobectomy in Türkiye: A case report

Hakki Ulutas^{a,*}, İlham Gulcek^b, Muhammed Kalkan^c

^aUniversity of Economics, Faculty of Medicine, Medical Point Hospital, Department of Thoracic Surgery, İzmir, Türkiye

^bGaziantep City Hospital, Clinic of Thoracic Surgery, Gaziantep, Türkiye

^cInonu University, Faculty of Medicine, Department of Thoracic Surgery, Malatya, Türkiye

Abstract

In recent years, video-assisted thoracic surgery (VATS) has become the gold standard approach in the surgical treatment of early-stage non-small cell lung cancer. Especially in cases of central tumors, sleeve lobectomies that preserve parenchyma and respiratory reserves are performed instead of pneumonectomies by experienced clinics. Here, we present the first case of uniportal VATS right bronchial sleeve upper lobectomy for right main bronchial invasion in Turkey, which was successfully performed in August 2022.

A patient diagnosed with laryngeal carcinoma who had been in remission for 5 years complained of a cough. Computed thoracic tomography showed hilar peribronchial thickening and an endobronchial lesion (EBL) extending from the right upper lobe bronchus to the main bronchus, almost completely obstructing the upper lobe bronchus. Bronchoscopy revealed that the right upper lobe entrance was obstructed with EBL, and its distance to the carina was 1.6 cm. Bronchoscopic biopsy revealed squamous cell carcinoma.

The thorax was entered through an incision of approximately 3 cm in the right fifth intercostal space. First, the right upper lobe pulmonary arteries and superior pulmonary vein were dissected and cut. The main bronchus was divided until the intermediate bronchus. With the help of an endoscissor, the main and intermediate bronchus were incised with appropriate surgical margins, and the lobectomy material was removed. Both macroscopic appearance and frozen and microscopic main and intermediate bronchus surgical margin tumor negativity were confirmed. One suture was passed through the lateral cartilage from the inside out, and the needle was fixed to the posterior pleura. Membranous and cartilage parts were continuously anastomosed with a double-needle 3/0 prolene suture at 2–3 mm intervals. Pathological evaluation confirmed squamous cell carcinoma with a tumor diameter of 1.7 cm, hilar 1/11 lymph node metastasis, and negative surgical margin.

Adhering to oncologic principles, sleeve resections, which are difficult even with the currently known open techniques, can be performed effectively and safely with uniportal VATS in experienced centers.

ARTICLE INFO

Keywords:

Uniportal VATS
Sleeve lobectomy
Anastomosis
Lung cancer

Received: Nov 01, 2023

Accepted: Mar 18, 2024

Available Online: 25.03.2024

DOI:

[10.5455/annalsmedres.2023.11.295](https://doi.org/10.5455/annalsmedres.2023.11.295)



Copyright © 2024 The author(s) - Available online at www.annalsmedres.org. This is an Open Access article distributed under the terms of Creative Commons Attribution-NonCommercial-NoDerivatives 4.0 International License.

Introduction

: In recent years, video-assisted thoracic surgery (VATS) has become the gold standard approach in the surgical treatment of early-stage non-small cell lung cancer (NSCLC). Minimally invasive surgical approaches are known to reduce morbidity and mortality [1]. Bronchoplastic procedures are required in 3–19% of lung cancer surgical treatments [2]. Especially in central tumors, sleeve lobectomies that preserve parenchyma and respiratory reserves are performed by experienced clinics instead of pneumonectomies.

Sleeve resections, which are complex and difficult even in open surgery, were initially contraindicated in VATS approaches and are now performed by VATS only in experienced centers [3,4]. Postoperative pain, morbidity, and length of hospital stay are reported to be lower with VATS approaches performed through a single incision (port) because less tissue is cut since the ribs are not separated [5].

The first sleeve resection with uniportal VATS was performed by Ganzales-Rivas et al. in 2013. In our country, sleeve resections with multiportal VATS have been reported [6]. Here, a case of right bronchial sleeve upper lobectomy by uniportal VATS, performed in August 2022 to treat right main bronchial invasion and successfully managed following oncologic principles in the Department

*Corresponding author:

Email address: drhakkiulutas@yahoo.com (Hakki Ulutas)

of Thoracic Surgery, Turgut Ozal Medical Center, Inonu University Faculty of Medicine, is presented.

Case Report

A 61-year-old man presented with a cough, which had been present for about 2 weeks and was accompanied by occasional dyspnea. He had received radiotherapy for laryngeal carcinoma 5 years ago and was being followed in remission. He had a smoking history of approximately 60 packs/year and quit after laryngeal cancer. Physical examination and laboratory tests revealed no significant pathology. Thoracic computed tomography (TCT) was performed after an infiltrative mass was observed in the right paracardiac area via chest radiography. On the TCT scan, hilar peribronchial thickening and an endobronchial lesion (EBL) extending from the right upper lobe bronchus to the main bronchus and almost completely obstructing the upper lobe bronchus were observed (Figure 1). Flexible bronchoscopy showed that the right upper lobe entrance was obstructed with the EBL, and its distance to the carina was 1.6 cm. The biopsy obtained from the lesion revealed squamous cell carcinoma. Positron emission tomography revealed no other pathologic involvement in the body except for a right upper lobe central mass. Pulmonary function tests showed FEV1 of 2400 ml (80%), FVC of 3300 ml (87%), and FEV1/FVC of 72%. Right sleeve upper lobectomy was planned for the complex operable patient with no distant metastasis.

The patient was intubated with a double lumen endotracheal tube, and the thorax was entered through a 3 cm uniportal incision through the anteroaxillary fifth intercostal space in the right lateral decubitus position. As with all uniportal approaches, we secured the 30-degree camera to the surgical drape with number 1 silk to provide better exposure of the intrathoracic cavity to the assistant and facilitate the use of other instruments through

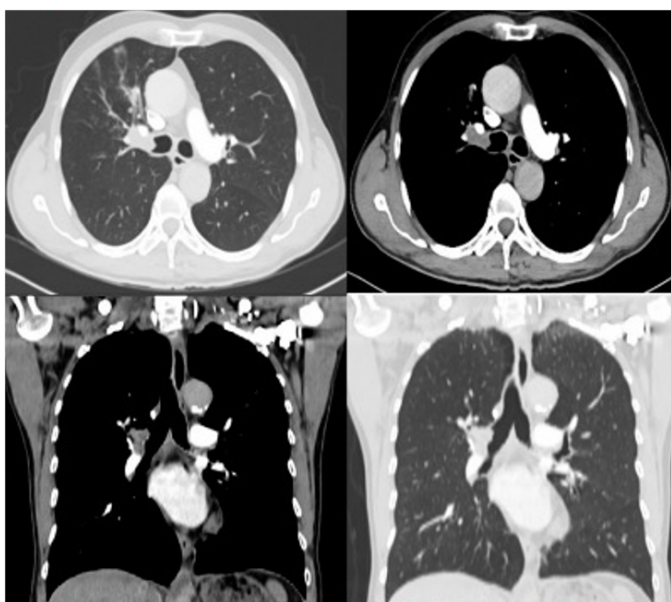


Figure 1. Thorax CT image of an endobronchial tumor extending towards the main bronchus at the entrance of the right upper lobe.

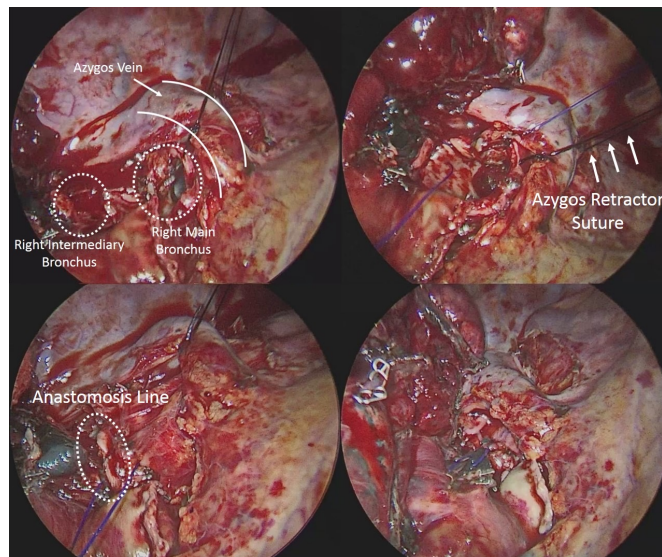


Figure 2. *Left upper figure;* the main bronchus and intermediate bronchus and azygos vein sling after removal of the upper lobe. *Right upper figure;* beginning of anastomosis with prolene suture. *Left and right lower figure;* after the anastomosis is completed.

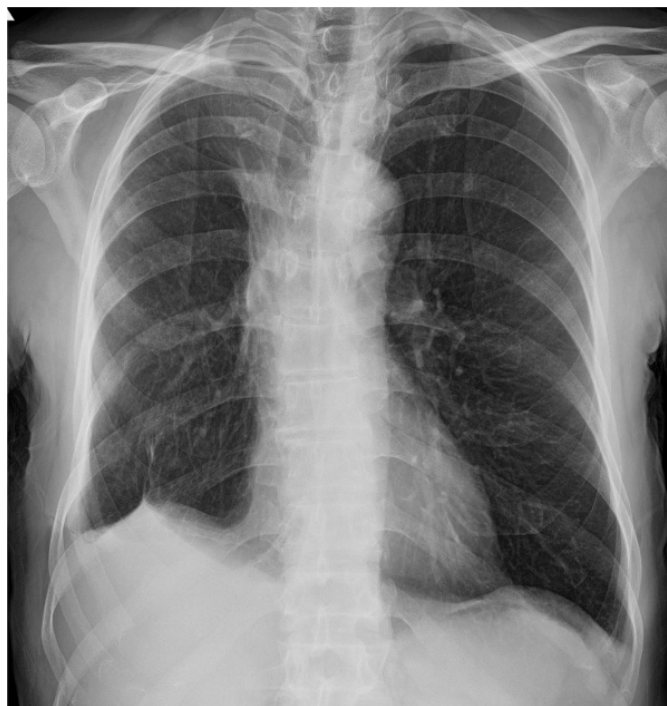

Figure 3. Postoperative 15 month chest radiography.

the same port. Minimal adhesions were separated by sharp and blunt dissection with the help of energy devices, and the parenchyma was freed. First, the right upper lobe pulmonary arteries and superior pulmonary vein were dissected and cut. The incomplete fissure was opened with an endostapler. The main bronchus was divided until the intermediate bronchus. The main and intermediate bronchus were cut with the help of an endoscissor with appropriate surgical margins, and the lobectomy material was removed. Both macroscopic appearance and frozen

and microscopic main bronchus and intermediate bronchus surgical margin tumor negativity were confirmed. The mediastinal pleura was opened, and lymph nodes 7, 9, and 10 were dissected. Before anastomosis, the azygos vein was turned and fixed to the chest wall with a tying suture, and the azygos vein was removed from the anastomosis line and appropriate exposure was provided. One suture was passed through the lateral cartilage from the inside out, and the needle was fixed to the posterior pleura. Membranous and cartilage parts were continuously anastomosed with a double-needle 3/0 prolene suture at 2–3 mm intervals. The azygos vein was fixed to the anastomosis line for support. No intraoperative complications developed, and the operation was completed with UVATS after air leak control (Figure 2). Prolonged postoperative air leak originating from the parenchyma was treated with a second tube thoracostomy. Pathological evaluation confirmed squamous cell carcinoma, with a tumor diameter of 1.7 cm, hilar 1/11 lymph node metastasis, and negative surgical margin (T2N1M0=Stage 2B). The anastomosis line was checked with flexible bronchoscopy on the seventh postoperative day. The chemotherapy patient has subsequently been followed up for 15 months without any problems (Figure 3).

Discussion

Currently, complex cases requiring parenchyma-sparing sleeve resections, which are difficult even in open surgery, are frequently performed by VATS-experienced surgeons with multiportal VATS [7,8,9]. Additionally, these procedures are performed in a limited number of centers with uniportal VATS. The work of Diego Gonzales-Rivas, the pioneer of the uniportal VATS approach and other such specialized surgeries, is known globally [10]. The challenges of uniportal VATS include the entry of the camera and surgical instruments through the same port, difficulty in maneuvering the instruments, and high contamination rate of the camera. We minimized these problems by holding the camera in front of the assistant surgeon, fixing the camera to the sterile drape with a silk suture, providing better maneuverability by inserting the surgical instruments under the camera, and wiping off camera contamination with a hazelnut tampon without removing the camera. In our country, the uniportal VATS approach is applied in very few centers. In the study “Learning Curve for Uniportal VATS Anatomical Pulmonary Resections” published in January 2023, Gürz et al. reported that uniportal VATS sleeve resection was performed in one case. However, detailed data about the case have not been shared. Additionally, cases that were converted to open were reported in this article. It is not stated whether the sleeve lobectomy case was converted to open or completed with uniportal VATS [11]. In our opinion, to perform sleeve resections with uniportal VATS, the clinic should have prior experience with at least 200–250 cases of uniportal VATS resection.

Right bronchial sleeve upper lobectomy is a sleeve lobectomy group with a high degree of difficulty due to right main bronchus shortness, main bronchus-intermediate bronchus diameter difference, pulmonary artery, and azygos vein localizations. Incision through the right fourth

intercostal space has been recommended [10]. We completed the surgery through a uniportal incision from the fifth intercostal space as in standard resections. There is no difference in the main principles of VATS sleeve resections and open sleeve resections. There is no consensus on anastomotic technique in VATS sleeve resections. A study by Palade et al. reported that in sleeve resections, there was no significant difference between separate and continuous sutures regarding postoperative complications [12]. Rivas et al. applied a continuous technique with monofilament absorbable or non-absorbable double-needle sutures in bronchial sleeve resections [10]. Different approaches using absorbable or non-absorbable 3/0 or 4/0 sutures exist. In the present case, we used monofilament non-absorbable (3/0) double-needle suture and continuous suture techniques separately on the membranous and cartilage parts. We think that the continuous technique is simpler and faster. In the uniportal VATS sleeve lobectomy technique, an important trick we applied to prevent the tangling of sutures is the fixation of one suture needle to the posterior pleura. In this manner, the sutures were prevented from tangling in the surgical field and hindering anastomosis. The first stitch is placed inside-out at the far border between the cartilaginous and membranous parts of the proximal bronchial tree and then connected outside-in to the distal bronchial tree, progressing counter-clockwise and incorporating the entire bronchial wall. Intercostal muscle flaps, thymopericardial fatty tissues, mediastinal pleura, and azygos veins can be used to support the anastomosis line. However, approaches differ between clinics, and no standardized approach exists. In our case, the live azygos vein was supported by the anastomosis line.

Conclusion

The most important principle in lung cancer surgery is to act following oncologic principles. In selected complex cases with limited respiratory reserve, sleeve resections instead of pneumonectomies provide significant advantages regarding morbidity and mortality. Adhering to oncologic principles, sleeve resections, which are difficult even with today’s known open techniques, can be performed effectively and safely with uniportal VATS in experienced centers.

References

1. Kocher GJ. Multiport and uniportal VATS sleeve resections. *J Thorac Dis* 2019;11(4):1091-1093. doi: 10.21037/jtd.2019.02.92.
2. Yamamoto K, Miyamoto Y, Ohsumi A, Kojima F, Imanishi N, Matsuoka K, et al. Sleeve lung resection for lung cancer: Analysis according to the type of procedure. *J Thorac Cardiovasc Surg* 2008;136:1349-56. doi: 10.1016/j.jtcvs.2008.05.018.
3. Hanna JM, Berry MF, D’Amico TA. Contraindications of video-assisted thoracoscopic surgical lobectomy and determinants of conversion to open. *J Thorac Dis* 2013;5 Suppl 3:S182-9. doi: 10.3978/j.issn.2072-1439.2013.07.08.
4. Paul S, Altorki NK, Sheng S, Lee PC, Harpole DH, Onaitis MW, et al. Thoracoscopic lobectomy is associated with lower morbidity than open lobectomy: A propensity-matched analysis from the STS database. *J Thorac Cardiovasc Surg* 2010;139:366-78. doi: 10.1016/j.jtcvs.2009.08.026.
5. Harris CG, James RS, Tian DH, et al. Systematic review and meta-analysis of uniportal versus multiportal video-assisted thoracoscopic lobectomy for lung cancer. *Ann Cardiothorac Surg* 2016;5:76-84.

6. Acar A, Ceylan KC. VATS sleeve resections. *Turk Gogus Kalp Dama* 2023;31(Suppl 1):S45-S53. doi: 10.5606/tgkdc.dergisi.2023.24737.
7. Chen H, Huang L, Xu G, Zheng B, Zheng W, Zhu Y, et al. Modified bronchial anastomosis in video-assisted thoracoscopic sleeve lobectomy: a report of 32 cases. *J Thorac Dis*. 2016;8:2233-40.
8. Zhou S, Pei G, Han Y, Yu D, Song X, Li Y, et al. Sleeve lobectomy by videoassisted thoracic surgery versus thoracotomy for non-small cell lung cancer. *J Cardiothorac Surg*. 2015;10:116.
9. Ng CS. Thoracoscopic sleeve resection—the better approach? *J Thorac Dis*. 2014;6:1164-6.
10. Diego Gonzalez-Rivas, Alejandro Garcia, Chang Chen, Yang Yang, Yuming Zhu, Gening Jiang. Technical aspects of uniportal video-assisted thoracoscopic sleeve resections: Where are the limits? *JTCVS Techniques* 2020;2:160-4.
11. Palade E, Holdt H, Passlick B. Bronchus anastomosis after sleeve resection for lung cancer: Does the suture technique have an impact on postoperative complication rate? *Interact Cardiovasc Thorac Surg* 2015;20:798-804. doi: 10.1093/icvts/ivv058.