



Treatment of concomitant SLAP lesion in patients aged 45 and above who underwent arthroscopic rotator cuff repair: Tenotomy versus labral repair?

Gokhan Ilyas^{a,*}, Ercument Egeli^b

^aUsak University, Faculty of Medicine, Department of Orthopaedics and Traumatology, Usak, Türkiye

^bEsmem State Hospital, Clinic of Orthopaedics and Traumatology, Usak, Türkiye

ARTICLE INFO

Keywords:

Rotator cuff injuries
SLAP tears
Shoulder injuries
Arthroscopic surgeries

Received: Jan 21, 2024

Accepted: Mar 13, 2024

Available Online: 25.03.2024

DOI:

[10.5455/annalsmedres.2024.01.020](https://doi.org/10.5455/annalsmedres.2024.01.020)

Abstract

Aim: The current study aimed to compare the clinical and functional outcomes of the long-head biceps tendon (LHBT) tenotomy or labrum repair for the biceps-labral complex in the presence of superior labrum anterior-posterior (SLAP) lesion accompanying Goutallier type 0-I-II rotator cuff injury in patients aged 45 and above who underwent arthroscopic repair.

Materials and Methods: A retrospective analysis was conducted on 1,148 patients who underwent arthroscopic shoulder surgery. A total of 223 patients, who underwent arthroscopic repair for Goutallier type 0, I, and II rotator cuff tears (RCT) and received simultaneous treatment for SLAP lesions through either LHBT tenotomy or labral repair, were included in the study. Patients were divided into two groups according to the treatment of SLAP lesions such as tenotomy (n=78) and repair (n=145). Demographic data, pre-operative, post-operative 3-month, and 12-month range of motion, visual analog scale (VAS), and Constant Murley Scale (CMS) were compared.

Results: Flexion and external rotation were significantly higher in the tenotomy group, and internal rotation in the repair group ($p < 0.001$, < 0.001 , 0.005 , respectively). Although the VAS score was significantly lower in the tenotomy group compared to the repair group in the 3rd-month postoperative control ($p < 0.001$), the difference between the two groups disappeared in the 12th-month control ($p = 0.081$). The CMS score was low in the tenotomy group preoperatively ($p = 0.015$), by the 12-month follow-up, although there was a severe increase in both groups, there was no statistically significant difference between them ($p = 0.071$).

Conclusion: The study determined that both LHBT tenotomy and labral repair treatments for SLAP lesions, performed in conjunction with arthroscopic rotator cuff repair, are successful methods in terms of function, pain, and range of motion changes. It was observed that flexion and external rotation outcomes were better in tenotomy patients, while internal rotation was more favorable in patients undergoing labral repair.



Copyright © 2024 The author(s) - Available online at www.annalsmedres.org. This is an Open Access article distributed under the terms of Creative Commons Attribution-NonCommercial-NoDerivatives 4.0 International License.

Introduction

Rotator cuff tears (RCT) are among the most reported shoulder pathologies, accounting for 20% of cases [1-2]. The rotator cuff is formed by the tendons of the subscapularis, supraspinatus, infraspinatus, and teres minor muscles, converging from the front to the back of the shoulder. RCT can occur in individuals of all age groups and, if left untreated, carries the potential for disability [3]. Although the prevalence of RCT ranges from 9.4% to 39%, it tends to increase with age [4-8].

Superior labrum anterior-posterior (SLAP) lesions are

noted to occur as a result of heavy lifting, falls onto an outstretched arm, and direct trauma. Overhead athletes are noted to be prone to SLAP lesions [9-10]. The lesion, initially defined by Andrews as a superior labral tear, was subsequently categorized into four different types with the introduction of Snyder's term "SLAP" lesion [9,11]. It has been noted that intra-articular lesions accompany full-thickness rotator cuff tears in 74% of cases, with labral tears being the most observed lesion [12]. In a separate study, it was shown that 60.5% of patients with fully repairable full-thickness RCT had associated intra-articular abnormalities [13]. In their study examining patients with superior labral lesions, Snyder et al. reported that 40% of them had accompanying RCT [14]. Normal shoulder

*Corresponding author:

Email address: gokhan.ilyas@usak.edu.tr (Gokhan Ilyas)

joint range of motion (ROM) is reported to be 180 degrees for flexion, 90 degrees for external rotation, and between 79-90 degrees for internal rotation [15].

In a prospective randomized study in 2008, Franceschi et al. argued that repairing a concomitant SLAP lesion is not necessary in addition to rotator cuff repair in 56 patients aged 50 and above [16]. In their study, they evaluated ROM and the University of California-Los Angeles (UCLA) scores both before and after the surgery. In the current study, in addition to ROM values, we conducted pain assessment using the Visual Analogue Scale (VAS) and functional evaluation using the Constant Murley Score (CMS). Increasing score on VAS indicates increased pain (max 10). The high score in CMS evaluation indicates increased functional capacity (max 100) [17,18]. The inclusion of a large patient population ensures an increased power of analysis. Additionally, patients with RCT were limited to Goutallier types 0, I, and II, aiming to eliminate additional negative effects that could impact the outcomes of rotator cuff insufficiency.

The current study aimed to compare the clinical and functional outcomes of the long-head biceps tendon (LHBT) tenotomy or labrum repair for the biceps-labral complex in the presence of superior labrum anterior-posterior (SLAP) lesion accompanying Goutallier type 0-I-II rotator cuff injury in patients aged 45 and above who underwent arthroscopic repair.

Materials and Methods

The current study was conducted by the principles of the Declaration of Helsinki. Between 2015 and 2023, a total of 1148 patients who underwent arthroscopic shoulder surgery by the lead author were retrospectively reviewed after obtaining approval from the local institutional review board (Usak University Faculty of Medicine, Clinical Research Ethics Committee [date: 11/01/24, decision number: 284-284-16]).

Patients aged 45 and above who underwent arthroscopic repair for Goutallier type 0, I, and II RCT and received simultaneous treatment for SLAP lesions through either biceps tenotomy or labral repair were included in the study. All patients under the age of 45 (n=231), those with Bankart lesions (n=63), bone Bankart lesions (n=14), those with missing parameters in the evaluation (n=71), individuals with a history of previous surgery on the same shoulder (n=15), adhesive capsulitis (n=12), inflammatory diseases (n=7), those with isolated SLAP or RCT (n=102), those without at least 1 year of postoperative follow-up (n=149), presence of Goutallier type III and IV RCT (n=151), patients with preoperative LHBT rupture (n=8), individuals who received treatment other than the one determined for SLAP lesion and RCT treatment (n=58), and patients who underwent a re-operation on the same shoulder for any reason or developed a re-tear in the rotator cuff (n=44) were determined as exclusion criteria for the study (Figure 1). In the presence of Goutallier type III and IV RCTs, they were excluded from the study due to the addition of factors that could negatively affect the treatment process.

Goutallier classification (Types 0-IV) has been utilized in the grading of RCT [19,20]. After applying the exclusion

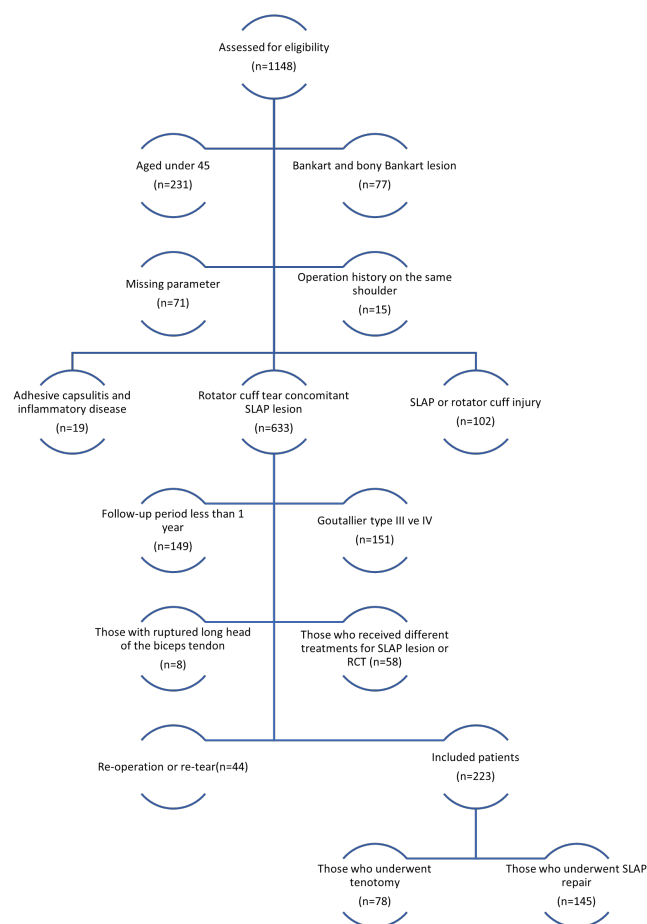


Figure 1. Flowchart

criteria, the patients included in the study (n=223) were divided into two separate groups such as those who underwent arthroscopic rotator cuff repair with LHBT tenotomy for SLAP lesions (n=78) and those who underwent arthroscopic rotator cuff repair with labral repair for SLAP lesions (n=145). With the help of statistical methods to be used in the study, it was calculated that there should be at least 51 patients in each group for the power level to be 0.80.

The data obtained from archival records and demographic information were evaluated, pre-operative-post-operative 3-month, and 1-year ROM measurements, VAS (0-10) and CMS (0-100) values were compared between the two groups separately at pre-operative, post-operative 3-month, and 1-year intervals.

Surgical technique

Before shoulder arthroscopy surgery, all patients underwent interscalene nerve block anesthesia for the affected extremity.

All operations were performed in the lateral decubitus position. The upper extremity is put into traction with 10 lbs. of weight. The arm is placed in 40° to 50° of abduction and approximately 15° of forward flexion.

Landmarks were determined by marking the coracoid process, the acromion's anterior, lateral, and posterior borders, and the clavicle. The posterior portal was estab-

lished from the inferior aspect of the posterolateral corner of the acromion, while the anterior portal was created from the lateral side of the coracoid process. The imaging was provided by entering the shoulder joint from the posterior portal with an arthroscope.

Based on imaging and examination, a decision was made to perform LHBT tenotomy or labrum repair in the presence of a SLAP lesion. The decision for LHBT tenotomy or labral repair was determined based on the presence of LHBT inflammation, subluxation, and partial rupture at the time of surgery (Figure 2, 3). If the decision for tenotomy was made, a T-shaped cut was made at the junction of the LHBT and the upper labrum. In the decision to re-

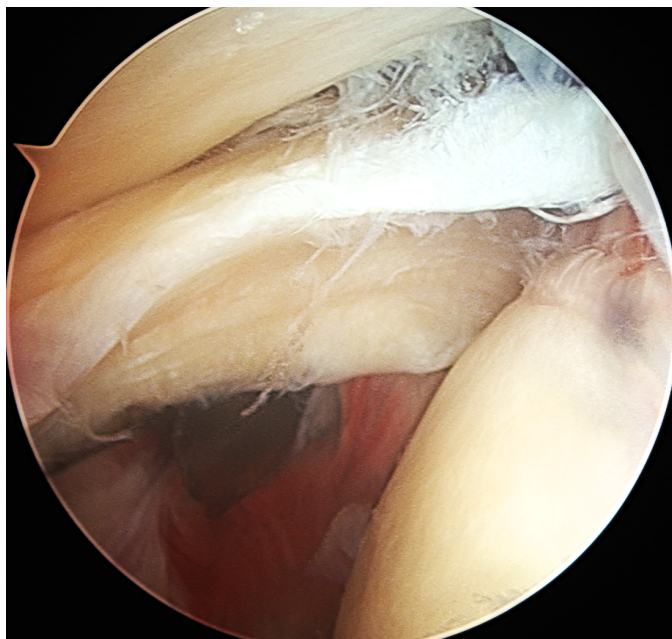


Figure 2. Appearance of partial rupture in the long head of the biceps tendon.

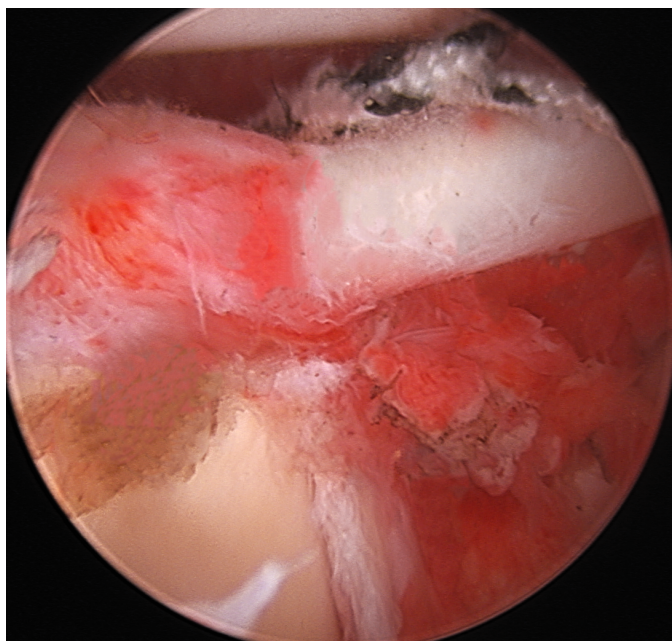


Figure 3. Type II SLAP lesion repair.

pair the labrum, after debridement, a 3.5 mm anchor was placed on the glenoid at 12 o'clock, the ropes of the anchor were passed through two separate areas, the superior labrum and the LHBT adhesion area, with the help of suture lasso, and the tissue was tightly adhered to the bone with the sliding knot technique. The remaining ropes were cut and removed.

Subacromial decompression was applied to all patients in the study concurrently with arthroscopic rotator cuff repair using the double-row technique.

Statistical analysis

SPSS (Statistical Package for the Social Sciences) version 24 (IBM Corp., Armonk, New York, USA) was used for the statistical analysis. Chi-square and Fisher exact tests were used for the evaluation of categorical data. A p-value below 0.05 was considered statistically significant. The decision to evaluate the data was made based on the normality analysis conducted using the Shapiro-Wilk test. A p-value below 0.05 was considered statistically significant. If the p-value was below 0.05, Mann-Whitney U analysis was used, assuming that there was a non-normal distribution. If it was above 0.05, the independent t-test was used, assuming that it was in normal distribution. A p-value less than 0.05 was considered significant. Post hoc analysis was performed using the G*power 3.1.9.7 program (Heinrich-Heine-Universität Düsseldorf, GERMANY).

Results

Of the patients included in the study, 137 (61%) were female, with a mean age of 53.52±8.2 years (45-79), while the mean age for males was 54.71±8.64 years (45-79) (p=0.246). When the tenotomy (n=78) and labral repair (n=145) groups were compared, no statistically significant difference was found between mean age, gender, and dominant extremity use (p=0.146, 0.085, 0.099, respectively). When the Goutallier grades between the two groups were examined, they were found to be statistically insignificant (p=0.165) (Table 1).

There was no statistically significant difference between the preoperative flexion, internal rotation, and external rotation values in the ROM evaluation between the groups

Table 1. Demographic data.

	Tenotomy	Repair	p-value	Total
Age median (IQR)	53 (12)	53 (10)	.146*	53 (11)
[95% CI]	[53.07-57.16]	[52.06-54.67]		[52.87-55.08]
Sex	54/24	83/62	.085**	137/86
Female/Male (n)				
Dominant arm/ non-dominant arm (n)	48/30	105/40	.099**	153/70
Goutallier type	4/32/42	11/75/59	.165***	15/107/101
0/I/II				
N	78	145		223

IQR: interquartile range, CI: confidence interval, *: Mann-Whitney U, **: Fisher-exact, ***: Chi-square.

Table 2. Comparison of range of motion (ROM).

	Tenotomy	Repair	p-value*
Before the operation			
median (IQR) [95% CI]			
F	95 (37.5) [92.1-106]	100 (30) [101-108.7]	.239
IR	60 (15) [54.4-58.9]	60 (10) [58.1-60.7]	.08
ER	40 (15) [35.9-40.5]	35 (20) [34.3-38]	.138
3-months			
median (IQR) [95% CI]			
F	130 (26.25) [128.1-136.2]	120 (35) [121.6-127.3]	.001
IR	65 (10) [62.8-66.3]	70 (10) [65.5-67.6]	.089
ER	65 (15) [60.9-62.6]	55 (15) [56.4-59.1]	<.001
12-months			
median (IQR) [95% CI]			
F	175 (21) [165.1-170.5]	160 (13) [162.5-161]	<.001
IR	75 (7) [73.7-76]	77 (5) [76.4-78.1]	.005
ER	84 (12) [79.6-82.8]	75 (9) [74.2-76.3]	<.001

IQR: interquartile range, CI: confidence interval, F: flexion, IR: internal rotation, ER: external rotation, *: Mann-Whitney U.

Table 3. Comparison of pain with the Visual Analogue Scale (VAS).

	Tenotomy	Repair	p-value*
Before the operation			
median (IQR) [95% CI]	6.5 (3) [5.8-6.6]	5 (3) [5.3-5.9]	.026
3-months			
median (IQR) [95% CI]	4 (2) [3.6-4.1]	5 (2) [5-5.5]	<.001
12-months			
median (IQR) [95% CI]	2 (1) [1.2-1.7]	2 (1) [1.5-1.8]	.081

IQR: interquartile range, CI: confidence interval, F: flexion, IR: internal rotation, ER: external rotation, *: Mann-Whitney U.

Table 4. Comparison of functional status with Constant Murley Scale (CMS).

	Tenotomy	Repair	p-value*
Before the operation			
median (IQR) [95% CI]	58 (6) [57-59.4]	61 (5) [58.8-60.6]	.015*
3-months			
median (IQR) [95% CI]	73.5 (13) [73.4-76.5]	69 (15) [68.8-71.5]	<.001*
12-months			
mean±SD (min-max)	83.77±3.63 (75-90)	84.69±3.5 (75-90)	.071**

SD: standard deviation, IQR: interquartile range, CI: confidence interval, *: Mann-Whitney U, **: Independent T-test

(p=0.239, 0.08, 0.138, respectively). It was determined that flexion and external rotation values were statistically significantly higher in the tenotomy group at the 3 months after operation (p=0.001, <0.001, respectively), while internal rotation did not create a significant difference between the two groups (p=0.089). At the last follow-up at 1 year, it was determined that flexion and external rotation were statistically significantly higher in the tenotomy

group (both p<0.001), while internal rotation was higher in the labral repair group (p=0.005). While there was no statistically significant difference between the two groups in the pre-operative ROM, at the final follow-up, it was found that flexion and external rotation were significantly higher in the tenotomy group, and internal rotation was significantly higher in the repair group (Table 2). When pre-operative and final follow-up values were compared, in the tenotomy group, there was a 69% increase in flexion, a 32% increase in internal rotation, and a 113% increase in external rotation. In the repair group, there was a 55% increase in flexion, a 30% increase in internal rotation, and a 108% increase in external rotation (all p<0.001).

When comparing the VAS scores between the two groups, it was determined that it was higher in the tenotomy group before the operation (p=0.026), was lower in the 3rd month (p<0.001), and there was no difference between them in the 1st year (p=0.071), which was the last control. The pain score, which was initially high in the tenotomy group, significantly decreased within the same group at 3 months, but no significant decrease was observed in the repair group (Table 3). When preoperative and final follow-up values were compared, a 77% reduction in pain was observed in the tenotomy group, and a 70% reduction in pain was observed in the repair group (both p<0.001).

When evaluated with the Constant Murley Score in functional evaluation, it was higher in the labral repair group before the operation (p=0.015), although it increased at the 3rd-month control, it was found to be statistically significantly lower compared to the tenotomy group (p<0.001). The functional score, which was initially lower in the tenotomy group, increased more at 3 months compared to the other group, but at the 12-month follow-up, despite a severe increase in both groups, no statistical difference was observed (p=0.071) (Table 4). When preoperative and final follow-up values were compared, there was a 44% increase in function in the tenotomy group and a 42% increase in the repair group (both p<0.001).

In our retrospective study, power (1-b) in post hoc analysis was calculated as 0.966 (sample size [n1=78 - n2=145], effect size d=0.5, and an error probability=0.05).

Discussion

In the current study, it was observed that successful results were obtained in both LHBT tenotomy and labrum repair methods applied in the treatment selection of SLAP lesions in the ROM, VAS, and CMS values examined in the case of concomitant RCT and SLAP lesions. During the preoperative ROM measurements, there was no statistically significant difference between the two groups (flexion, internal rotation, and external rotation respectively, p=0.239, 0.08, 0.138). However, in the final follow-up, flexion and external rotation were significantly higher in the tenotomy group (both p<0.001), while internal rotation was found to be significantly higher in the repair group (p=0.005). Although there were severe improvements in VAS and CMS compared to the pre-operative values, at the last follow-up, there was no statistically significant difference between the groups (p = 0.081, .071, respectively).

Franceschi and colleagues [16] compared LHBT tenotomy and labral repair procedures for SLAP lesions in the pres-

ence of RCT and SLAP lesions in their study comprising 56 patients aged 50 and above. In their study where the degree of RCT was not specified, the evaluation included ROM and the UCLA score. They demonstrated a significant increase in the UCLA score, rising from 10.1 to 32.1 in the tenotomy group (n=27) and from 10.4 to 27.9 in the repair group (n=29) ($p<0.001$). In the current study, instead of the UCLA score, the CMS values used increased from 58.2 to 83.8 in the tenotomy group (n=78) and from 59.7 to 84.7 in the repair group (n=145) ($p<0.001$). In Franceschi et al.'s study [16], significant increases were observed in the ROM values for flexion, external rotation, and internal rotation compared to preoperative values (all $p<0.001$). In the current study, significant increases in all ROM values compared to preoperative values were observed (all $p<0.001$). However, unlike the study by Franceschi et al. [16], internal rotation values were measured higher in the labral repair group compared to the tenotomy group ($p<0.001$).

Kim et al. [21] examined 36 patients with concomitant RCT extending from large (less than 3 cm) to massive and SLAP lesions who were 60 years and older. They divided the patients into two groups based on the SLAP treatment, with LHBT tenotomy performed in 16 patients and labral repair in 20 patients. While there was no statistical difference in the UCLA score before the operation ($p=0.744$), they found an increase in both groups at the final follow-up. However, the tenotomy group had a higher increase compared to the repair group ($p=0.007$). In the current study, in which large and massive tears were excluded from the evaluation and the average age was 54, it was determined that although the CMS score was statistically significantly higher in the labrum repair group preoperatively ($p = 0.015$), the statistical difference between both groups disappeared at the last follow-up ($p = 0.071$). The reason for the disappearance of the difference at the final follow-up could be the significant difference observed preoperatively.

Abbot et al. [22] conducted a study with 38 patients where they applied debridement and labral repair for SLAP lesion treatment in conjunction with rotator cuff repair, comparing UCLA scores and ROM. They showed that the UCLA score increased from 17.4 to 34 in the debridement group (n=20) and from 17.9 to 31 in the repair group (n=18) ($p<0.001$). In their study where pre-operative ROM values were not provided, they found that in the final assessments, the internal and external rotation values were higher in the debridement group compared to the repair group (both $p<0.001$), while there was no statistically significant difference in the flexion ($p=0.08$). In the current study, where LHBT tenotomy (n=78) was applied instead of debridement for the treatment of SLAP lesions, it was found that the internal rotation value was higher in the repair group (n=145) ($p=0.005$), while the flexion value was higher in the tenotomy group ($p<0.001$). The inability to predict the healing of the labrum when debridement is applied for Type II SLAP lesions may be the reason for these differences.

Lim et al. [23] conducted a series of 35 patients aged 45 and older, in which they compared LHBT tenodesis (n=18) and labral repair (n=17) using ROM, VAS, and

CMS in the simultaneous treatment of rotator cuff repair and SLAP lesion. They observed that; the VAS score decreased from 4.6 to 1.7 in the tenodesis group and from 5.4 to 1.6 in the repair group (both $p<0.001$). The CMS values increased from 61 to 80 in the tenodesis group and from 64 to 83 in the repair group (both $p<0.001$), and ROM measurements increased compared to preoperative values ($p<0.001-0.049$). In their final assessments, they did not find any statistical differences between groups in terms of flexion, external rotation, and internal rotation values ($p=0.546, .961, .443$, respectively). In this study, in which tenodesis was applied instead of the tenotomy method, although there was similarity with the current study in terms of VAS and CMS values, the flexion, internal rotation, and external rotation at the final follow-up results in different values in our study ($p<0.001, .005, <.001$, respectively).

Our current study has some limitations. The retrospective nature of the study is inherently limiting. The lack of additional criteria in functional assessment can also be considered a limitation. The fact that all cases were performed by a single surgeon and the high number of cases are strengths of the study.

Conclusion

In our study investigating the difference between LHBT tenotomy and labral repair in conjunction with arthroscopic rotator cuff repair for concomitant rotator cuff injury and SLAP lesion, we found that functional, pain, and range of motion values significantly improved with both treatment methods compared to preoperative levels. However, flexion and external rotation outcomes were better in the tenotomy group, while internal rotation outcomes were better in the labral repair group.

Acknowledgements

We would like to thank Prof Onder KALENDERER for his unwavering support.

Ethical approval

Ethical approval was received from Uşak University Faculty of Medicine Clinical Research Ethics Committee (date: 11/01/24, decision no: 284-284-16).

References

1. Urwin M, Symmons D, Allison T, et al. the burden of musculoskeletal disorders in the community: the comparative prevalence of symptoms at different anatomical sites, and the relation to social deprivation. *Ann Rheum Dis.* 1998 Nov;57(11):649-55.
2. Yamamoto A, Takagishi K, Osawa T, et al. Prevalence and risk factors of a rotator cuff tear in the general population. *J Shoulder Elbow Surg.* 2010;19(1):116-120.
3. Lazarides AL, Alentorn-Geli E, Choi JH, et al. Rotator cuff tears in young patients: a different disease than rotator cuff tears in elderly patients. *J Shoulder Elbow Surg.* 2015 Nov;24(11):1834-43.
4. Yamaguchi K, Tetro AM, Blam O, et al. Natural history of asymptomatic rotator cuff tears: a longitudinal analysis of asymptomatic tears detected sonographically. *J Shoulder Elbow Surg.* 2001 May-Jun;10(3):199-203.
5. Neumann CH, Holt RG, Steinbach LS, et al. MR imaging of the shoulder: appearance of the supraspinatus tendon in asymptomatic volunteers. *AJR Am J Roentgenol.* 1992 Jun;158(6):1281-7.

6. Tibone JE, Elrod B, Jobe FW, et al. Surgical treatment of tears of the rotator cuff in athletes. *J Bone Joint Surg Am.* 1986 Jul;68(6):887-91.
7. Fukuda H, Hamada K, Yamanaka K. Pathology and pathogenesis of bursal-side rotator cuff tears viewed from en bloc histologic sections. *Clin Orthop Relat Res.* 1990 May;(254):75-80.
8. Fukuda H, Mikasa M, Yamanaka K. Incomplete thickness rotator cuff tears diagnosed by subacromial bursography. *Clin Orthop Relat Res.* 1987 Oct;(223):51-8.
9. Snyder SJ, Karzel RP, Del Pizzo W, et al. SLAP lesions of the shoulder. *Arthroscopy.* 1990;6(4):274-279.
10. Frantz TL, Shacklett AG, Martin AS, et al. Biceps Tenodesis for Superior Labrum Anterior-Posterior Tear in the Overhead Athlete: A Systematic Review. *Am J Sports Med.* 2021;49(2):522-528.
11. Andrews JR, Carson WG Jr, McLeod WD. Glenoid labrum tears related to the long head of the biceps. *Am J Sports Med.* 1985;13:337-341.
12. Miller C, Savoie FH. Glenohumeral abnormalities associated with full-thickness tears of the rotator cuff. *Orthop Rev.* 1994;23(2):159-162.
13. Gartsman GM, Taverna E. The incidence of glenohumeral joint abnormalities associated with full-thickness, reparable rotator cuff tears. *Arthroscopy.* 1997;13(4):450-455.
14. Snyder SJ, Banas MP, Karzel RP. An analysis of 140 injuries to the superior glenoid labrum. *J Shoulder Elbow Surg.* 1995;4(4):243-248.
15. Chang LR, Anand P, Varacallo M. Anatomy, Shoulder and Upper Limb, Glenohumeral Joint. In: *StatPearls.* Treasure Island (FL): StatPearls Publishing; August 8, 2023.
16. Franceschi F, Longo UG, Ruzzini L, et al. No advantages in repairing a type II superior labrum anterior and posterior (SLAP) lesion when associated with rotator cuff repair in patients over age 50: a randomized controlled trial. *Am J Sports Med.* 2008;36(2):247-253.
17. Constant CR, Gerber C, Emery RJ, et al. A review of the Constant score: modifications and guidelines for its use. *J Shoulder Elbow Surg.* 2008, 17:355-61. 10.1016/j.jse.2007.06.022.
18. Çelik D: Turkish version of the modified Constant-Murley score and standardized test protocol: reliability and validity. *Acta Orthop Traumatol.* 2016;69-75. 10.3944/AOTT.2016.14.0354.
19. Goutallier D, Postel JM, Bernageau J, et al. Fatty muscle degeneration in cuff ruptures: pre- and postoperative evaluation by CT scan. *Clin Orthop Relat Res.* 1994;304:78-83.
20. Fuchs B, Weishaupt D, Zanetti M, et al. Fatty degeneration of the muscles of the rotator cuff: assessment by computed tomography versus magnetic resonance imaging. *J Shoulder Elbow Surg.* 1999;8(6):599-605.
21. Kim SJ, Lee IS, Kim SH, et al. Arthroscopic repair of concomitant type II SLAP lesions in large to massive rotator cuff tears: comparison with biceps tenotomy. *Am J Sports Med.* 2012;40(12):2786-2793.
22. Abbot AE, Li X, Busconi BD. Arthroscopic treatment of concomitant superior labral anterior posterior (SLAP) lesions and rotator cuff tears in patients over the age of 45 years. *Am J Sports Med.* 2009;37(7):1358-1362.
23. Lim S, Kim SK, Kim YS. Comparison between SLAP Repair and Biceps Tenodesis with Concomitant Rotator Cuff Repair in Patients Older than 45 Years: Minimum 2-Year Clinical and Imaging Outcomes. *Clin Orthop Surg.* 2020;12(3):364-370.