



Ann Med Res

Current issue list available at [AnnMedRes](http://AnnMedRes)

Annals of Medical Research

journal page: [www.annalsmedres.org](http://www.annalsmedres.org)

# Can lacrimal gland reposition surgery performed during upper lid blepharoplasty lead to dry eye disease?

Demet Yolcu

University of Health Sciences, Abdurrahman Yurtaslan Oncology Training and Research Hospital, Department of Ophthalmology, Ankara, Türkiye

## ARTICLE INFO

### Keywords:

Lacrimal gland prolapse  
Reposition surgery  
Ocular surface disease  
OSDI  
Upper lid blepharoplasty

Received: Nov 23, 2023

Accepted: Feb 21, 2024

Available Online: 27.02.2024

DOI:

[10.5455/annalsmedres.2023.11.314](https://doi.org/10.5455/annalsmedres.2023.11.314)

## Abstract

**Aim:** The aim of the present paper was to investigate the impact of lacrimal gland reposition procedure on ocular surface parameters, and the paper seeks to fill a gap about a subject that has not been studied in detail before.

**Materials and Methods:** The medical records of patients who underwent upper eyelid blepharoplasty surgery along with lacrimal gland repositioning procedure (Group 1) and patients who underwent only upper eyelid blepharoplasty (Group 2) between October 2021 and March 2023 were retrospectively analyzed. Postoperative final visit tear break-up time (TBUT), tear meniscus height (TMH), Schirmer's test and ocular surface disease index (OSDI) questionnaire was compared with preoperative values separately in each group. Additionally, these tests were compared between the two groups.

**Results:** The postoperative OSDI score was significantly higher ( $p: 0.04$ ), and the postoperative TMH was significantly lower ( $p: 0.03$ ) in lacrimal gland surgery group when compared with standard blepharoplasty group. Additionally, in lacrimal gland surgery group, the postoperative TMH was significantly lower and OSDI scores were significantly higher when compared with the preoperative values ( $p: 0.03$  for TMH and  $p: 0.03$  for OSDI score).

**Conclusion:** Reposition of a prolapsed lacrimal gland can result with ocular surface disease. In those cases, the physicians should be aware of this potential complication before surgery planning and take appropriate measures to minimize the risks.



Copyright © 2024 The author(s) - Available online at [www.annalsmedres.org](http://www.annalsmedres.org). This is an Open Access article distributed under the terms of Creative Commons Attribution-NonCommercial-NoDerivatives 4.0 International License.

## Introduction

Blepharoplasty procedure can be done for both cosmetic and functional purposes. Numerous types of procedures can be done during the upper lid blepharoplasty to achieve more aesthetically and functionally satisfied results, and reposition of a prolapsed lacrimal gland is one of the most used procedures [1, 5]. Lacrimal gland composed of two portions (palpebral and orbital portions) and the ductus of both portions drains into the upper-temporal portion of the conjunctival fornix which is located at the 5 mm superior to the lateral tarsal border [6, 7]. Lacrimal gland prolapsus has been reported approximately 10-60% of the patients who underwent upper lid blepharoplasty. Lacrimal gland prolapsus can be observed as a fullness or swelling of the superolateral portion of the upper eyelid. The etiopathology of the prolapsus can be explained by the enlargement of the gland due to the systemic conditions (such as inflammation, infiltration or infections) and

by the laxity of the attachments which normally hold the gland in the original location. Lacrimal gland prolapsus can be seen preoperatively during the examination of the upper eyelids or during the upper lid blepharoplasty procedure. The isolation of the prolapsed lacrimal gland from the surrounding fat pads, refixation of the prolapsed part of the gland into the original location and gentle cauterization of the prolapsed part of the gland are the mainly used correction procedures [1].

The lacrimal gland produces aqueous component of the tear film and during the lacrimal gland reposition procedures the gland can be potentially damaged and can lead to decreased tear production and dry eye disease [8-12]. Hence, the aim of the present paper was to investigate the impact of lacrimal gland reposition procedure on ocular surface parameters, and the paper seeks to fill a gap about a subject that has not been studied in detail before.

## Materials and Methods

Medical records of the patients who underwent lacrimal gland reposition procedure concomitant with upper lid ble-

\*Corresponding author:

Email address: [drylcdemet@hotmail.com](mailto:drylcdemet@hotmail.com) (Demet Yolcu)

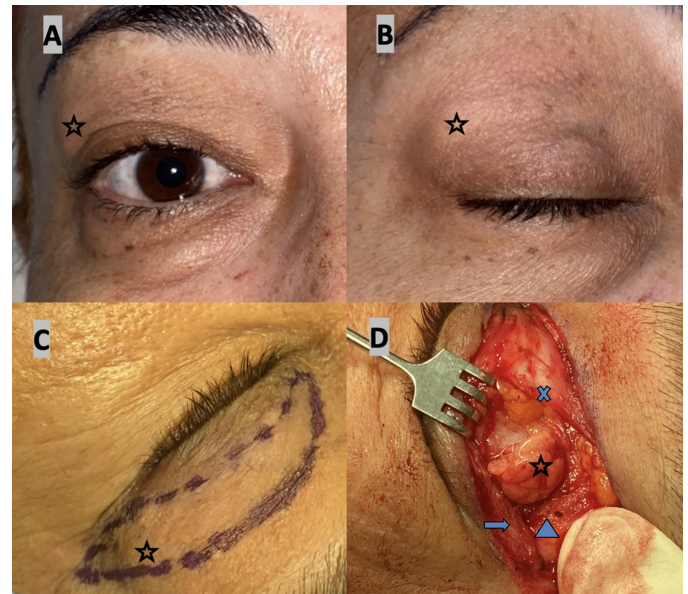
pharoplasty (Group 1), and patients who underwent standard upper lid blepharoplasty (Group 2) at the University of Health and Sciences Dr. Abdurrahman Yutaslan Oncology Training and Research Hospital, Department of Ophthalmology, between October 2021 and March 2023 were evaluated, retrospectively. All patients signed written consent for surgeries and publication of the study results. Study protocol was conducted in accordance with the ethical principles of Declaration of Helsinki Institutional Review Board, and approved by Dr Abdurrahman Yurtaslan Oncology Training and Research Hospital, Non-Invasive Clinical Research Ethics Committee (dated 05/10/2023 and numbered 2023-09/76). From the medical records; age, sex, follow-up period and ocular examination findings were retrieved. Patients who underwent preoperative and postoperative (at least 3 months) Schirmer's test, tear break up time (TBUT) test, anterior segment photographs to measure the tear meniscus height (TMH) and obtained by using the autorefractometer (Canon, RK-F1, USA) and ocular surface disease index (OSDI) questionnaire prior to the surgery and during the follow-up period were included to the study. The exclusion criteria were; other eyelid and ocular pathologies, systemic illness or drug usage which could interfere the ocular surface parameters, 3 months of follow-up time, 4mm lacrimal gland prolapse or lacrimal gland disease that require identification through biopsy. Postoperative final test results were used for the comparisons in each group, and comparison among the two groups, and preoperative and postoperative values were performed.

#### *Surgical method*

All surgeries were performed under local anesthesia. The eyelid skin crease was demarcated by using a surgical pen and the amount of the excess skin was demarcated. The skin was infiltrated with 3 ml of 1% lidocaine with epinephrine and the skin was incised with a scalpel blade. Standard blepharoplasty with excess skin removal and closure of the skin edges with 6-0 polypropylene suture was performed. If the lacrimal gland prolapse was observed, following the excision of the excess skin, the septum and orbicular muscle was opened temporally; the prolapsed lacrimal gland was found and separated from the surrounding tissues (Figure 1). The degree of the lacrimal gland prolapse was documented by placing a millimeter ruler at the orbital rim. The tip of the gland was sutured to the arcus marginals just anterior to the lacrimal fossa with a 5-0 double armed polypropylene suture to form a truss suture. In some cases, the lacrimal gland capsule was contracted by using cautery to achieve a good eyelid contour. At the end of the operation septum and orbicularis were repaired and skin edges were closed with a 6/0 polypropylene suture. Suture removal was performed at postoperative 7-10 days.

#### *Ocular examination*

**Assessment of ocular symptoms:** The Ocular Surface Disease Index (OSDI) questionnaire was used to assess the ocular symptoms (Table 1) [13-17]. The OSDI questionnaires consisted of 12 questions and evaluate the symptoms that patients might have experienced over the past week.



**Figure 1.** A: The appearance of the prolapsed lacrimal gland in the upper temporal region of the upper eyelid was marked with a star. B: The same subject with closed eyes and the appearance of the prolapsed lacrimal gland in the upper temporal region of the upper eyelid was marked with a star. C: The appearance of another case diagnosed with lacrimal gland prolapsus. Excess skin was marked with surgical pen, and, prolapsed lacrimal gland in the upper temporal region of the upper eyelid was marked with a star. D: The appearance of the prolapsed lacrimal gland (marked with a star) following the orbicularis muscle and orbital septum were opened and the septum was fully divided temporally until the presence of a lacrimal gland was identified (the orbital septum is marked with a multiplication sign and the orbicularis muscle is marked with a triangle and the orbital rim is marked with an arrow).

According to the questionnaire; subjects had a score from 0 to 100, with higher scores representing more severe symptoms. According to the OSDI scores, subjects divided into four groups as follows; 0-12 was normal, 13-22 was mild, 23-32 was moderate, 33 was severe.

**Schirmer's test:** A filter paper was placed in the lower eyelid fornix and Schirmer's test without anesthesia was performed. After 5 minutes, the length of the moistened portion of the strip was measured with the eyes closed. Wetting length of the filter paper was recorded in millimeters. More than 10 mm of moisture on the filter paper in 5 minutes was normal.

**Tear break-up time (TBUT) test:** One droplet of the 1% sterile fluorescein dye was applied into the conjunctival sac, and patients blinked their eyes several times to mix the fluorescein dye, and then asked not to close the eyes, and the time was recorded from staining of the cornea to the first stainless ocular surface area visualization under the slit lamp biomicroscope with blue cobalt filter light illumination. According to the results, a TBUT below the

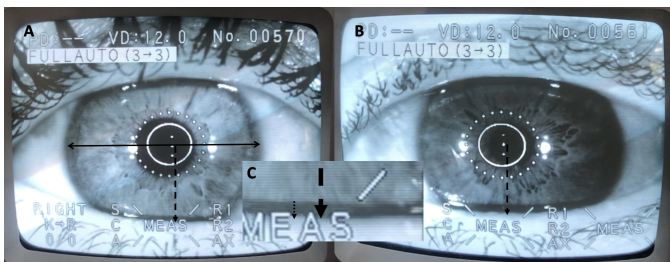
**Table 1.** Ocular surface disease index symptom evaluation form.

Please, read and answer the questions below, fill the box which matches mire likely with your symptoms.						
		ALL of the time	MOST of the time	HALF of the time	SOME of the time	NONE of the time
Did you experience the conditions below during the last week?						
1	Sensitivity to the lights?	4	3	2	1	0
2	Irritation on in the eyes?	4	3	2	1	0
3	Pain in the eyes?	4	3	2	1	0
4	Not to see clearly?	4	3	2	11	0
5	Decreased vision?	4	3	2	1	0
Did you experienced difficulty when doing the things stated below because of your eyes during the last week?						
6	To read a book?	4	3	2	1	0
7	To drive a car at night?	4	3	2	1	0
8	To work with PC or bank machine?	4	3	2	1	0
9	To watch a TV?	4	3	2	1	0
Did you experienced discomfort at the conditions stated below because of your eyes during the last week?						
10	At the places which are windy?	4	3	2	1	0
11	At the places which are very dry?	4	3	2	1	0
12	At the places that are air conditioned?	4	3	2	1	0

Calculation of OSDI: OSDI - sum of severity for all questions answered 4 (total number of questionnaires answered).

10 sec was considered as abnormal.

**Tear meniscus height (TMH) test:** The TMH was evaluated by using the anterior segment photographs of the autorefractometer. The calculation of the TMH was made by using the ImageJ software (<http://rsbweb.nih.gov/ij/>), and the ratio of the tear meniscus height (at the midpoint of the lower eyelid) and wide-to-wide horizontal corneal diameter was multiplied with 12 to standardize the measurements (Figure 2) [18].



**Figure 2.** A, B: The appearances of the anterior segment photographs obtained by using the autorefractometer device. Two headed arrow represents the wide-to-wide (WTW) horizontal corneal diameter, and the dotted arrow represents the point where tear meniscus height (TMH) was measured. C: a big image was taken to make measurements, and the little dotted arrow represents the TMH. To calculate the exact TMH; the ratio of the TMH and WTW was multiplied with 12.

#### Statistical analysis

SPSS 22.0 software (IBM) was used for data analyses. Continuous variables were expressed as mean SD. Categorical variables were expressed as frequencies and percent-

ages. The normality of the variables was verified by using the Kolmogrov-Smirnov tests. The Mann Whitney U test was used for comparison of non-normally distributed continuous variables between the two independent groups. Wilcoxon Signed Rank test was used for comparison of non-normally distributed two related samples of continuous variables in each group. A p value 0.05 was considered to be statistically significant.

#### Results

Of the 23 subjects (underwent bilateral lacrimal gland reposition procedure concomitant with upper lid blepharoplasty), 16 patients met the inclusion criteria and included to the group 1, and, of the 34 subjects (underwent standard upper lid blepharoplasty), 20 met the inclusion criteria and included to the group 2. There was no significant difference among the two groups in terms of age, gender and follow-up time (p: 0.12, p: 0.23, p: 0.54, respectively) (Table 2). The postoperative OSDI score was significantly higher (p: 0.04), and the postoperative TMH was significantly lower (p: 0.03) in lacrimal gland surgery group when compared with standard blepharoplasty group. Additionally, in lacrimal gland surgery group, the postoperative TMH was significantly lower and OSDI scores were significantly higher when compared with the preoperative values (p: 0.03 for TMH and p: 0.03 for OSDI score) (Table 2).

In lacrimal gland surgery group, the postoperative TBUT and Schirmer's tests were not significantly different when compared with preoperative values (p: 0.09, p: 0.13, respectively) (Table 2). Similarly, the postoperative TBUT and Schirmer's tests were not significantly different when compared with standard blepharoplasty group (p: 0.32, p: 0.11, respectively).



**Table 2.** The distribution of the demographics and objective and subjective ocular surface disease assessment tests among the groups.

	G1: Lacrimal gland surgery group (n: 16)	G2: Standard blepharoplasty group (n: 20)	p
Age (year)	56.4 7.3 (43-62)	61.7± 4.4 (39-67)	P:0.12*
Male/Female	3/13	4/16	p: 0.23*
Follow-up time (month)	8± 3.2 (3-12)	9± 4.2 (4-13)	P:0.54*
Pre O-Schirmer's T(mm)	16.3 ±7.1 (12-25)	15.6± 8.1 (10-25)	p: 0.13, 0.29 **
Post O-Schirmer's T (mm)	14.2 ±8.8 (9-25)	14.6± 8.18 (10-25)	P: 0.11*
Pre O-TBUT (min)	11.3 ±5.4 (8-15)	12.4± 6.2 (9-15)	p: 0.09, 0.23**
Post O-TBUT (min)	8.2± 2.1 (4-11)	9.2± 3.2 (8-16)	P: 0.32
Pre O-TMH (mm)	0.30± 0.09 (0.19-0.42)	0.29± 0.04 (0.15-0.4)	<b>p:0.03#, 0.32**</b>
Post O-TMH (mm)	0.20± 0.08 (0.09-0.31)	0.27± 0.1 (0.08-0.35)	<b>P: 0.03#</b>
Pre O-OSDI score	8.3± 4.2 (0-18)	7.7± 6.2 (3-16)	<b>P: 0.03#, 0.17**</b>
OSDI: 0-12	14	15	
OSDI: 13-22	3	5	
OSDI: 23-32	-	-	
OSDI 33	-	-	
Post O-OSDI score	14.3 6.1 (0-23)	9.3 4.1 (3-21)	<b>P: 0.04#</b>
OSDI: 0-12	10	14	
OSDI: 13-22	4	3	
OSDI: 23-32	2	3	
OSDI 33	-	-	

TBUT: Tear Break Up Time, TMH: Tear Meniscus Height, OSDI: Ocular surface disease index. Pre O: Preoperative, Post O: Postoperative. # Statistically significant difference p 0.05 \*Comparison of the two study groups. \*\* Comparison of the preoperative and postoperative values of the lacrimal gland and standard blepharoplasty groups, respectively.

## Discussion

According to the current study; in lacrimal gland surgery group, there was a significant difference in postoperative TMH when compared with the preoperative value and standard blepharoplasty group. In recent years, non-invasive BUT and TMH measurements are recommended because of the stimulant effect of the invasive tests [19]. Additionally, more than one objective ocular surface tests were recommended to achieve more reliable results [20, 21]. In the current study, sodium fluorescein (used in the TBUT test), and filter paper (used in the Schirmer's test) were the possible stimulants that could alter the exact measurements. In the current study, the TMH measurement was performed by using the anterior segment photographs of the autorefractometer (obtained without using slit lamp illumination that may create a stimulating effect), and the significant change in TMH may be due to non-invasive nature of the measurement method. The effectiveness of the using anterior segment photographs of the autorefractometer for measuring the margin reflex distance and angle kappa has been demonstrated by previous studies [18, 22].

Additionally, in the current study, the postoperative OSDI scores were significantly higher in lacrimal gland surgery group when compared with the standard blepharoplasty group. The OSDI scores could be due to the invasive nature of the lacrimal gland suspension procedure when compared with the standard blepharoplasty.

In the literature, the effect of the lacrimal gland repositioning procedure on ocular surface parameters have not been evaluated in a detailed fashion and studies on this topic is limited [17, 23- 25]. Guyuron et al. [26] exam-

ined the lacrimal gland suspension procedure and dry eye disease, and could not find a difference between the preoperative and postoperative Schirmer's test results. In the Guyuron's study, lacrimal gland suspension was performed concomitant with both upper and lower eyelid surgery (which could affect the lower eyelid tear pump function and could result with false Schirmer's test results), and it would not be correct to compare the results of the current study with the Guruyon's study.

In the literature, Massry et al. reported that, lacrimal gland reposition surgery is a safe procedure with a normal healing time and morbidity, however, he did not evaluate the ocular surface parameters [1]. Additionally, there are studies reported that, blepharoplasty induces the dry eye disease after the surgery. Hollander et al. conducted a randomized controlled trial, and didn't find significant differences in dry eye parameters during long-term follow-up (12 months), however, the patients reported that their dry eye complaints increased, and the authors stated that, blepharoplasty does not induce or worsen objective dry eye parameters, but may worsen subjective complaints of dry eyes [17]. Similarly, in the current study, despite there was no significant worsening in some objective dry eye tests, the OSDI questionnaire was significantly improved in lacrimal gland surgery group.

In the literature, there are studies discuss the tear deficiencies following total removal of the lacrimal gland. Stevenson et al. reported that, lacrimal gland excision procedure in mice resulted with tear-deficiency and dry eye disease [8]. Zhang et al. reported tear film abnormalities during the early stage after lacrimal gland tumor removal, and reduction of reflex lacrimal secretion [10]. Bhattacharya et

al. reported that, dry eye disease was observed one month after excision of the lacrimal gland in rabbits, and with time, significant improvement of dry eye was observed after excision [11]. Akaishi et al. reported two children who underwent accidental excision of the unilateral lacrimal gland tissue during the levator surgery, and parents of each child noticed that when the children cried, there were no tears in the affected eyes. In those studies, the lacrimal gland was removed completely instead of reposition and it is not possible to compare the results with the present study.

In the literature, it is well described that, dry eye symptoms are poorly correlated with dry eye objective tests. When considering the results reported in the literature, we can conclude that dry eye disease and diagnosis of the dry eye is a complicated issue [25, 27-31]. A combination of tests are commonly used to achieve more reliable diagnosis [25]. In the current study, in lacrimal gland surgery group, more than one objective ocular surface tests were performed and only one test (TMH) supported the dry eye disease. Additionally, the lacrimal gland surgery group showed higher postoperative dry eye symptoms when compared with preoperative values and standardized blepharoplasty group. Hence, it would be useful to evaluate the risk of dry eye development prior to the lacrimal gland reposition procedure for both patients and physicians.

There were numerous limitations in the current study such as; the retrospective nature of the study and small sample size. To achieve more reliable results, prospective and randomized studies with larger population, advanced evaluation methods and longer follow-up period is needed.

## Conclusion

In conclusion, lacrimal gland prolapse can be observed during cosmetic blepharoplasty surgeries and reposition of a prolapsed lacrimal gland can result with ocular surface disease. In those cases, the physicians should be aware of this potential complication before surgery planning and take appropriate measures to minimize the risks.

## Acknowledgments

None.

## Declaration of interest statement

The author has no conflicts of interest to declare.

## Ethical approval

This study approved by Dr Abdurrahman Yurtaslan Oncology Training and Research Hospital, Non-Invasive Clinical Research Ethics Committee (dated 05/10/2023 and numbered 2023-09/76).

## References

- Massry GG. Prevalence of lacrimal gland prolapse in the functional blepharoplasty population. *Ophthalmic Plast Reconstr Surg.* 2011;27:410-3.
- Friedhofer H, Orel M, Saito FL, et al. Lacrimal gland prolapse: management during aesthetic blepharoplasty: review of the literature and case reports. *Aesthetic Plast Surg.* 2009;33:647-53.
- Yang C, Guo X, Du L, et al. A Modified Procedure for Single-eyelid Asian Females with Lacrimal Gland Prolapse: Lacrimal Gland Reposition combined with Fat Transposition in Double-eyelid Operation. *Aesthetic Plast Surg.* 2021;45:1611-9.
- Beer GM, Kompatscher P. A new technique for the treatment of lacrimal gland prolapse in blepharoplasty. *Aesthetic Plast Surg.* 1994;18:65-9.
- Yuksel D, Yakin M, Kosker M, Simsek S. The treatment of lacrimal gland prolapse in blepharoplasty by repositioning the glands. *Semin Ophthalmol.* 2013;28:230-2.
- Conrady CD, Joos ZP, Patel BC. Review: The Lacrimal Gland and Its Role in Dry Eye. *J Ophthalmol.* 2016;2016:7542929.
- Singh S, Donthinani PR, Srivastav S, et al. Lacrimal and meibomian gland evaluation in dry eye disease: A mini-review. *Indian J Ophthalmol.* 2023;71:1090-8.
- Stevenson W, Chen Y, Lee SM, et al. Extraorbital lacrimal gland excision: a reproducible model of severe aqueous tear-deficient dry eye disease. *Cornea.* 2014;33:1336-41.
- Golan S, Vingopoulos F, Olson LC, et al. Lacrimal tissue resection in Fasanella Servat operation and the correlation to dry eye. *Orbit.* 2020;39:171-4.
- Zhang YQ, Qian J, Yuan YF, et al. [Tear film and lacrimal excretion changes after lacrimal gland tumor removal]. *Zhonghua Yan Ke Za Zhi.* 2013;49:27-31.
- Bhattacharya D, Ning Y, Zhao F, et al. Tear Production After Bilateral Main Lacrimal Gland Resection in Rabbits. *Invest Ophthalmol Vis Sci.* 2015;56:7774-83.
- Akaishi P, Galindo-Ferreiro A, Elkhamary SM, et al. Accidental lacrimal gland removal during resection of the levator palpebrae superioris muscle. *Arq Bras Oftalmol.* 2017;80:57-8.
- Perry HD, Donnenfeld ED. Dry eye diagnosis and management in 2004. *Curr Opin Ophthalmol.* 2004;15:299-304.
- Oh JR, Chang JH, Yoon JS, Jang SY. Change in quality of life of patients undergoing silicone stent intubation for nasolacrimal duct stenosis combined with dry eye syndrome. *Br J Ophthalmol.* 2015;99:1519-22.
- Kang TS, Cho J, Kim J, et al. Modified ocular surface disease index as a screening criteria for dry eye syndrome presenting after successful dacryocystorhinostomy. *PLoS One.* 2021;16:e0247168.
- Garcia-Alfaro P, Garcia S, Rodriguez I, Verges C. Dry eye disease symptoms and quality of life in perimenopausal and postmenopausal women. *Climacteric.* 2021;24:261-6.
- Yang J, Zhao W, Liao Y, et al. Ocular surface disease index questionnaire as a sensitive test for primary screening of chronic ocular graft-versus-host disease. *Ann Transl Med.* 2022;10:855.
- Yolcu D, Ozdogan S. a novel method to measure margin reflex distance using the autorefractometer. *Int ophthalmol.* 2022 Apr;42(4):1241-1247.
- Fernandez J, Vallejo M, Martinez J, et al. Agreement and repeatability of objective systems for assessment of the tear film. *Graefes' Archive for Clinical and Experimental Ophthalmology.* (2018) 256; 1535-1541.
- Niedernolte B, Trunk L, Wolffsohn J, et al. Evaluation of tear meniscus height using different clinical methods. *Clinical and Experimental Optometry.* 2021, Vol. 104, No. 5, 583-588.
- Wu Y, Wang C, Eang X, et al. Advances in Dry Eye Disease Examination Techniques. *Front. Med.* 2022; 8:826530.
- Yolcu D. Evaluation of angle kappa using the autorefractometer front monitor image. *Photodiagnosis Photodyn Ther.* 2023 Mar; 41:103296
- Rodrigues C, Carvalho F, Marques M. Upper Eyelid Blepharoplasty: Surgical Techniques and Results-Systematic Review and Meta-analysis. *Aesthetic Plast Surg.* 2023.
- Prischmann J, Sufyan A, Ting JY, et al. Dry eye symptoms and chemosis following blepharoplasty: a 10-year retrospective review of 892 cases in a single-surgeon series. *JAMA Facial Plast Surg.* 2013;15:39-46.
- Hollander MHJ, Pott JWR, Delli K, et al. Impact of upper blepharoplasty, with or without orbicularis oculi muscle removal, on tear film dynamics and dry eye symptoms: A randomized controlled trial. *Acta Ophthalmol.* 2022;100:564-71.
- Guyuron B, DeLuca L. Aesthetic and Functional Outcomes of Dacryoadenectomy. *Aesthetic surgery Quarterly-Summer 1996.* Volume 16, Number 2.138-141.
- Fatima A, Vadla P, Konda N. Changes in the tear film and meibomian gland morphology between preclinical dry eye and normal subjects represented by ocular surface disease index scores. *Exp Eye Res.* 2022;222:109188.
- Jones LT. The lacrimal secretory system and its treatment. *Am J Ophthalmol.* 1966;62:47-60.
- Obata H. Anatomy and histopathology of the human lacrimal gland. *Cornea.* 2006;25:S82-9.

30. Kashkouli MB, Tabrizi A, Ghazizadeh M, et al. Supine Test: A New Test for Detecting Lacrimal Gland Prolapse Before Upper Blepharoplasty. *Ophthalmic Plast Reconstr Surg*. 2019;35:581-5.
31. Huang S, Juniat V, James C, et al. Histopathological Characteristics of Lacrimal Gland Prolapse. *Ophthalmic Plast Reconstr Surg*. 2023;39:389-93.