



# The relationship between cyst diameter and long-term results of PAIR treatment

Mustafa Yildirim<sup>a,\*</sup>, Hakan Artas<sup>a</sup>

<sup>a</sup>Fırat University, Faculty of Medicine, Department of Radiology, Elazığ, Türkiye

## ARTICLE INFO

### Keywords:

Hydatid cyst

CE1

PAIR

Inactivation time

Received: Aug 21, 2023

Accepted: Dec 06, 2023

Available Online: 27.12.2023

DOI:

[10.5455/annalsmedres.2023.08.211](https://doi.org/10.5455/annalsmedres.2023.08.211)

## Abstract

**Aim:** The PAIR (Puncture, Aspiration, Injection of scolicedal agent, and Reaspiration) treatment is used for echinococcosis type 1 (CE1) liver hydatid cysts. The aim of this study is to show the relationship between the cyst diameter and long-term results of PAIR.

**Materials and Methods:** Between 2016 and 2021, fifty patients with 54 liver CE1 hydatid cysts who underwent PAIR treatment were included in the study. Under general anesthesia, procedures were carried out. Technical success (completing the required steps in a procedure), clinical success (absence of recurrence or major complication upon follow-up), complications, cyst cavities' long-term alterations were evaluated. Inactivation times of cysts smaller than 6 cm and larger than 6 cm were compared.

**Results:** The long axis of the cysts was between 3 cm and 12 cm. Technical success rate was 100%. The average follow-up time was  $996 \pm 250$  days. The cysts showed a mean volume reduction of 70.1% on follow up. The treatment was effective in 48 patients and 52 hydatid cysts. The effectiveness of the long-term treatment was 96%. Cysts smaller than 6 cm had a significantly shorter inactivation time than cysts larger than 6 cm ( $p=0.01$ ). Recurrence (CE2) was detected in one patient (2 %). This patient was treated with the modified catheterization (MoCAT) technique. Major complication (abscess) was detected in one patient (2 %) and abscess was drained using the percutaneous seldinger technique. Intra-abdominal spread, anaphylaxis, or mortality did not develop in any patient. Post-procedural pain developed in 3 patients as a minor complication (6%).

**Conclusion:** Although the inactivation time is longer in cysts larger than 6 cm, PAIR technique used to treat liver CE 1 hydatid cysts are effective and secure.



Copyright © 2024 The author(s) - Available online at [www.annalsmedres.org](http://www.annalsmedres.org). This is an Open Access article distributed under the terms of Creative Commons Attribution-NonCommercial-NoDerivatives 4.0 International License.

## Introduction

Echinococcus Granulosus, which causes hepatic hydatid cysts, is a serious public health hazard for the general populace [1]. The disease is endemic in some Asian, Mediterranean, North and South African countries and Australia. The parasite most frequently affects the liver [2]. Patients has non-specific symptoms generally and hepatic hydatid cysts are detected incidentally. Rarely, cyst rupture to the biliary tract and peritoneum may occur and cause severe complications such as anaphylaxis. Even if viable cysts are asymptomatic, they should be treated because of possible life-threatening complications [3].

According to the World Health Organization, cystic echinococcosis cysts are classified as active (CE 1, CE 2), transitional (CE 3a and CE 3b), and inactive (CE 4, CE 5) types by ultrasound image [4]. Treatment is advised for

hepatic hydatid cysts CE1, CE2, and CE3 [5]. Surgery is the traditional method of treating hepatic CE. But surgery may be related to high rates of morbidity, mortality. The therapeutic efficacy of albendazole is limited in this patient group [6]. Percutaneous treatment for these patients has been demonstrated in modern clinical practice to be quite effective and to have decreased morbidity and mortality [7].

For the percutaneous treatment of hydatid cysts, there are three main methods. The most commonly used method is PAIR (Puncture, Aspiration, Injection of scolicedal agent, and Reaspiration). The other technique is the catheterization technique and is used for CE1 and CE 3a cysts. The third method is the modified catheterization technique (MoCaT). MoCaT is used in percutaneous treatment of CE 2 and CE 3b hydatid cysts [8]. The cyst is punctured with one needle in PAIR technique. On the other hand, catheterization technique needs more needle and catheter manipulation. These techniques are widely used for treatment.

\*Corresponding author:

Email address: [Mustafa23468@outlook.com](mailto:Mustafa23468@outlook.com) (Mustafa Yildirim)

Cysts less than 5 cm in diameter are categorized as small CE. If the cyst diameter is between 5-10 cm, it is categorized as medium CE. Cysts larger than 10 cm are classified as giant CE [9]. Generally, the PAIR technique is especially used for the treatment of CE1 cysts less than 6 cm in diameter. Catheterization technique is used in larger cysts and presence of cysto-biliary fistula [10]. It is advised that hydatid cysts be classified according to the CE classification, with a 5-year follow-up period with the ultrasound following percutaneous treatment [11]. The goal of percutaneous treatment is to convert active and transitional hepatic hydatid cysts to inactive state [12].

The majority of available research has focused on the effectiveness of medicinal, surgery, and percutaneous treatment techniques. However, studies on the follow-up of cysts after percutaneous treatment and the factors affecting the inactivation period are limited. A study on the relationship between cyst diameter and inactivation time in PAIR treatment was not found in the literature. In this study, we aimed to evaluate the effectiveness of PAIR treatment, technical and clinical success rate, complications, and, relationship between the inactivation time and the cyst diameter for CE1 liver hydatid cysts. We also aimed to compare our PAIR treatment results with literature data.

## Materials and Methods

The local ethics committee approved this study (Fırat University Non-invasive Research Ethics Committee, Date: 25.05.2023, Protocol number: 2023/07-17). Informed consent was waived due to the retrospective nature of the study. Patients who underwent percutaneous treatment for hepatic hydatid cysts between 2016 and 2021 were examined. CE2 and CE3 cysts and patients who underwent the catheterization technique were not included in the study. Fifty patients (22 females) with 54 CE1 who underwent PAIR treatment were included in the study.

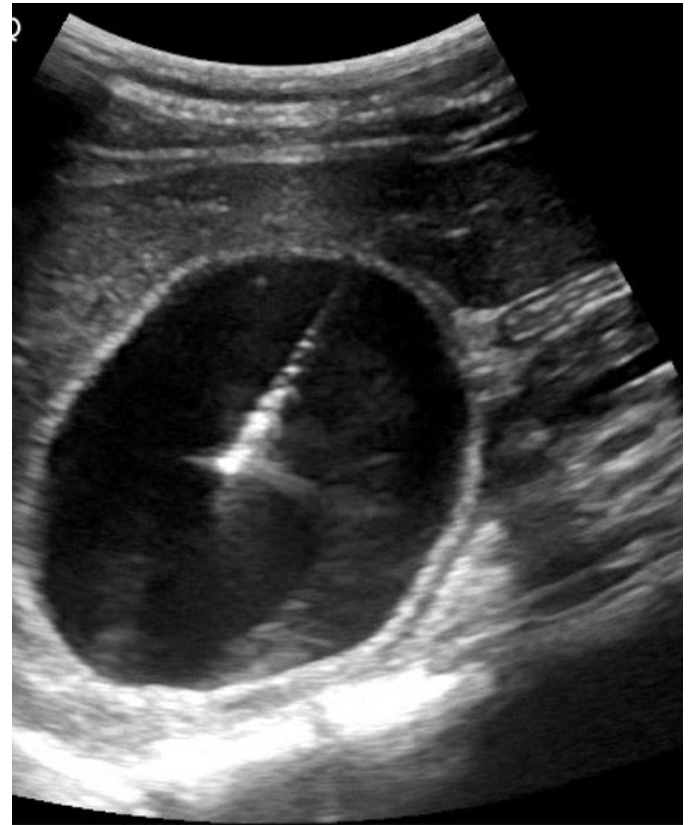
### Pre-procedural preparation

Ultrasonography was used to determine the hydatid cysts' initial diagnosis, and they were categorized according to ultrasound characteristics. Prophylactic albendazole was administered one week before the procedure orally at a dose of 10-15 mg/kg per day, and after the procedure, albendazole treatment was continued for four weeks [13]. Every procedure was carried out under general anesthesia due to potential severe allergic reaction risk.

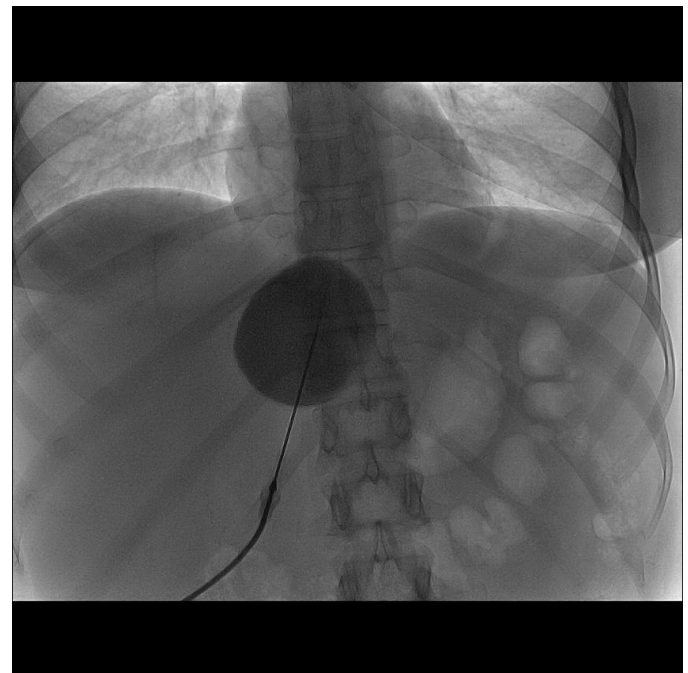
For general anesthetic preparation, patients were fasted for at least 8-10 hours before the procedure. The patients' coagulation parameters were examined before the procedure and coagulation disorders were corrected before the procedure. Under US and fluoroscopic guidance, all procedures were carried out by interventional radiologist.

### Technique

**PAIR:** Under sonographic guidance, an 18G Seldinger needle was used to puncture the cysts. About 20% of the cyst's estimated volume was aspirated. Under fluoroscopy, a contrast agent was injected via needle to detect any possible peritoneal or biliary connection. If cystography revealed there was no communication with the biliary tree,

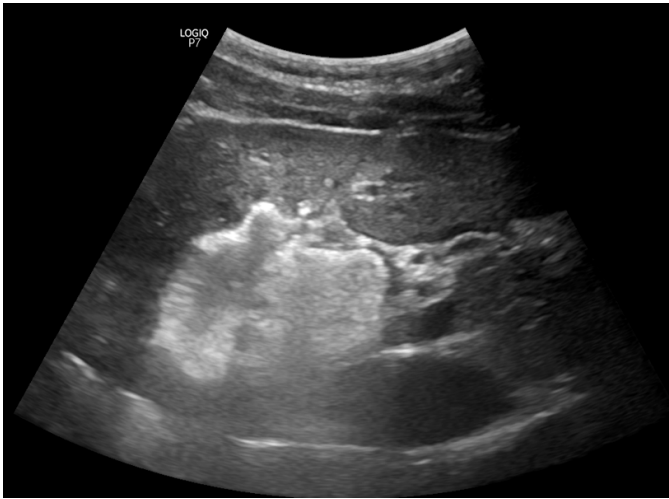

**Figure 1.** Puncture of cyst and aspiration of cyst content.

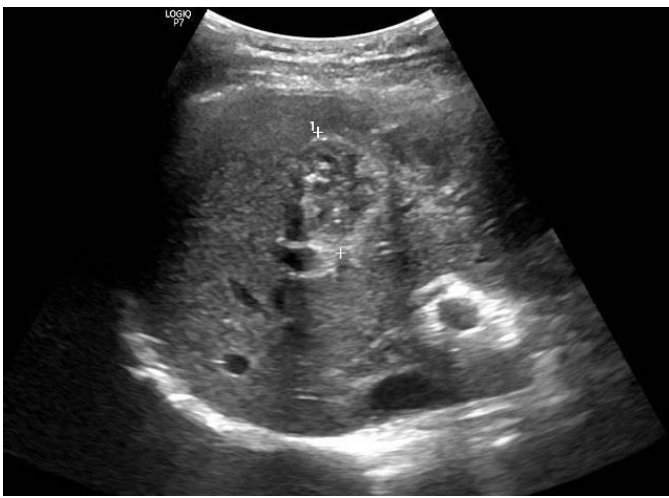

**Figure 2.** Cystography revealed there was no communication with the biliary tree.

the remaining cyst was aspirated while keeping the needle tip inside the cyst. Then, hypertonic saline (30% concentration) up to 30-35% of the initial cyst volume was injected. The cyst's contents were re-aspirated through the needle when the membrane separated from the pericyst, which generally occurs approximately 7-10 minutes after the injection. The needle was withdrawn after re-



**Figure 3.** Injection of hypertonic saline.



**Figure 4.** Cystic inactivation and pseudotumor appearance.

aspiration and PAIR was terminated (Figure 1, 2, 3) [14].

**Catheterization technique:** This technique is a modified version of the PAIR technique. Following the first three steps of PAIR, an 8F catheter is inserted into the cavity. Following cavity content aspiration, the catheter is left to gravity drainage for twenty-four hours. When daily drainage drops below 10 cc, a cystogram is performed to show that there is no fistula between the cavity and the biliary tree. After the catheter irrigation with hypertonic saline, all cavity contents are evacuated and the catheter is removed [14].

**MoCaT technique:** This technique is used for treatment of CE 2 and CE 3b hydatid cysts. The aim of this technique is to evacuate of cystic and solid component (membranes and daughter vesicles) of cavity. 14F pig-tail catheter is inserted to cavity. With multiple isotonic saline irrigations, fluid contents and membrane fragments are aspirated. During this method, daughter vesicles are aggressively dissolved. If there is no cystobiliary fistula, hypertonic saline is injected. After waiting 7-10 minutes, all contents are aspirated and the catheter is removed [14].

### Follow-up

The first sonographic examination was performed in the first month after the procedure. In the first year, patients were followed up with by ultrasound every three months; in the second year, every six months; and in the years following that, every year. Our primary follow-up modality was ultrasound. In 6 cases, standard US follow-up was combined with the CT when the US investigations were deemed inadequate for the best assessment.

### Definitions

Technical success was described as the successful completion of all catheterization and PAIR procedure steps. According to the CIRSE classification of complications, complications were categorized as major and minor (15). Major complications (cavity infection, cysto-biliary fistula, and anaphylactic shock) and minor complications (fever, pain, temporary bleeding, and angioneurotic edema) were examined. Clinical success was described as the absence of recurrence or major complication upon follow-up.

The healing criteria included a decrease in cyst volume and size, thickening of the cyst wall and irregularities, a steady decrease in fluid content, and finally pseudotumor appearance. The period between the time of percutaneous procedure and the first follow-up when the cyst was transformed into an inactive form was referred to as the "inactivation time" (Figure 4). Inactivation times of all cysts were determined. On follow-up examinations, the appearance of double-layered wall sign or daughter vesicles was considered as recurrence. By the follow-up ultrasound reports, the follow-up time, last cyst volume at the follow-up, and inactivation time were noted.

Cyst volumes were determined using three orthogonal dimensions taken from two-dimensional ultrasound images ( $A \times B \times C \times 0.523$ ). Age and gender of the patient, the number and size of cysts, the length of follow-up, recurrence rates, and complications and were all determined.

### Statistical analysis

IBM SPSS for Windows, version 22.0, was used to conduct statistical analysis. Parameters of cysts smaller than 6 cm and larger than 6 cm were compared. Kolmogorov Smirnov test was used to evaluate whether the distribution was normal. Student-t test was used to compare the inactivation times of cysts and age ranges of two group. Chi square test was used to compare other parameters (gender, complication, localization, recurrence). A p value of  $<0.05$  was considered statistically significant. Post-hoc power analysis was done using the Clin-Calc calculator ([clincalc.com/stats/Power.aspx](http://clincalc.com/stats/Power.aspx)) for inactivation time.

### Results

The mean age of the patients was  $41.35 \pm 20.33$  years. The long axis of the cysts ranged from 3 cm to 12 cm. The long axis of 30 cysts (55.5 %) was greater than 6 cm and the long axis of 24 cysts (44.4 %) was less than 6 cm.

Technical success rate was 100%. The average follow-up time was  $996 \pm 250$  days. Pretreatment mean cyst volume was 195.5 (15-1,656) ml and post-treatment final cyst volume was 58.6 (4-648) ml. The cysts showed a mean volume



**Table 1.** Comparison of demographic data and other parameters of CE1 hydatid cysts.

	Cysts diameter < 6 cm (n = 24)	Cysts diameter ≥ 6 cm (n = 30)	p
Age (mean ± SD)	40.35 ± 20.31	42.35 ± 20.35	0.455
Gender, (male/female)	10/14	12/14	0.749
Localization, (right/left)	18/6	20/10	0.505
Major Complication, (Yes/None)	1/23	0/30	0.256
Minor Complication, (Yes/None)	1/23	3/27	0.620
Recurrence	0/24	1/29	0.367
Cyst inactivation time, (months)	7.75 ± 2.72	14.75 ± 6.73	<b>0.001</b>

reduction of 70.1% on follow up. 52 of the 54 cysts met the healing criteria on follow-up. Treatment was effective in 48 patients. The long-term success rate of treatment was 96%.

The post-hoc power value for inactivation time was 95%. The mean inactivation time of cysts smaller than 6 cm was 7.75 months. The mean inactivation time of cysts larger than 6 cm was 14.75 months. Cysts smaller than 6 cm had a significantly shorter inactivation time than cysts larger than 6 cm ( $p=0.01$ ). No significant difference was observed in terms of other parameters such as age, gender, cyst localization, major/minor complication, recurrence, and follow-up period. (Table 1).

Cystobiliary fistula was not observed in any patient. Major complication (abscess) was detected in one patient (2%). In this patient, abscess was detected 10 months after the procedure and the abscess was drained with the percutaneous Seldinger technique. Recurrence (CE2 hydatid cyst) was detected in the ninth month after the procedure in one patient (2%). Recurrence was treated with the modified catheterization (MoCAT) technique. Intra-abdominal spread, anaphylaxis, or mortality did not develop in any patient. Post-procedural pain developed in 3 patients as a minor complication (6%). Other minor complications, such as fever, tachycardia, angioneurotic edema did not develop in any of the patients.

## Discussion

This is a retrospective study showing the long-term results of PAIR treatment of CE1 liver hydatid cyst. Our study showed that long-term success rate of PAIR was highly effective. Cysts smaller than 6 cm had a significantly shorter inactivation time than cysts larger than 6 cm. Recurrence and cavity infection occurred in two patients. Abscess and recurrence were treated percutaneously. In our study, we did not experience any significant percutaneous approach-related problems, such as parasite seeding, anaphylactic shock, or patient mortality.

When compared to the outcomes of surgery and albendazole treatment, percutaneous treatment of hepatic CE1 (PAIR and catheterization procedures) was found to be very efficient and secure [16, 17]. Therefore, percutaneous treatment approaches have largely replaced surgery [18]. Gupta et al showed that the rate of biliary fistula and cavity abscess was significantly higher in the surgically treated group than in the PAIR-treated group [19]. Also, compared to a surgical technique, percutaneous approach is less invasive and more economical to treat numerous

hepatic cysts, splenic hydatid cysts or other abdominal hydatid cysts [20, 21, 22, 23].

Percutaneous treatment options for liver CE1 and CE3a cysts include catheterization and PAIR methods. With a success rate of 96–100%, percutaneous management of CE1 and CE3a cysts has proven to be both safe and effective [24, 25, 26]. The success rate of our study was 96%.

Percutaneous techniques is associated with lower morbidity and mortality, low recurrence rates and shorter hospital stays. Complications such as a severe allergic reaction, pneumothorax, cavity infection, and developing of a cystobiliary fistula have been reported in up to 9% of patients [27, 28]. In our study, the rate of major complication and minor complication was 2% and 6% respectively.

In a study comparing PAIR and catheterization procedures, the rate of major complications was found to be 2.94% in the PAIR group and 36.84% in the catheterization group [29]. In the related study, percutaneous treatment was applied to CE1 and CE3a cysts, and the complication rate in catheterization group was higher than in PAIR group. Lower rates of complications and length of hospital stay are advantages of PAIR technique. In the presence of cystobiliary fistula, the catheterization technique should be used.

In our study, PAIR treatment technique was applied only to patients with CE1. Long axis of the largest cyst was 12 cm. The long axis of 30 cysts was greater than 6 cm and the long axis of 4 cysts was greater than 10 cm. The PAIR technique is employed for the management of CE1 and CE3a cysts that measure less than 5 cm in diameter [10]. According to our study, PAIR treatment is effective and safe even for CE1 cysts larger than 6 cm. Large-scale studies should be conducted to evaluate the effectiveness of PAIR in giant (> 10 cm) CE1 cysts.

Turgut et al showed that the inactivation time was shorter in patients with longer catheterization time [30]. In our study, cysts larger than 6 cm had a significantly longer inactivation time than cysts smaller than 6 cm ( $p=0.01$ ). This finding may be seen as a disadvantage of the PAIR technique. To evaluate this, in cysts larger than 6 cm, the inactivation times of the PAIR technique and catheterization technique should be compared. Studies on this should be done.

Recurrence is still one of the most problematic aspects of managing hydatid disease [31]. The rate of recurrence following percutaneous treatment for hydatid cysts ranges from 0–4% [32]. In our study, recurrence rate was 2% and daughter vesicles were detected in the patient with relapse.

This patient was treated successfully with MoCAT technique.

Our study includes a number of limitations. The relatively small number of patients and the retrospective nature are limitations of the study.

### Conclusion

In conclusion, the primary line of treatment for CE1 cysts should be percutaneous methods. The long-term results of PAIR treatment for CE1 hepatic hydatid cysts are satisfactory. Although the inactivation time is longer in cysts larger than 6 cm, PAIR technique used to treat liver CE 1 hydatid cysts are effective and secure. Percutaneous treatment techniques have low complication rates and low recurrence rates. Percutaneous treatments such as MoCAT technique can be used for local recurrences.

### Ethical approval

This study was approved by Firat University Non-Interventional Research Ethics Committee (Date: 25.05.2023, Protocol number: 2023/07-17).

### References

- Aydın Y, Çelik M, Ulaş A.B, Eroğlu A. Transdiaphragmatic approach to liver and lung hydatid cysts. *Turk J Med Sci.* 2012;42: 1388-93.
- McManus DP, Zhang W, Li J, Bartley PB. Echinococcosis. *Lancet.* 2003;362: 1295–304.
- Moro P, Schantz PM. Echinococcosis: a review. *Int J Infect Dis.* 2009;13: 125–33.
- Turgut AT, Akhan O, Bhatt S, Dogra VS. Sonographic spectrum of hydatid disease. *Ultrasound Q.* 2008;24: 17-29.
- WHO informal working group. International classification of ultrasound images in cystic echinococcosis for application in clinical and field epidemiological settings. *Acta Trop.* 2003;85: 253–61.
- Franchi C, Di Vico B, Teggi A. Long-term evaluation of patients with hydatidosis treated with benzimidazole carbamates. *Clin Infect Dis.* 1999;29: 304–9.
- Koroglu M, Erol B, Gurses C, et al. Hepatic cystic echinococcosis: percutaneous treatment as an outpatient procedure. *Asian Pac J Trop Med.* 2014;7: 212–5.
- Popa AC, Akhan O, Petrutescu MS, et al. New options in the management of cystic echinococcosis—a single centre experience using minimally invasive techniques. *Chirurgia (Bucur).* 2018;113: 486–96.
- Macpherson CNL, Vuitton DA, Gharbi HA, Caremani M, Frider B, Brunetti E, et al. International classification of ultrasound images in cystic echinococcosis for application in clinical and field epidemiological settings. *Acta Trop.* 2003;85: 253–61.
- Kahriman G, Ozcan N, Dogan S and Karaborklu O. Percutaneous treatment of liver hydatid cysts in 190 patients: a retrospective study. *Acta Radiol.* 2017 Jun;58(6):676-684.
- Wen H, Vuitton L, Tuxun T, et al. Echinococcosis: Advances in the 21st Century. *Clin Microbiol Rev* 2019;32: pii:e00075-18.
- Akhan O, Gumus B, Akinci D, Karcaaltıncaba M, Ozmen M. Diagnosis and percutaneous treatment of soft tissue hydatid cysts. *Cardiovasc Intervent Radiol* 2007;30: 419-25.
- Akhan O, Yildiz AE, Akinci D, Yildiz BD, Ciftci T. Is the adjuvant albendazole treatment really needed with PAIR in the management of liver hydatid cysts? A prospective, randomized trial with short-term follow-up results. *Cardiovasc Intervent Radiol.* 2014;37: 1568–74.
- Akhan O. Percutaneous treatment of liver hydatid cysts: to PAIR or not to PAIR. *Curr Opin Infect Dis.* 2023 Oct 1;36(5):308-317.
- Filippiadis DK, Binkert C, Pellerin O, Hoffmann RT, Krajina A, Pereira PL. Cirse quality assurance document and standards for classification of complications: the cirse classification system. *Cardiovasc Intervent Radiol.* 2017;40: 1141–6.
- Kern P, Menezes da Silva A, Akhan O, et al. The echinococcoses: diagnosis, clinical management and burden of disease. *Adv Parasitol.* 2017;96: 259–369.
- Smego RA Jr, Bhatti S, Khaliq AA, Beg MA. Percutaneous aspiration-injection-reaspiration drainage plus albendazole or mebendazole for hepatic cystic echinococcosis: a meta-analysis. *Clin Infect Dis.* 2003;37: 1073–83.
- Group WHOIW. International classification of ultrasound images in cystic echinococcosis for application in clinical and field epidemiological settings. *Acta Trop.* 2003;85: 253–61.
- Gupta N, Javed A, Puri S, Jain S, Singh S, Agarwal AK. Hepatic hydatid: PAIR, drain or resect? *J Gastrointest Surg.* 2011;15: 1829–1836.
- Akhan O, Akkaya S, Dagoglu MG, et al. Percutaneous treatment of splenic cystic echinococcosis: results of 12 cases. *Cardiovasc Intervent Radiol.* 2016;39: 441–6.
- Akhan O, Canyigit M, Kaya D, et al. Long-term follow-up of the percutaneous treatment of hydatid cyst in the adrenal gland: a case report and review of the literature. *Cardiovasc Intervent Radiol.* 2011;34(Suppl 2): S256–S259259.
- Akhan O, Ustunsoz B, Somuncu I, et al. Percutaneous renal hydatid cyst treatment: long-term results. *Abdom Imaging.* 1998;23: 209–13.
- Yagci G, Ustunsoz B, Kaymakcioglu N, et al. Results of surgical, laparoscopic, and percutaneous treatment for hydatid disease of the liver: 10 years experience with 355 patients. *World J Surg.* 2005;29: 1670–9.
- Köroğlu M, Erol B, Gürses C, et al. Hepatic cystic echinococcosis: percutaneous treatment as an outpatient procedure. *Asian Pac J Trop Med* 2014; 7: 212–215.
- Kahriman G, Ozcan N, Donmez H. Hydatid cysts of the liver in children: percutaneous treatment with ultrasound follow-up. *Pediatr Radiol* 2011; 41: 890–894.
- Goktay AY, Secil M, Gulcu A, et al. Percutaneous treatment of hydatid liver cysts in children as a primary treatment: long-term results. *J Vasc Interv Radiol* 2005; 16: 831–839.
- Kabaalioglu A, Ceken K, Alimoglu E, et al. Percutaneous imaging-guided treatment of hydatid liver cysts: do long-term results make it a first choice? *Eur J Radiol* 2006; 59: 65–73.
- Giorgio A, de Stefano G, Esposito V, et al. Long-term results of percutaneous treatment of hydatid liver cysts: a single center 17 years experience. *Infection* 2008; 36: 256–261.
- Akhan O, Erdoğan E, Ciftci TT, et al. Comparison of the Long-Term Results of Puncture, Aspiration, Injection and Re-aspiration (PAIR) and Catheterization Techniques for the Percutaneous Treatment of CE1 and CE3a Liver Hydatid Cysts: A Prospective Randomized Trial. *Cardiovasc Intervent Radiol.* 2020 Jul;43(7):1034-1040.
- Turgut B, Öncü F. The Conversion Time of Cysts to Inactive form After Percutaneous Treatment of Hepatic Hydatid Disease and Predisposing Factors in This Process. *Med Bull Haseki* 2020;58: 286-292.
- Piccoli L, Tamarozzi F, Cattaneo F, Mariconti M, Filice C, Bruno A, et al. Longterm sonographic and serological follow-up of inactive echinococcal cysts of the liver: hints for a “watch-andwait” approach. *PLoS Negl Trop Dis.* 2014;8.
- Köroğlu M, Erol B, Gürses C, et al. Hepatic cystic echinococcosis: percutaneous treatment as an outpatient procedure. *Asian Pac J Trop Med* 2014;7: 212–215.