



Can mediastinum cause referred pain in idiopathic scoliosis?

Ahmet Payas^{a,*}, Sabri Batın^b

^aAmasya University, Faculty of Medicine, Department of Anatomy, Amasya, Türkiye

^bKayseri City Education and Training Hospital, Department of Orthopedics and Traumatology, Kayseri, Türkiye

ARTICLE INFO

Keywords:

Scoliosis
Mediastinum
Lung
Referred Pain
Pleura Parietalis

Received: Aug 25, 2023

Accepted: Oct 13, 2023

Available Online: 25.10.2023

DOI:

[10.5455/annalsmedres.2023.08.221](https://doi.org/10.5455/annalsmedres.2023.08.221)

Abstract

Aim: In idiopathic scoliosis (IS), the mechanism of action of the pain that occurs, especially in the back and neck region, with the increase in curvature, is not known exactly. In the study, the relationship between these pains and the mediastinum was investigated.

Materials and Methods: The study, which was planned retrospectively, included 25 individuals with IS (Lenke Type I) and 21 healthy individuals. Individuals with IS determined the regions where they felt the most pain on the body diagram. The lung and mediastinal volumes of the participants were measured in mm³ on computed tomography (CT) images. The ratios of the area occupied by the lung and mediastinum in the thoracic cavity were calculated in each group. The obtained data were evaluated using the IBM SPSS 23.0 program, and $p < 0.05$ was considered statistically significant.

Results: There was no significant difference between the two groups in terms of baseline characteristics ($p > 0.05$). It was determined that individuals with IS felt the most pain in the 3rd, 4th, and 5th cervical and 2nd, 3rd, 4th, 5th, and 6th thoracic spinal nerve dermatomas regions. Compared to the control group, the area covered by the lung in the thoracic cavity decreased by 50% in the IS group, while the area covered by the mediastinum increased at the same rate ($p < 0.001$).

Conclusion: We think that the pain that occurs in the neck and shoulder region with the increase in the degree of curvature in individuals with IS with a major curvature in the thoracic region (Lenke Type I) is referred to as pain originating from the mediastinum.



Copyright © 2023 The author(s) - Available online at www.annalsmedres.org. This is an Open Access article distributed under the terms of Creative Commons Attribution-NonCommercial-NoDerivatives 4.0 International License.

Introduction

Idiopathic scoliosis (IS) is a spinal curvature that is mostly seen in the adolescent group, and its etiology is still unclear [1]. It is very rare for individuals with IS to go to the hospital complaining of neck or back pain at the initial stage of the curve. Therefore, the diagnosis of IS is usually made by school screening or by family members asymmetries in the back or waist region of the individual with IS [2]. Since rotation and lateral flexion of the spine would cause mechanical stresses such as tension or compression on the structures around the spine, pain was expected to occur in all stages of IS [3]. However, this situation is different in IS, and pain, which is not common in the first stages of the curve, manifests itself more in the back and neck region with the increase in the degree of major curvature [4-6]. The course and mechanism of action of this pain in IS have not yet been fully elucidated [7].

Rotation and lateral flexion of the vertebrae in IS cause the alignment of the spine and ribs to deteriorate and the

structures in the cavitas thoracis to be stressed or displaced [8]. The lungs and mediastinum are most affected by the change in Cavitas thoracis. Especially since the borders of the mediastinum are surrounded by the pain-sensitive pleura parietalis, changes in the mediastinum can trigger pain [9]. The pleura parietalis sections forming the mediastinum borders are innervated by the nerve (n.) phrenicus. A pain originating from here can cause reflected pain in the neck root and shoulder regions [10-12]. This referred pain can be explained by the fact that the nerve supraclavicularis responsible for the innervation of the neck root and shoulder region and the nerve phrenicus (C3, C4, C5) originate from the same medulla spinalis segments [11,12]. Lung and mediastinum volumes are closely related. Decreased lung volumes can trigger mediastinum enlargement and cause pain by stimulating the pleura parietalis, which forms its borders [9].

We think that the pain seen especially in the neck and shoulder region, with the progression of the curvature in individuals with IS whose major curvature is located in the thoracic region is the reflected pain caused by increased pressure on the pleura parietalis as a result of mediastinum

*Corresponding author:

Email address: fizyopayass@gmail.com (Ahmet Payas)

enlargement. For this purpose, the area occupied by the lung and mediastinum in the thoracic cavity will be determined on the computed tomography (CT) images of individuals with IS and compared with healthy individuals. In addition, it will be examined whether the areas of pain felt in individuals with IS and the areas of reflected pain originating from the mediastinum overlap.

Materials and Methods

Participants and study groups

Patients who were diagnosed with idiopathic scoliosis (IS) in our clinic within the last 6 months and whose major curvature was between 20 and 60 degrees were included in this retrospective study. Local ethics committee approval (Hitit University, 03.01.2023/2022-28) was obtained, and the study was conducted in accordance with the Declaration of Helsinki. The data of the IS individuals who had thoracic region computed tomography (CT) in the last 6 months were digitally recorded. As a control group, asymptomatic individuals who applied to our clinic and had a CT image of the thoracic region in the last 6 months were retrospectively scanned. The sample of this study was determined by performing power analysis with G-power 3.1.9.4, program $\alpha = 0.05$, $\beta = 0.10$, effect size = 0.80; each study and control group should have at least 21 patients. The IS Group and Control Group were comprised of at least 21 patients who met the inclusion criteria in both groups.

IS group, inclusion criteria: It consisted of individuals aged 18–40 who were followed up with the diagnosis of Lenke Type 1 (Right Thoracic) idiopathic scoliosis with a major curvature angle between 20–60 degrees. Attention was paid to the absence of trauma, surgery, or any neurological, pulmonary, or orthopedic disease that would affect the thoracic region in individuals with IS. It was paid attention that the participants to be included in the control group were between the ages of 18 and 40 and did not have any deformity in the thoracic region or a disease that would affect the thoracic region as a result of clinical examination and postural analysis. Volunteers who agreed to participate in the study were invited to the hospital. After the informed consent form was signed, postural analysis and pain assessment were performed, and the data obtained were digitally recorded. The CT data of 95 IS individuals were accessed, and, 25 IS individuals who met the study criteria were included in the study (Table 1). In the control group, 21 cases meeting the criteria were included in the study.

Definition of lateral deviation of the vertebrae using with Cobb’s angle

Radiological evaluation of scoliosis in all participants was made by an orthopedic specialist with 10 years of professional experience, based on scoliosis measurements repeated twice, one month apart.

Evaluation of the location of pain in individuals with AIS

The duration, frequency, severity, and factors that increase the pain were evaluated during the interview. The location of pain was divided into eight regions on the body diagram. The first region is right C3, C4, and C5 cervical;

Table 1. Flow diagram of study inclusion and exclusion criteria.

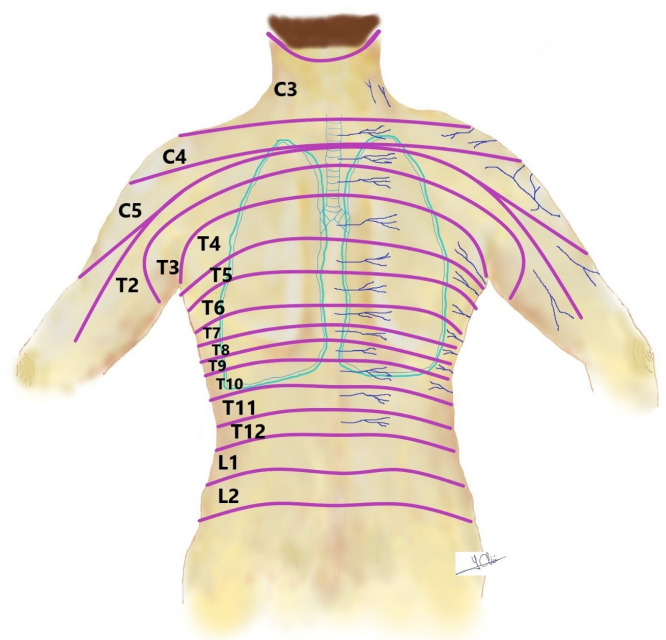
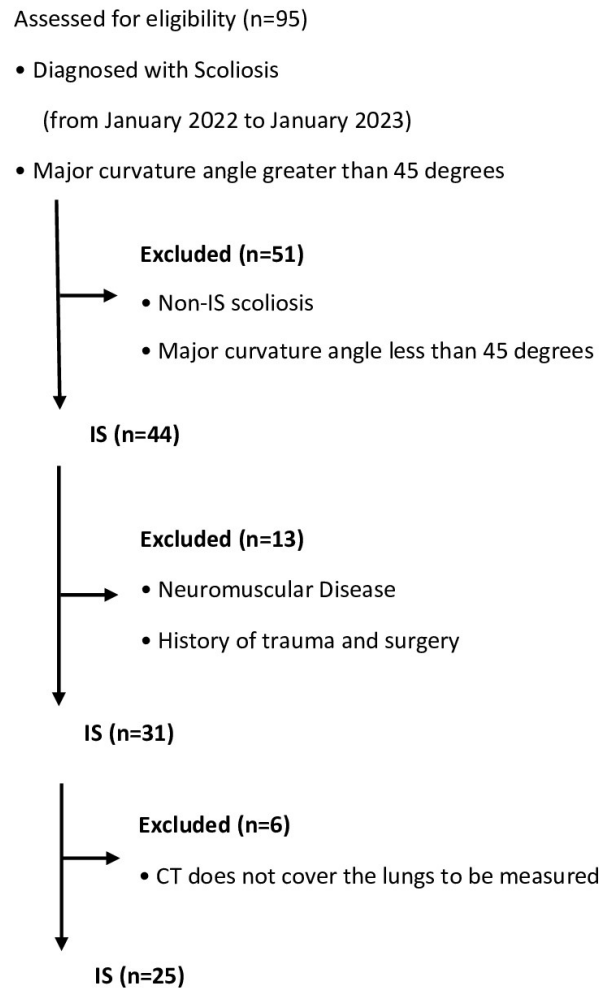


Figure 1. Body diagram.

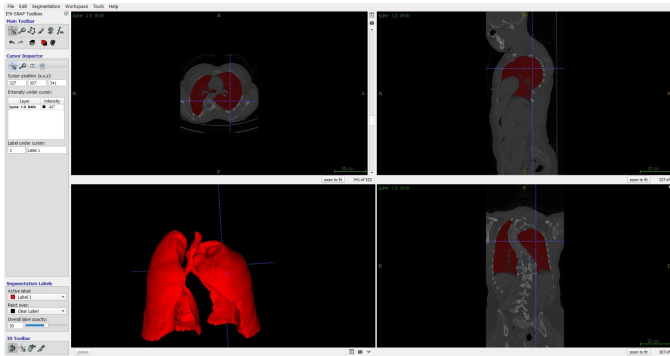


Figure 2. Calculation of lung volume in individuals with idiopathic scoliosis.

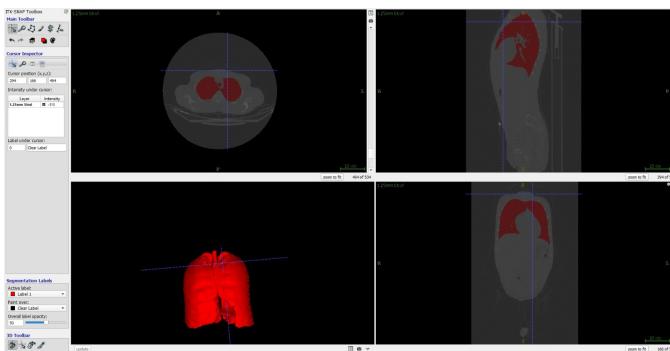


Figure 3. Calculation of lung volume in healthy individuals.

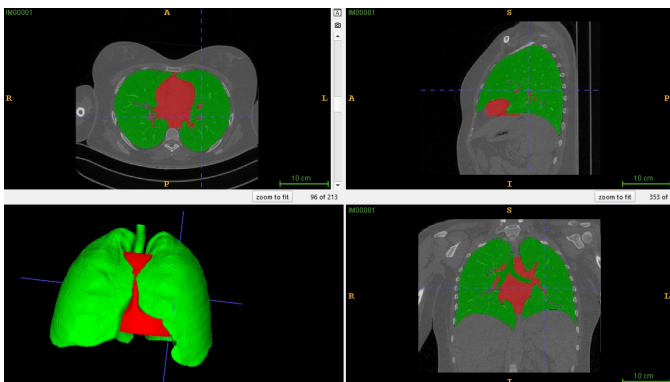

Figure 4. Three-dimensional representation of the lung and mediastinum, the volume of which is measured.

the second region is left C3, C4 and C5 cervical; the third region is right T2, T3, T4, T5 and T6 thoracic; the fourth region is left T2, T3, T4, T5 and T6 thoracic; the fifth region is right T7, T8, T9, T10, T11, and T12 thoracic; the sixth region is left T7, T8, T9, T10, T11, and T12 thoracic; the seventh region is right L1 and L2 lumbar; and the eighth region consists of L1 and L2 lumbar spinal nerve dermatoma regions (Figure 1). Individuals with IS selected areas of pain over these areas.

Computed tomography (CT) capture and lung volume calculation

CT imaging was performed on a multi-detector CT scanner (Philips Ingenuity Core 128, Philips, The Netherlands).

CT device with a section thickness of 1.25 mm in the axial plane in accordance with the protocol, axial images, coronal and sagittal reformat images created from these images, and 3D images were evaluated together. Today, there are powerful tools that provide high efficiency and accuracy that manually, semi-automatically, and automatically segment anatomical structures over medical images. In this study, the Insight Segmentation and Registration Tool Kit (ITK-SNAP) program was used to calculate the volumes of the right and left lungs. In the ITK-SNAP program, the volume calculation process is done in two different ways: manually and semi-automatically. In our study, the volumes of the right and left lungs were calculated using the automatic segmentation algorithm in the ITK SNAP program. Studies have proven that calculating the volume of any anatomical structure with ITK-Snap software is a reliable and valid method [13,14]. The CT data received in the segmentation process in Digital Imaging and Communications in Medicine (DICOM) format was loaded into the ITK SNAP toolkit. After the ITK SNAP program was opened, the "Active Label" and Draw Over settings were made in the "Quick Label Picker" tab, and the right, left lung, and mediastinum borders were determined in the axial, coronal, and sagittal planes. The algorithm divides the pixels corresponding to the volume of the right, left lung, and mediastinum in all CT data slices into a certain class and calculates their volume in mm³ (Figure 2), (Figure 3), (Figure 4). Statistical analysis was performed by averaging the volume data measured twice at different times.

Statistical analysis

Statistical analysis of the data was done with the help of the IBM SPSS 23.00 package program. The normal distribution of the data in the study was analyzed by considering five important parameters (Skewness-Kurtosis, standard deviation/mean, Q-Q plots, histogram, and Shapiro-Wilk test). The number of data was sufficient, and the parameters showing a normal distribution were given as mean±std. The Independent Samples T Test was applied for comparison between independent pairs. ROC curve analysis was performed to determine the risk factor. The area under the curve (AUC) was determined. Sensitivity and specificity values were determined by determining the cut off values. In the study, $\alpha = 0.05$ was accepted, and the $p < \alpha$ value was found to be statistically significant.

Results

The mean age of the groups was calculated as 21.4 ± 1 years and 22.2 ± 3 years in the IS and control groups, respectively. The mean of the major curvature angle of the IS group was 40.6 ± 3.2 degrees. The descriptive characteristics of the participants are shown in Table 2. There was no significant difference between the study groups in terms of descriptive characteristics ($p > 0.05$).

According to the body outline diagram, it was determined that the most pain was in the 3rd, 4th, and 5th right cervical and 2nd, 3rd, 4th, 5th, and 6th right thoracic spinal nerve dermatoma areas in individuals with IS (Figure 5).

Total lung volume was reduced by 50% in the IS group compared to the control group ($p < 0.001$). The volume

Table 2. Comparison of mediastinum and lung volume between groups.

	IS Group	Control Group	Sig. (p)
Age	21.4±1	22.2±3	0.95
Cobb angle	40.6±3.2	-	-
Whole Lung Volume (mm3)	1845200.91±460571.93	3618247.60±816267.21	<0.001
Mediastinum Volume (mm3)	739935.04±137718.78	873490.54±168676.93	0.006
Mediastinum volume ratio (%)*	41.89±7.82	25.57±7.32	<0.001

Parametric data were shown as Mean±Standard Deviation (Mean±Std) and Independent Samples T Test was used for statistical analysis. * Mediastinum volume ratio (%)= (Mediastinum Volume (mm3)*100)/ Whole Lung Volume (mm3).

Table 3. Determination of the critical limit of the mediastinum volume relative to the lung volume.

Risc Factor	AUC (95%)	Cut off	Sensitivity (%)	Specificity (%)
Critical limit ratio of mediastinum volume	0.945 (0.883-1.000)	36.85	0.826	0.909

ROC curve analysis (sensitivity: 82.6%, specificity: 90.9%). * Mediastinum volume ratio (%)= (Mediastinum Volume (mm3)*100)/ Whole Lung Volume (mm3).

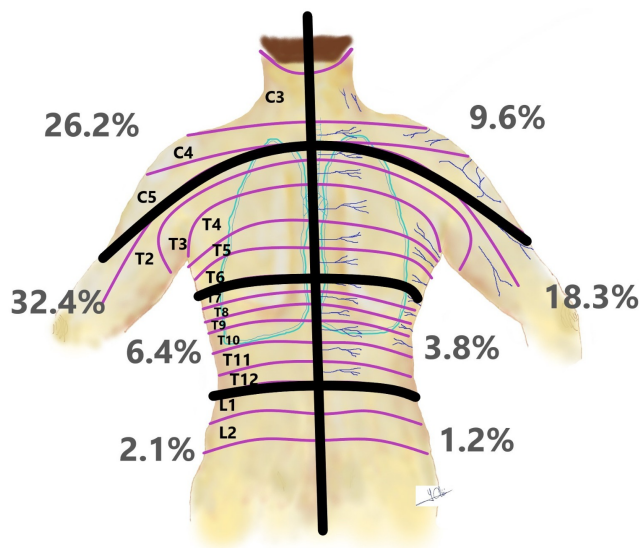


Figure 5. Location of pain in patients with idiopathic scoliosis.

occupied by the mediastinum in the thoracic cavity was 42% in the IS group, while it was 25% in healthy individuals. The ratio of the volume occupied by the mediastinum in the thorax in the IS group was found to be significantly higher than in the control group ($p < 0.001$), (Table 2). ROC curve analysis was performed to determine the critical border of the mediastinum in the thorax region, and the ideal ratio of mediastinum volume to the whole lung volume was found to be 36.85% (sensitivity: 82.6%, specificity: 90.9%) (Table 3). The ratio of mediastinum volume to whole lung volume in the IS group was calculated as 42%, and it was found that the mediastinum volume exceeded the critical limit.

Discussion

The cause of pain, which occurs with the progression of the curvature in IS and spreads to the neck and shoulder, is often overlooked. Our study is the first to investigate

the cause of pain radiating to the neck root and shoulder region in IS. In the present study, the volume occupied by the mediastinum in the thorax increases proportionally in individuals with IS. There is no study in the literature that determines the critical limit ratio of mediastinum volume to lung volume. According to our ROC curve analysis, it was determined that the critical limit ratio of the volume of the mediastinum to the lung volume was 36.85% (sensitivity: 82.6%, specificity: 90.9%). It is seen that the critical limit ratio of mediastinum volume to lung volume is exceeded in individuals with IS.

Referred pain is a type of pain that originates from the visceral organs but is perceived in areas far from the source of the pain [15]. The increase in the anatomical volume of the mediastinum causes the stimulation of pain receptors and pain by pressing on the pleura parietalis sections that form its borders. Studies show that this pain causes reflected pain in the neck root and shoulder region during transportation with N. phrenicus [16-19]. Stimulation of the n. phrenicus, which consists of small, unmyelinated C-fibers with a high arousal threshold, causes pain in the n. supraclavicularis innervation areas originating from the same spinal segments [11,12].

McCormick et al. reported that a patient with increased mediastinum volume as a result of mediastinal lymphoma may have pain radiating to the scapular, shoulder, and arm regions. He emphasized that it should not be forgotten that the pain felt in the scapular, shoulder, and arm regions may originate from the mediastinum [20]. Kaako et al. found a mass in the mediastinum of a 33-year-old male patient with severe upper back, neck, and shoulder pain for three weeks. They suggested that the mass may cause pain by forcing the anatomical boundaries of the mediastinum [21]. The pain radiating to the neck root, upper back, and shoulder areas of patients after thoracic surgery attracted the attention of researchers. They stated that this pain, which emerged as a result of the studies, was a reflection of visceral pain, especially the mediastinum, which was irritated as a result of the surgical procedure [19,22,23].

In the study, it is seen that the lung volume in individ-

uals with IS is significantly reduced compared to healthy individuals. It is seen that the cavity in the thorax, which occurs with the decrease in the lung volume, is filled by the expansion of the mediastinum, and it is seen that the volume of the mediastinum exceeds the critical limit. The increase in mediastinum volume causes irritation in the parts of the pleura parietalis, which form the mediastinum borders and are sensitive to pain. We believe that the pain seen in the neck root and shoulder region, especially with the increase in the degree of curvature in individuals with IS, is referred to as pain originating from the walls of the mediastinum.

It is known that most individuals with IS do not feel much pain at the beginning of the curve, but the pain felt increases as the major curve angle increases [24,25]. Theroux et al. reported that pain originating from the spine may be positively related to the severity of the curvature in IS [5].

Curvature of the spine; located around the columna vertebralis, tension and compression stresses occur on ligaments, joint capsules, periosteum of vertebrae, muscles, anterior dura mater, dural leaves, adipose tissue, and blood vessels, which have a rich nociceptive network. These stresses stimulate nociceptors and cause pain [26].

In individuals with IS, it was expected that the structures rich in nociceptors would produce pain from the moment the deformity began in the spine physiologically. However, in individuals with IS whose major curvature is located in the thoracic region, pain occurs mostly with an increase in the angle of curvature and is mostly seen in the neck root and shoulder regions. Therefore, we do not believe that the source of pain in IS is the structures rich in nociceptors around the spine. We think that this pain is more visceral.

Studies have reported that neck problems are more common in individuals with IS compared to the control group, and they often coexist with back problems [27,28]. It has been reported that female patients with IS have a high incidence of axial neck-shoulder pain, which affects their health-related quality of life [29].

In the present study, it was observed that the regions where intense pain is felt in individuals with IS were the upper thoracic and neck regions. These areas correspond to the areas where the pain caused by the stimulation of the n. phrenicus is reflected. These outputs of the study are supported by the studies carried out. We think that the pain that occurs in IS over time and gets worse day by day is not caused by structures such as muscles, ligaments, and joint capsules around the spine, but rather by the pleura parietalis parts around the mediastinum.

Limitations

Our study has several limitations. The most important of these is that only individuals with IS with a Lenke Type 1 curve were included in the study. Also, the patients were followed up for a short time. The results obtained from the study can be supported by more detailed, prospective, large sample, and longer follow-up studies.

Limitations of our study are the small sample size and the inclusion of only individuals with IS with Lenke Type I (right thoracic) scoliosis. How the mediastinum changes

in individuals with other Lenke Type curvatures has not been examined.

Conclusion

Our hypothesis in the presented study is that the source of pain that occurs with the increase in major curvature in individuals with IS is that it originates from visceral organs rather than tissues such as ligaments, joint capsules, and muscle around the columna vertebralis. If there was pain from the tissues around the spine, pain in IS would have been present from the beginning of the curve. In the study, the ratio of the area occupied by the mediastinum in the thoracic cavity was higher in individuals with IS than in healthy individuals. It is seen that the space formed in the thorax due to the decrease in lung volume in individuals with IS fills with mediastinum enlargement, and the critical limit for mediastinum volume is exceeded. In addition, in the study, it is seen that the areas where individuals with IS feel pain and the areas of reflected pain originating from the pleura parietalis largely overlap. We think that the pain that occurs in the late period and spreads to the neck and shoulder regions in individuals with IS with a major curvature in the thoracic region is caused by the enlargement of the mediastinum and the irritation of the surrounding pleura parietalis.

Ethical approval

Ethical approval of the study was approved by the non-interventional ethics committee of Hitit University with the decision dated 03.01.2023 and numbered 2022-28.

References

1. Payas A, Batin S, Kurtoglu E, Arik M, Seber T, Ucar I, et al. Is the Integration Problem in the Sensorimotor System the Cause of Adolescent Idiopathic Scoliosis? *J Pediatr Orthop*. 2023 Feb 1;43(2):e1111-e1119. doi: 10.1097/BPO.0000000000002300.
2. Sato T, Hirano T, Ito T, Morita O, Kikuchi R, Endo N, et al. Back pain in adolescents with idiopathic scoliosis: epidemiological study for 43,630 pupils in Niigata City, Japan. *Eur Spine J*. 2011 Feb;20(2):274-9. doi: 10.1007/s00586-010-1657-6.
3. Woolf CJ. Central sensitization: implications for the diagnosis and treatment of pain. *Pain*. 2011 Mar;152(3 Suppl):S2-S15. doi: 10.1016/j.pain.2010.09.030.
4. Mayo NE, Goldberg MS, Poitras B, Scott S, Hanley J. The Ste-Justine Adolescent Idiopathic Scoliosis Cohort Study. Part III: Back pain. *Spine (Phila Pa 1976)*. 1994 Jul 15;19(14):1573-81. doi: 10.1097/00007632-199407001-00005.
5. Theroux J, Le May S, Hebert JJ, Labelle H. Back Pain Prevalence Is Associated With Curve-type and Severity in Adolescents With Idiopathic Scoliosis: A Cross-sectional Study. *Spine (Phila Pa 1976)*. 2017 Aug 1;42(15):E914-E919. doi: 10.1097/BRS.0000000000001986.
6. Wong AYL, Samartzis D, Cheung PWH, Cheung JPY. How Common Is Back Pain and What Biopsychosocial Factors Are Associated With Back Pain in Patients With Adolescent Idiopathic Scoliosis? *Clin Orthop Relat Res*. 2019 Apr;477(4):676-686. doi: 10.1097/CORR.0000000000000569.
7. Balagué F, Pellisé F. Adolescent idiopathic scoliosis and back pain. *Scoliosis Spinal Disord*. 2016 Sep 9;11(1):27. doi: 10.1186/s13013-016-0086-7.
8. Mohanty SP, Pai Kanhangad M, Gullia A. Curve severity and apical vertebral rotation and their association with curve flexibility in adolescent idiopathic scoliosis. *Musculoskelet Surg*. 2021 Dec;105(3):303-308. doi: 10.1007/s12306-020-00660-0.
9. Gray H, Williams P, Bannister L. Gray's anatomy. Churchill Livingstone. 1996.

10. Payas A, Ekinci Y, Gürbüz K, et al. Vitamin B12 reduces the negative effects of nicotine on fetal bone development in the rats. *Jt Dis Relat Surg.* 2022;33(1):216-224. doi:10.52312/jdrs.2022.552.
11. Wang NS. Anatomy of the pleura. *Clin Chest Med.* 1998 Jun;19(2):229-40. doi: 10.1016/s0272-5231(05)70074-5.
12. Jones JS. The pleura in health and disease. *Lung.* 2001;179(6):397-413. doi: 10.1007/s004080000075.
13. Gomes AF, Brasil DM, Silva AIV, Freitas DQ, Haiter-Neto F, Groppo FC. Accuracy of ITK-SNAP software for 3D analysis of a non-regular topography structure. *Oral Radiol.* 2020;36(2):183-189. doi:10.1007/s11282-019-00397-y.
14. Almuzian M, Ghatam HMA, Al-Muzian L. Assessing the validity of ITK-SNAP software package in measuring the volume of upper airway spaces secondary to rapid maxillary expansion. *J Orthod Sci.* 2018;7:7. Published 2018 Feb 15. doi:10.4103/jos.JOS_93_17.
15. Cervero F, Laird JM. Visceral pain. *Lancet.* 1999 Jun 19;353(9170):2145-8. doi: 10.1016/S0140-6736(99)01306-9.
16. Danelli G, Berti M, Casati A, Bobbio A, Ghisi D, Mele R, et al. Ipsilateral shoulder pain after thoracotomy surgery: a prospective, randomized, double-blind, placebo-controlled evaluation of the efficacy of infiltrating the phrenic nerve with 0.2%wt/vol ropivacaine. *Eur J Anaesthesiol.* 2007 Jul;24(7):596-601. doi: 10.1017/S0265021507000178.
17. Martinez-Barenys C, Busquets J, de Castro PE, Garcia-Guasch R, Perez J, Fernandez E, et al. Randomized double-blind comparison of phrenic nerve infiltration and suprascapular nerve block for ipsilateral shoulder pain after thoracic surgery. *Eur J Cardiothorac Surg.* 2011 Jul;40(1):106-12. doi: 10.1016/j.ejcts.2010.10.025.
18. Bunchungmongkol N, Pipanmekaporn T, Paiboonworachat S, Saeteng S, Tantraworasin A. Incidence and risk factors associated with ipsilateral shoulder pain after thoracic surgery. *J Cardiothorac Vasc Anesth.* 2014 Aug;28(4):979-82. doi: 10.1053/j.jvca.2013.10.008.
19. Bamgbade OA, Dorje P, Adhikary GS. The dual etiology of ipsilateral shoulder pain after thoracic surgery. *J Clin Anesth.* 2007 Jun;19(4):296-8. doi: 10.1016/j.jclinane.2006.09.010.
20. McCormick Z, Bouffard KJ, Neudorf D, Casey E. A mediastinal mass presenting with unilateral periscapular and arm pain. *PM R.* 2014 Jun;6(6):560-3. doi: 10.1016/j.pmrj.2013.11.012.
21. Kaako A, Kolade VO. Mediastinal extragonadal seminoma presenting as severe back pain in a young male. *Tenn Med.* 2011 Oct;104(9):41-5.
22. Pipanmekaporn T, Leurcharumee P, Punjasawadwong Y, Khorana J, Samerchua A, Sukhupragarn W, Sukuan I, Bunchungmongkol N, Saokaew S. Efficacy of Phrenic Nerve Block and Suprascapular Nerve Block in Amelioration of Ipsilateral Shoulder Pain after Thoracic Surgery: A Systematic Review and Network Meta-Analysis. *Medicina (Kaunas).* 2023 Jan 31;59(2):275. doi: 10.3390/medicina59020275.
23. Yousefshahi F, Predescu O, Colizza M, Asenjo JF. Postthoracotomy Ipsilateral Shoulder Pain: A Literature Review on Characteristics and Treatment. *Pain Res Manag.* 2016;2016:3652726. doi: 10.1155/2016/3652726.
24. Calvo-Muñoz I, Gómez-Conesa A, Sánchez-Meca J. Prevalence of low back pain in children and adolescents: a meta-analysis. *BMC Pediatr.* 2013 Jan 26;13:14. doi: 10.1186/1471-2431-13-14.
25. Bess S, Line B, Fu KM, McCarthy I, Lafage V, Schwab F, et al; International Spine Study Group. The Health Impact of Symptomatic Adult Spinal Deformity: Comparison of Deformity Types to United States Population Norms and Chronic Diseases. *Spine (Phila Pa 1976).* 2016 Feb;41(3):224-33. doi: 10.1097/BRS.0000000000001202.
26. Adams MA, Dolan P. Spine biomechanics. *J Biomech.* 2005 Oct;38(10):1972-83. doi: 10.1016/j.jbiomech.2005.03.028.
27. Moskowitz A, Moe JH, Winter RB, Binner H. Long-term follow-up of scoliosis fusion. *J Bone Joint Surg Am.* 1980 Apr;62(3):364-76.
28. Topalis C, Grauers A, Diarbakerli E, Danielsson A, Gerdhem P. Neck and back problems in adults with idiopathic scoliosis diagnosed in youth: an observational study of prevalence, change over a mean four year time period and comparison with a control group. *Scoliosis Spinal Disord.* 2017 Jun 8;12:20. doi: 10.1186/s13013-017-0125-z.
29. Watanabe K, Ohashi M, Tashi H, Shibuya Y, Makino T, Hasegawa K, et al. Axial Neck-Shoulder Pain After Posterior Correction and Fusion for Adolescent Idiopathic Scoliosis With Structural Thoracic Curve: Does Cranial Fusion Level Affect Neck Symptoms? *Clin Spine Surg.* 2023 Aug 1;36(7):E311-E316. doi: 10.1097/BSD.0000000000001370.