



Use of bovine pericardium-derived mesh in direct-to-implant reconstruction with permanent implant in the ptotic breasts

✉ Mehmet Sagir^{a,*}, ✉ Nur Ramoglu^b, ✉ Erdem Guven^a, ✉ Seda Erozc^c, ✉ Cihan Uras^b

^aPrivate Maslak Acibadem Hospital, Clinic of Plastic, Reconstructive and Aesthetic Surgery, Istanbul, Türkiye

^bAcibadem Mehmet Ali Aydınlar University, Faculty of Medicine, Department of General Surgery, Istanbul, Türkiye

^cPrivate Maslak Acibadem Hospital, Clinic of Radiation Oncology, Istanbul, Türkiye

ARTICLE INFO

Keywords:

Breast reconstruction
Bovine pericardium-derived mesh
Bovine pericardium
Implant-based breast reconstruction
Breast cancer

Received: Jul 28, 2023

Accepted: Sep 28, 2023

Available Online: 25.10.2023

DOI:

[10.5455/annalsmedres.2023.07.168](https://doi.org/10.5455/annalsmedres.2023.07.168)

Abstract

Aim: Breast reconstruction is being performed more frequently in patients who have undergone mastectomy as a result of breast cancer. In this study, it was aimed to clinically investigate the efficacy and safety of the use of bovine pericardium-derived mesh in the creation of preoperative ptosis simulation in patients with grade 1-2-3 ptosis in whom skin reduction techniques are not applied and who underwent mastectomy and reconstruction with a permanent implant.

Materials and Methods: Between January 2019 and April 2022, patients with grade 1, 2, and 3 breast ptosis who underwent a nipple-sparing mastectomy and simultaneous breast reconstruction with a permanent implant using bovine pericardium-derived mesh were evaluated retrospectively. Preoperative and postoperative (minimum 1 year after) anterior and oblique images of patients were evaluated. If the ptosis grade did not change in the postoperative image compared to the preoperative image, it was considered successful. If ptosis did not occur, natural breast view was not formed or the reconstruction failed, it was considered unsuccessful.

Results: A total of 123 patients, 191 breasts, 55 of which were unilateral and 68 bilateral, were included in the study. The average follow-up time was 26 months. The dual plane was chosen for 130 breasts and pre pectoral plane was selected for 61 breasts. The mean age of the patients was 43.7 years. Preoperative ptosis was restored in 180 (94.2%) of 191 breasts. In five breasts with recurrent seroma formation, the bovine pericardium-derived mesh was found to be nonvascularized and was removed. No implant extrusion was observed in any of the patients during the follow-ups.

Conclusion: Bovine pericardium-derived mesh is an effective and safe material in patients with ptotic breasts. In most of the patients' breasts, bovine pericardium-derived meshes are vascularized and integrated with the tissue. Therefore, the appearance of ptosis is reestablished after surgery with bovine pericardium-derived mesh.



Copyright © 2023 The author(s) - Available online at www.annalsmedres.org. This is an Open Access article distributed under the terms of Creative Commons Attribution-NonCommercial-NoDerivatives 4.0 International License.

Introduction

Breast cancer is one of the mostly seen cancers in which the life expectancy reached above 90% with the early detection modalities [1]. Therefore patients are living with their new breasts for a longer time after breast cancer surgery. Mental well-being also became an issue since breast conservation and reconstruction affects female psychology highly [2,3]. That is why the reconstruction of the remaining breast is one of the crucial aspects of breast cancer treatment.

Breast reconstruction is being performed more frequently in patients who have undergone mastectomy as a result

of breast cancer. The use of biological and synthetic meshes in breast reconstruction has made the application of simultaneous breast reconstruction with mastectomy widespread [4-9]. Biological meshes are obtained from human cadaver skin, bovine pericardium or porcine skin after undergoing certain processes and extracted from their cells [10]. In the literature, there are many studies on the safety of using biological meshes obtained from bovine pericardium in human body and human breasts in particular [6,9,11,12].

Breast ptosis is a condition that can occur either with puberty or at any time in a woman's life after puberty. The ptosis in breast classified by Regnault as pseudoptosis, grade 1, 2 and 3 [13]. Different mastopexy types are preferred for different ptosis grades [14]. In reconstruction,

*Corresponding author:

Email address: mdmehmetsagir@gmail.com (✉ Mehmet Sagir)

approach to the breast may change according to different degrees of ptosis.

If skin reduction techniques will not be used in ptotic breast reconstruction, it is important to recreate the ptosis for natural view. If ptosis is not established again, sagging of the skin over the prosthesis, unnatural appearance may occur. In this study, it was aimed to clinically investigate the efficacy and safety of the use of bovine pericardium-derived mesh in creation of preoperative ptosis simulation in patients with grade 1-2-3 ptosis in whom skin reduction techniques are not applied and who underwent mastectomy and reconstruction with permanent implant.

Materials and Methods

Between January 2019 and April 2022, patients with grade 1, 2 and 3 breast ptosis who underwent nipple-sparing mastectomy and simultaneous breast reconstruction with a permanent implant using bovine pericardium-derived mesh were evaluated retrospectively. Ptosis was classified according to Regnault classification [13]. Ptosis in patients was evaluated separately for each breast. Breast ptosis in patients is shown in Figure 1 and Figure 2. Patients who underwent skin reduction for any reason were excluded from the study. The evaluation was made by the operation nurse and assistant of the physician. Preoperative and postoperative (minimum 1 year after) anterior, oblique and lateral images of patients were evaluated. If ptosis occurred in the postoperative image compared to the preoperative image and natural breast view formed, it was considered successful (shown in Figure 1 and Figure 2). If ptosis did not occurred, natural breast view was not formed or the reconstruction failed, it was considered unsuccessful. For a natural breast appearance, it was checked in the anterior view whether the medial and lateral quadrants of the breast were formed, and in the lateral and oblique views whether the inferior and superior poles were formed (shown in Figure 1).

Patients who received radiotherapy were not included in the study.

This study protocol was reviewed and approved by Acibadem Mehmet Ali Aydınlar University Medical Research Evaluation Board (ATADEK), approval number [2023-07/248].

Data were calculated manually.

Results

A total of 123 patients, 191 breasts, 55 of which were unilateral (shown in Figure 2) and 68 bilateral (shown in Figure 1), were included in the study. Two patients underwent bilateral prophylactic mastectomy. While 121 breasts had cancer, 70 breasts underwent risk-reducing surgery. Average follow-up time was 26 months (ranged from 39 to 12 months). Dual plane was chosen in 130 breasts and prepectoral plane was selected in 61 breasts. Both planes (dual and prepectoral) were used in all groups. In all patients anatomical texture implant was used.

The mean age of the patients was 43.7 years (ranged from 34 to 62 years). Unilateral reconstruction was performed in 55 patients and bilateral reconstruction was performed in 68 patients. The highest number of patients had grade

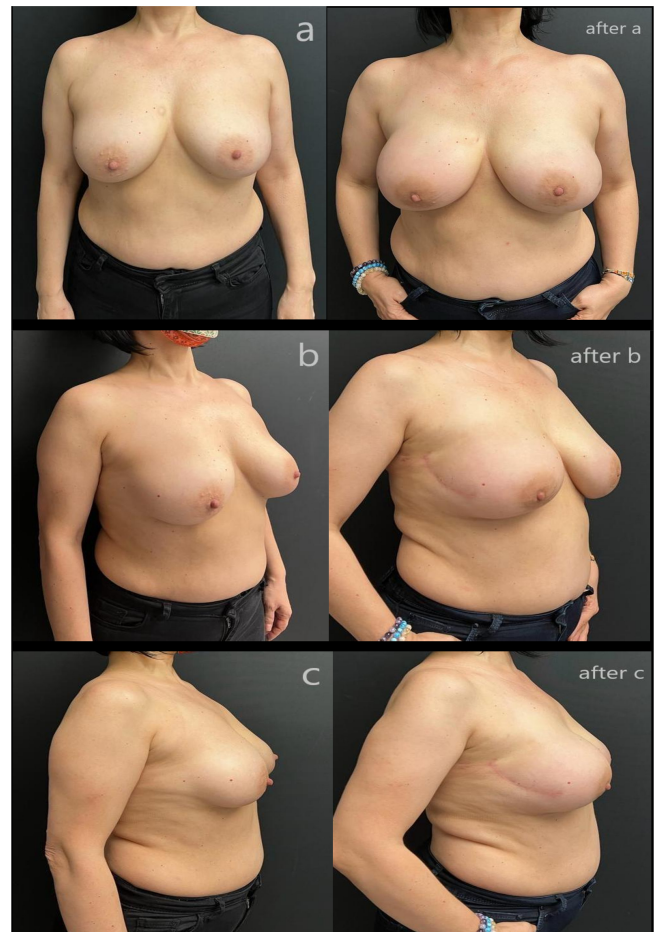


Figure 1. 47-year-old multiparous patient with grade 2 ptosis. Dual plane bilateral reconstruction with bovine pericardium-derived mesh was performed in the patient with right breast cancer. Preoperative anterior (a), oblique (b), lateral (c) view. Postoperative 12th month anterior (a), oblique (b), lateral (c) view.

Table 1. The demographic and clinic characteristics of the patients and the degree of ptosis.

	Number	Ratio
Age (mean)	34-62 years (43.7 years)	
Unilateral reconstruction	55	
Bilateral reconstruction	68	
Mean BMI	28.6	
Active smoking	21	17 %
Ex smoking	18	14.6 %
Grade 1 ptosis breast	65	34 %
Grade 2 ptosis breast	88	46 %
Grade 3 ptosis breast	38	19.8 %
Removed tissue (mean)	238-678 cc (352 cc)	
Used prosthesis (mean)	245-650 cc (342 cc)	
Comorbidity (Diabetes, Cardiovascular disease, hypertension, collagen vascular disease)	15	12.1 %

Table 2. Complications.

	Complications (per breast)		
	Number	Ratio %	
Full thickness NAC necrosis	5	2.6 %	Excision of necrotic tissue and primary repair were performed.
Full tickness mastectomy flap necrosis	6	3.1 %	Necrosis was at the incision line in 4 breasts and at the skin flap in 2 breasts. Excision of necrotic tissue and primary repair were performed.
Reconstruction failure	3	1.5 %	At the end of the adjuvant treatments, reconstruction was done with the latissimus dorsi flap+the implant.
Infection	6	3.1 %	The patients were treated with IV antibiotics.
Seroma	5	2.6 %	It was explored in operating room conditions. The bovine pericardium was not found to be vascularized and was removed.
Hematoma	2	1 %	It was evacuated in operating room conditions.

2 ptosis. The demographic and clinic characteristics of the patients and the degree of ptosis are given in Table 1.

Preoperative ptosis was restored in 180 (94,2 %) of 191 breasts (shown Figure 1 and Figure 2). Bovine pericardium-derived mesh was removed in 5 of 11 breasts, and implant loss occurred in three of them. There were recurrent seroma formations in these five breasts. The mesh was not vascularized in these breasts. There were six breasts in which bovine pericardium-derived mesh was

not removed and ptosis was not obtained. Two of the patients with implant loss were heavy smokers and had neoadjuvant chemotherapy. Moreover, a patient with implant loss had a history of collagen tissue disease. The patients, in whom we did not experience implant loss, did not have any comorbidities or clinic conditions. No implant extrusion was observed in any of the patients during the follow-ups. Complications are given in Table 2.

Discussion

Direct-to-implant reconstruction became more preferred in current time with its advantages like higher satisfaction, lower morbidity and cost [15]. The improvements in biological mesh/implant technology led the one session surgery to be more widely accepted. In this study, we evaluated the outcomes of breast reconstruction with bovine pericardium-derived mesh in patients who had ptotic breasts and had gone through nipple sparing mastectomy. The results of the postoperative follow-up show that bovine pericardium-derived mesh is a safe and efficient material.

All the biological (human, porcine, bovine) materials have advantages and disadvantages according to their properties. Jagsi et al. claim that using autologous materials conclude with less complication rates including scarring, capsular contracture, infection, pain, skin necrosis, fibrosis and impaired wound healing, and higher satisfaction of the patients [16]. In a meta-analysis by Lee et al. including 20 studies, the complication rates including seroma formation, infection, reconstruction failure and flap necrosis are found to be similar in human cadaveric materials, FlexHD, DermaMatrix, and AlloDerm with a total complication rate of 20 to 40 % [17]. In our study, our total complication rate was 14.1%. Although the patient groups in these studies are not homogenous and the parameters examined are not exactly the same, considering the total complication rates in the literature, it can be said that the bovine pericardium we used in ptotic breast reconstruction did not increase the total complication rate.

Bovine pericardium-derived mesh is used by different med-

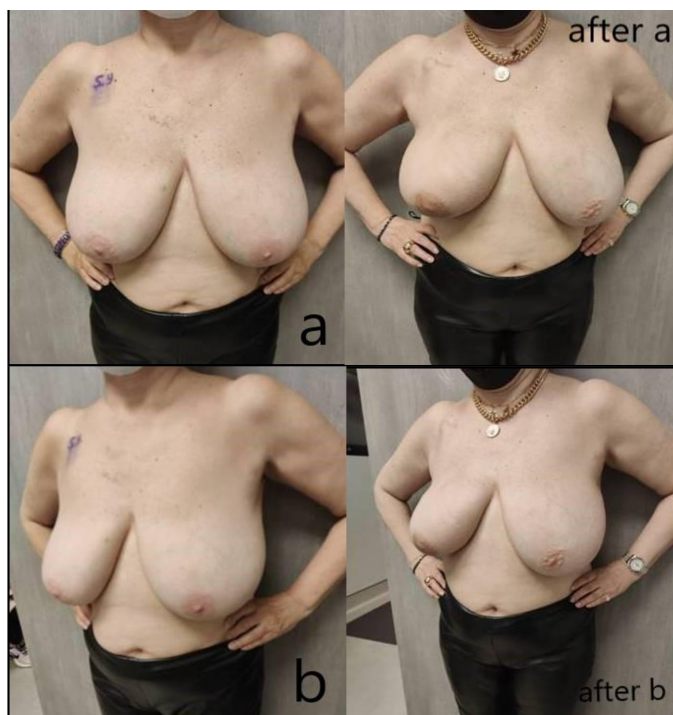


Figure 2. 58-year-old nulliparous patient with grade 3 ptosis. Prepectoral reconstruction with bovine pericardium-derived mesh for right breast cancer. Preoperative anterior (a), oblique (b) view. Postoperative 23th month anterior (a), oblique (b) view.

ical area. In a rat model, comparing polytetrafluoroethylene (PTFE), Fascia lata (Tutoplast), bovine pericardium (Tutopatch) use for incisional hernia, it is shown PTFE and bovine pericardium are safe and effective with acceptable foreign body reaction, adequate strength, especially in recurrent and contaminated cases [10]. In a study of uveal melanoma, Tutopatch is used as a wrapping material for orbital hydroxyapatite implants and it is emphasized that the material is safe to use without any complication to be managed [18]. In another study, in which Tutopatch is used as a graft for reconstruction of inferior vena cava, it is shown that again tutopatch is safe, being compatible with the tissue and without any infective complication. A study by Coleman et al., it is claimed that Tutopatch is suitable for complex venous reconstruction [19]. In our study, in which ptotic breasts were included in the study, it was observed that the bovine pericardium-derived mesh was vascularized in 97,3% of the breasts. Considering the findings in previous literature and the results of our study, the use of bovine pericardium-derived mesh can be considered as one of the safe and effective biomaterials providing a natural appearance in ptotic breast reconstruction.

There are variety of reasons causing breast ptosis like macromastia, weight loss, pregnancy, smoking, aging and hormonal changes [20,21]. Although the reconstructive approach is different according to breast size and degree of ptosis, this subject is out of this study. Since skin reduction techniques were used from the lower pole of the breast in pseudoptosis patients according to our approach, these patients were excluded from the study.

Ptosis of the breast is one of the important issues that must be thought of before reconstruction. This is even more important in unilateral reconstruction, because if the ptotic and natural breast appearance cannot be obtained during reconstruction, the patient may need to live with a serious asymmetry. Grade 3 ptosis accepted as a contraindication for implant for a long period of time, but in recent years there is a consensus that it can be placed prepectorally [22]. We increase the safety of surgery with subpectoral repair in reconstructions with insufficient skin thickness and skin flap circulation disorder and that cannot be performed prepectorally. On the other hand, a natural and ptotic breast can be obtained by placing a bovine pericardium-derived mesh as an extension of the pectoral muscle on the area of the implant that is not covered by the muscle, since the ptosis of the subpectoral implant cannot be achieved sufficiently. In our study, patients with grade 1, 2 and 3 ptosis were reconstructed using dual and prepectoral planes. In the first year visit and evaluation, ptosis was observed in 94,2 % of the patients. It is important to carry out new studies on the behavior of the bovine pericardium-derived mesh in the human tissue in which ptosis cannot be established, in order to clarify the effectiveness of bovine pericardium-derived mesh.

In ptotic breasts, skin flaps are elongated. Additionally the distance between nipple to the jugulum has increased, except for pseudoptosis. Accordingly, the risk of skin flap necrosis increases in this patient group. In patients whose skin flaps are not reduced, if the breast ptosis is not established, asymmetry and unnatural breast appearance

may occur. Bovine pericardium-derived mesh ensures that most of the weight of the prosthesis is transferred to the body instead of the skin flaps in early postoperative period. By keeping the prosthesis fixed in the breast, it prevents shape deformity. It contributes to the formation of a natural breast appearance in the long term period. Since it is a biological product, angiogenesis occur; it integrates with the tissue and gives a similar softness and flexibility as the tissue. We believe that this helps the breast to become ptotic after surgery. In long term period, it increases the distance between the prosthesis and the skin surface. Furthermore, it prevents the extrusion of the implant because of increased pressure at the lower pole of breast. Radiotherapy may adversely affect the breast. In this study, the effectiveness of bovine pericardium-derived mesh in the ptotic breast is investigated. Patients who received radiotherapy were excluded from the study because we could not distinguish whether a possible negative effect on the breast was radiotherapy or mesh.

The retrospective nature and relatively small number of patients are important limitations of this study. The fact that bovine pericardium-derived mesh is a foreign body and a costly product is also among the limitations of this study.

Conclusion

Bovine pericardium-derived mesh is an effective and safe material in patients with ptotic breasts. In most of the patients' breasts bovine pericardium-derived mesh is vascularized and integrates with the tissue. Therefore, appearance of ptosis is reestablished after surgery with bovine pericardium-derived mesh.

Informed consent

Written informed consent was obtained from participants to participate in the study.

Conflict of interest statement

The authors have no conflicts of interest to declare.

Funding sources

This research did not receive any specific grant from funding agencies in the public, commercial, or not-for-profit sectors.

Ethical approval

This study protocol was reviewed and approved by Acibadem Mehmet Ali Aydınlar University Medical Research Evaluation Board (ATADEK), approval number [2023-07/248].

References

1. Ginsburg O, Yip CH, Brooks A, et al. Breast cancer early detection: A phased approach to implementation. *Cancer*. 2020 May 15;126 Suppl 10(Suppl 10):2379-2393. doi: 10.1002/cncr.32887. PMID: 32348566; PMCID: PMC7237065.
2. Dinapoli L, Colloca G, Di Capua B, Valentini V. Psychological Aspects to Consider in Breast Cancer Diagnosis and Treatment. *Curr Oncol Rep*. 2021 Mar 11;23(3):38. doi: 10.1007/s11912-021-01049-3. PMID: 33709235; PMCID: PMC7952347.

3. Elder EE, Brandberg Y, Björklund T, et al. Quality of life and patient satisfaction in breast cancer patients after immediate breast reconstruction: a prospective study. *Breast*. 2005;14(3):201-8.
4. Colwell AS, Taylor EM. Recent Advances in Implant-Based Breast Reconstruction. *Plast Reconstr Surg*. 2020 Feb;145(2):421e-432e. doi: 10.1097/PRS.00000000000006510.
5. Ding BW, Wang HQ, He SS, et al. Application of acellular bovine pericardium patch in implant based immediate breastreconstruction. *Zhonghua Wai Ke Za Zhi*. 2022 Mar 1;60(3):237-243. doi: 10.3760/cma.j.cn112139-20211012-00485.
6. Castagnetti F, Bertani C, Foroni M, et al. The Bovine Pericardium Matrix in Immediate Implant-Based Breast Reconstruction. *Aesthetic Plast Surg*. 2020 Dec;44(6):2051-2060. doi: 10.1007/s00266-020-01651-z. Epub 2020 Feb 28.
7. Kong TH, Chung KJ, Kim T, Lee JH. Effect of acellular dermal matrix thickness and surface area on direct-to-implant breast reconstruction. *Gland Surg*. 2022 Aug;11(8):1301-1308. doi: 10.21037/gs-22-175.
8. Pouzet L, Hotton J, François C, et al. Breast reconstruction with silicone prosthesis and acellular dermal matrix of porcine origin: Retrospective study of 84 cases. *Ann Chir Plast Esthet*. 2022 Jun;67(3):133-139. doi: 10.1016/j.anplas.2022.03.001. Epub 2022 Jun 6.
9. Gubitosi A, Docimo G, Parmeggiani D, et al. Acellular bovine pericardium dermal matrix in immediate breast reconstruction after Skin Sparing Mastectomy. *Int J Surg*. 2014;12 Suppl 1:S205-8. doi: 10.1016/j.ijssu.2014.05.007. Epub 2014 May 22.
10. Kapan S, Kapan M, Goksoy E, et al. Comparison of PTFE, pericardium bovine and fascia lata for repair of incisional hernia in rat model, experimental study. *Hernia*. 2003 Mar;7(1):39-43. doi: 10.1007/s10029-002-0096-7. Epub 2002 Dec 11. PMID: 12612797.
11. Belkorissat RA, Sadoul C, Bouziane Z, et al. Tubular Reconstruction with Bovine Pericardium Xenografts to Treat Native Aortic Infections. *Ann Vasc Surg*. 2020 Apr;64:27-32. doi: 10.1016/j.avsg.2019.10.104. Epub 2020 Jan 10.
12. Morris PD, Furtado R, Pulitano C, et al. Inferior Vena Cava Resection and Reconstruction with Bovine Pericardium for Renal Cell Carcinoma: Complications and Outcomes. *Urology*. 2019 Dec;134:143-147. doi: 10.1016/j.urology.2019.09.006. Epub 2019 Sep 19).
13. Regnault P. Breast ptosis. Definition and treatment. *Clin Plast Surg*. 1976 Apr;3(2):193-203. PMID: 1261176.
14. Qureshi AA, Myckatyn TM, Tenenbaum MM. Mastopexy and Mastopexy-Augmentation. *Aesthet Surg J*. 2018 Mar 14;38(4):374-384. doi: 10.1093/asj/sjx181. PMID: 29365038.
15. Teoh V, Gui G. Direct to implant breast reconstruction with biological acellular dermal matrices. *Br J Hosp Med (Lond)*. 2020 Mar 2;81(3):1-7. doi: 10.12968/hmed.2018.0428a. Epub 2020 Mar 4. PMID: 32240004.
16. Jagsi R, Momoh AO, Qi J, et al. Impact of Radiotherapy on Complications and Patient-Reported Outcomes After Breast Reconstruction. *J Natl Cancer Inst*. 2018 Feb 1;110(2):157–65. doi: 10.1093/jnci/djx148. PMID: 28954300; PMCID: PMC6059091.
17. Lee KT, Mun GH. A Meta-analysis of Studies Comparing Outcomes of Diverse Acellular Dermal Matrices for Implant-Based Breast Reconstruction. *Ann Plast Surg*. 2017 Jul;79(1):115-123. doi: 10.1097/SAP.0000000000001085. PMID: 28509698.
18. Gupta M, Lyon F, Singh AD, et al. Bovine pericardium (Tuttopatch) wrap for hydroxyapatite implants. *Eye (Lond)*. 2007 Apr;21(4):476-9. doi: 10.1038/sj.eye.6702227. Epub 2006 Jan 27. PMID: 16440021.
19. Coleman S, Kerr H, Krishnamurthi V, et al. The use of bovine pericardium for complex urologic venous reconstruction. *Urology*. 2014 Feb;83(2):495-7. doi: 10.1016/j.urology.2013.10.011. Epub 2013 Nov 22. PMID: 24275287.
20. Martinez AA, Chung S. Breast Ptosis. 2022 Jan 14. In: *StatPearls* [Internet]. Treasure Island (FL): StatPearls Publishing; 2023 Jan-. PMID: 33620861.
21. Rinker B, Veneracion M, Walsh CP. Breast ptosis: causes and cure. *Ann Plast Surg*. 2010 May;64(5):579-84. doi: 10.1097/SAP.0b013e3181c39377. PMID: 20354434.
22. Vidya R, Berna G, Sbitany H, et al. Prepectoral implant-based breast reconstruction: a joint consensus guide from UK, European and USA breast and plastic reconstructive surgeons. *Ecancermedalscience*. 2019 May 7;13:927. doi: 10.3332/ecancer.2019.927. PMID: 31281424; PMCID: PMC6592711.