



Evaluation of the necessity of routine histopathological examination in tonsillectomy and/or adenoidectomy operations

Suheyla Kandemir^{a,*}, Gozde Pamuk^b, Tuba Yigit^c

^aKırıkkale Yüksek İhtisas Hospital, Department of Otorhinolaryngology, Kırıkkale, Türkiye

^bKent ENT Hospital, Department of Otorhinolaryngology, Ankara, Türkiye

^cKırıkkale Yüksek İhtisas Hospital, Department of Medical Pathology, Kırıkkale, Türkiye

ARTICLE INFO

Keywords:

Tonsillectomy
Adenoidectomy
Histology
Pathology

Received: Apr 13, 2023

Accepted: Jul 17, 2023

Available Online: 25.07.2023

DOI:

[10.5455/annalsmedres.2023.04.094](https://doi.org/10.5455/annalsmedres.2023.04.094)

Abstract

Aim: The aim of the study is to discuss the necessity of microscopic histopathological examination for routine tonsillectomy and/or adenoidectomy (T&A).

Materials and Methods: Patients who underwent T&A surgery in our clinic between 2017 and 2022 and were diagnosed pathologically were included in the study. The files of the patients were scanned retrospectively from the hospital automation system. Demographic characteristics (age, gender) and histopathological findings of the patients were recorded.

Results: A total of 635 cases were analyzed, of which 294 were female (46.3%) and 341 were male (53.7%). The mean age of the patients was 12.6 ± 7.1 years, and their ages ranged from 3 to 48 years. As a result of histopathological evaluation, the most common diagnosis was chronic lymphoid hyperplasia. No malignancy or unexpected findings were found in any of the samples.

Conclusion: Given the rarity of unexpected clinical diagnoses in routine T&A specimens, it is difficult to justify the cost and effort of histopathologically analyzing each specimen. Therefore, the histopathological request for T&A specimens should be based on specific risk factors.



Copyright © 2023 The author(s) - Available online at www.annalsmedres.org. This is an Open Access article distributed under the terms of Creative Commons Attribution-NonCommercial-NoDerivatives 4.0 International License.

Introduction

Tonsil diseases are common in pediatric and adult otolaryngology practice [1]. A wide variety of diseases affecting this tissue often require tonsillectomy [2]. Tonsillectomy and/or adenoidectomy (T&A) is the most common otolaryngology surgery. While chronic infections and obstructive sleep apnea are the main indications for T&A surgery, it can also be performed as a biopsy procedure to rule out malignancy.

The main reason for investigating the necessity of pathological examination in routine T&A specimens is that the histopathologist's working time is wasted, many other specimens that need attention are damaged, and it imposes a financial burden on the patients [3,4]. Due to the extremely low incidence of unexpected pathologies in childhood, discussions on this issue still continue [5,6]. On the other hand, it is routinely subjected to histopathology in most centers due to avoidance of forensic procedures and

fear of missing some unexpected diseases, especially malignancy.

This study aims to reveal the necessity of routine histopathological examination for T&A.

Materials and Methods

Patients who underwent T&A surgery in our clinic between 2017 and 2022 and were diagnosed with pathology were included in the study. The files of the patients were scanned retrospectively from the hospital automation system. Demographic characteristics (age, gender) and histopathological findings in the files of the patients were recorded. Patients whose pathology diagnosis could not be reached were excluded from the study. Adult patients as well as pediatric patients were included in the study. Diagnostic tonsillectomies were excluded from the study and only routine operations were examined. The patients who would undergo diagnostic tonsillectomy were decided by examining the patient files. Patients who had certain risk factors (significant tonsillar asymmetry, mucosal irregularity, clinical malignancy findings, cervical lymphadenopathy, weight loss, night sweats) in the patient file and who

*Corresponding author:

Email address: dr.suheyla_bostan@hotmail.com (Suheyla Kandemir)

underwent diagnostic tonsillectomy were excluded from the study.

All patients underwent classical T&A under general anesthesia and all specimens were sent to pathology in 10% formaldehyde solution. Samples taken from all patients in our clinic are routinely sent to pathology.

The study protocol was approved by the Kırıkkale University Faculty of Medicine Ethics Committee, decision number: 2023.03.06, date: 29.03.2023. This study was performed as a retrospective file review; therefore, written informed consent was not obtained. The study was performed in accordance with the Declaration of Helsinki guidelines.

Statistical analysis

Statistical analysis was performed using IBM SPSS Statistics version 25.0 (IBM Corp., Armonk, NY, USA). Shapiro-Wilk test and normal distribution parameters were used to evaluate the normality of the data distribution. Wilcoxon test was used to compare dependent parametric variables that were not normally distributed. The Mann-Whitney U test was used to compare the nonparametric independent variables in the two groups. Statistical significance level was accepted as $p < 0.05$.

Results

In the study, 635 cases including 294 (46.3%) women and 341 (53.7%) men were examined. The mean age of the patients was 12.6 ± 7.1 years, and their ages ranged from 3 to 48 years. A total of 4 different histopathological diagnosis codes were entered in routine T&A samples (Table 1). There was no statistically significant difference when looking at age by gender ($p > 0.05$). Considering age in pathological diagnoses, no statistically significant difference was observed ($p > 0.05$). All tonsillectomies are bilateral (100%). As a result of histopathological evaluation; Chronic lymphoid hyperplasia (bilateral tonsillectomy + adenoidectomy) was the most common with 44.3% of the cases (Table 1). No malignancy or unexpected findings were found in any of the samples.

Histopathological images of chronic lymphoid hyperplasia and actinomyces colonization are shown in Figure 1.

Table 1. Histopathological diagnoses.

Histopathological diagnosis	n	%
Chronic lymphoid hyperplasia; Bilateral tonsillectomy + adenoidectomy	281	44.3
Chronic inflammation, lymphoid hyperplasia; Adenoidectomy	278	43.8
Actinomyces colonization; Right-left tonsillectomy	37	5.8
Chronic tonsillitis, lymphoid hyperplasia; Both tonsils, tonsillectomy	33	5.2
Malignancy	0	0
Total	635	100

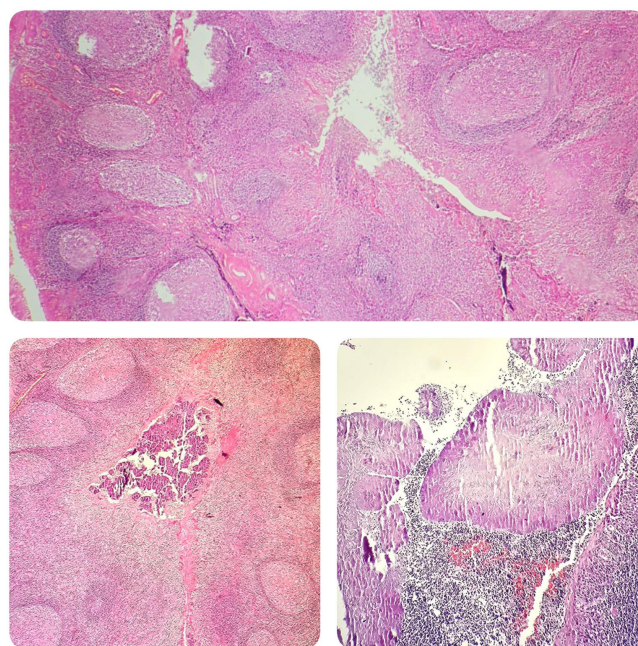


Figure 1. Top image chronic lymphoid hyperplasia (H&E x 40), Bottom image Actinomyces colony (H&E x 40 and H&E x 100, respectively) Adenotonsillar tissue with reactive changes characterized by germinal center formations with keratinized squamous epithelium, exfoliated keratin, and epithelial crypt formation lined with inflammatory cells in sections (top image H&E). Colony of actinomyces seen as large basophilic filamentous bacterial clusters (sulfur granules) on H&E stained sections of tonsil tissue (bottom picture H&E x 40 and H&E x 100, respectively).

Discussion

The histopathological demand from T&A specimens differs at various centers around the world. As in most centers in the literature, samples from all patients are routinely sent to histopathology in our clinic [6,7].

As a result of routine histopathological examination of tonsillectomy materials, the most common pathology in the literature is chronic lymphoid hyperplasia [8,9]. In the etiology of reactive lymphoid hyperplasia, recurrent acute tonsillitis attacks, subclinical resistant infections and unfinished tonsillitis treatments take the first place. The most common diagnosis among our cases was chronic lymphoid hyperplasia. The most common malignancy in the tonsil is squamous cell carcinoma, while the second most common malignancy is lymphoma. The most common tonsillar malignancy in the pediatric age group is lymphoma [10,11]. Bhargava et al. reported 2-30% colonization of Actinomyces among the factors predisposing to tonsil and adenotonsillar hypertrophy [12]. In our study, we detected actinomyces colonization in 37 cases (5.8%).

Histopathological examination of all routine T&A specimens is done to avoid missing an unexpected diagnosis, particularly malignancy [6,13]. Bizzell et al. over a 10-year period, incidental malignancy was not found in any of the 8,807 tonsillectomy specimens [14]. Yasan et al.

no occult pathology was observed, covering 1184 patients [15]. Kalcioğlu et al. when tonsillectomy specimens from the last 14 years were retrospectively scanned, no incidental malignancy was detected in any of the 2410 patients [16]. Randall et al. a retrospective PubMed review of 20 studies concluded that routine histological evaluation of adenoidectomy and tonsillectomy specimens is not necessary because of the low incidence of occult malignancies in the absence of risk factors [3].

There are studies showing that although the incidence of occult malignancy is extremely low as a result of the examination of samples taken from routine T&A samples, it is not zero. Faramarzi et al. reported that malignancy was detected incidentally in only 1 of 5058 patients in their study examining routine tonsillectomy specimens [17]. Garavello et al. reported two unexpected cases of malignancy in the evaluation of tonsil specimens from 1123 patients [6]. Williams et al. they found malignancy in 3 of 4070 cases [5]. Verma et al. they reported that they found unexpected findings in 3 cases (0.015%) in the meta-analysis study numbered 20560. Of these, 1 has been reported as glycogen storage disease and 2 as non-Hodgkin lymphoma [18].

As stated in the general literature, it can be thought that the low rate of unexpected malignancies in routine T&A materials brings unnecessary workload to the pathology departments and is not cost-effective. Sturm-O'Brien et al. stated that histological examinations of selected samples should be determined by each hospital according to hospital size, funding, pathology and input from otolaryngologists [19]. It is the necessity of examining suspicious cases, which is often recommended in the literature. The presence of certain risk factors is also important in these cases. Microscopic examination is required if there is significant tonsillar asymmetry, mucosal irregularity, immunosuppressed patient, clinical signs of malignancy (such as cervical lymphadenopathy, hoarseness, weight loss, night sweats) [9,20,21].

In our study, in which the microscopic examination results of 635 routine T&A samples were evaluated for unexpected malignancy, no malignant tumors were detected.

This study has some limitations. First, the study included pediatric patients as well as adult patients. Second, diagnostic tonsillectomies were not covered in the study, we only evaluated routine operations.

Conclusion

The necessity of microscopic histopathological examination in routine T&A specimens is still controversial. Based on our data, nothing significant was revealed by obtaining histological examination of our routine samples, and we do not consider the cost and effort of histological analysis to be justified. However, it may be useful to request pathological examination in the presence of risk factors so that physicians do not encounter problems such as the legally unexpected diagnosis of malignancy. Therefore, the histopathological request for T&A specimens should be based on specific risk factors.

Ethical approval

The study protocol was approved by the Kırıkkale University Faculty of Medicine Ethics Committee, decision number: 2023.03.06, date: 29.03.2023.

References

- Guerra MM, Garcia E, Pilan RR, et al. Antibiotic use in post-adenotonsillectomy morbidity: A randomized prospective study. *Braz J Otorhinolaryngol* 2008;74(3):337-41.
- Ikram M, Khan MA, Ahmed M, et al. The histopathology of routine tonsillectomy specimens: results of a study and review of literature. *Ear Nose Throat J*. 2000;79(11):880-2.
- Randall DA, Martin PJ, Thompson LD. Routine histologic examination is unnecessary for tonsillectomy or adenoidectomy. *Laryngoscope*. 2007;117(9):1600-4.
- Netser JC, Robinson RA, Smith RJ, Raab SS. Value-based pathology: a cost-benefit analysis of the examination of routine and nonroutine tonsil and adenoid specimens. *Am J Clin Pathol*. 1997;108(2):158-65.
- Williams MD, Brown HM. The adequacy of gross pathological examination of routine tonsils and adenoids in patients 21 years old and younger. *Hum. Pathol*. 2003;34(10):1053-7.
- Garavello W, Romagnoli M, Sordo L, et al. Incidence of unexpected malignancies in routine tonsillectomy specimens in children. *Laryngoscope*. 2004;114(6):1103-5.
- Erkiliç S, Aydın A, Koçer NE. Histological features in routine tonsillectomy specimens: the presence and the proportion of mesenchymal tissues and seromucinous glands. *J Laryngol Otol*. 2002;116(11):911-3.
- Erdag TK, Ecevit MC, Guneri EA, et al. Pathologic evaluation of routine tonsillectomy and adenoidectomy specimens in the pediatric population: is it really necessary? *Int J Pediatr Otorhinolaryngol*. 2005;69(10):1321-5.
- Alvi A, Vartanian AJ. Microscopic examination of routine tonsillectomy specimens: is it necessary? *Otolaryngol Head Neck Surg*. 1998;119(4):361-3.
- Syrjänen S. HPV infections and tonsillar carcinoma. *J Clin Pathol*. 2004;57(5):449-55.
- Chaturvedi AK, Engels EA, Anderson WF, Gillison ML. Incidence trends for human papillomavirus-related and -unrelated oral squamous cell carcinomas in the United States. *J Clin Oncol*. 2008;26(4):612-9.
- Bhargava D, Bhusnurmath B, Sundaram KR, et al. Tonsillar actinomycosis: a clinicopathological study. *Acta Trop*. 2001;80(2):163-8.
- Younis RT, Hesse SV, Anand VK. Evaluation of the utility and cost-effectiveness of obtaining histopathologic diagnosis on all routine tonsillectomy specimens. *Laryngoscope*. 2001;111(12):2166-9.
- Bizzell JG, Richter GT, Bower CM, et al. Routine pathologic examination of tonsillectomy specimens: A 10-year experience at a tertiary care children's hospital. *Int J Pediatr Otorhinolaryngol*. 2017;102:86-89.
- Yasan H, Doğru H, Candir O, et al. Incidence of unexpected pathology in routine adenoidectomy specimens. *Int J Pediatr Otorhinolaryngol*. 2006;70(1):95-8.
- Kalcioğlu MT, Gurses I, Erdem T. Is the pathological examination of routine tonsillectomy and adenoidectomy specimens necessary? A retrospective study of 559 adenoidectomy and 1132 tonsillectomy specimens and a literature review. *B-ENT*. 2010;6(2):91-5.
- Faramarzi A, Ashraf MJ, Hashemi B, et al. Histopathological screening of tonsillectomy and/or adenoidectomy specimens: a report from southern Iran. *Int J Pediatr Otorhinolaryngol*. 2009;73(11):1576-9.
- Verma SP, Stoddard T, Gonzalez-Gomez I, Koempel JA. Histologic analysis of pediatric tonsil and adenoid specimens: is it really necessary? *Int J Pediatr Otorhinolaryngol*. 2009;73(4):547-50.
- Sturm-O'Brien AK, Hicks JM, Giannoni CM, et al. Optimal utilization of histopathologic analysis of tonsil and adenoid specimens in the pediatric population. *Int J Pediatr Otorhinolaryngol*. 2010;74(2):161-3.
- Schrock A, Jakob M, Send T, et al. Histology after tonsillectomy? *HNO*. 2009;57(4):351-7.

21. Strong EB, Rubinstein B, Senders CW. Pathologic analysis of routine tonsillectomy and adenoidectomy specimens. *Otolaryngol Head Neck Surg.* 2001;125(5):473-7.