



Audiologic follow up results of child with NGLY1 deficiency

İ Ogulcan Gundogdu^{a,*}, İ Cem Yeral^a, İ Oguz Yilmaz^b, İ Yildirim Ahmet Bayazit^c

^aIstanbul University-Cerrahpasa, Faculty of Health Sciences, Department of Audiology, Istanbul, Türkiye

^bIstanbul Medipol University, Faculty of Health Sciences, Department of Audiology, Istanbul, Türkiye

^cIstanbul Medipol University, Faculty of Medicine, Department of Otolaryngology, Istanbul, Türkiye

ARTICLE INFO

Keywords:

Auditory neuropathy

Cochlear microphonics

Congenital disorder of

deglycosylation

NGLY1

Progressive hearing loss

Received: Jan 12, 2023

Accepted: May 23, 2023

Available Online: 23.06.2023

Abstract

NGLY1 deficiency is a rare in which affected individuals show developmental delay/intellectual disability in the mild to profound range, epilepsy, auditory neuropathy, abnormal liver function, complex hyperkinetic movement disorder and poor growth. Here, we present the follow-up results of hearing status in a patient with NGLY1 deficiency.

DOI:

[10.5455/annalsmedres.2023.01.022](https://doi.org/10.5455/annalsmedres.2023.01.022)



Copyright © 2023 The author(s) - Available online at www.annalsmedres.org. This is an Open Access article distributed under the terms of Creative Commons Attribution-NonCommercial-NoDerivatives 4.0 International License.

Introduction

NGLY1 encodes the enzyme N-glycanase (NGLY1), which catalyzes protein deglycosylation by cleavage of intact glycan from N-linked glycoproteins [1, 2]. NGLY1 deficiency was first published by Need et al in 2012 as the first autosomal recessive congenital disorder of N-linked deglycosylation [3]. Its prevalence is unknown [4].

Clinical features of NGLY1 deficiency contain developmental delay, hypotonia, liver dysfunction, hypertransaminasemia, small feet, peripheral neuropathy, poor or absent tear production, and abnormal involuntary movements.

In addition to these, there may be optic atrophy, corneal ulceration, scoliosis, constipation and brain imaging abnormalities [5, 6].

The information related to hearing status of the patients is limited. The follow up results of hearing loss is unclear. Herein we reported the audiological follow up results of a patient with NGLY1 deficiency for the first time.

Case Report

Informed consent was obtained from the patient's parent to share the test results and information.

The case was a 4-year-old boy who was the first child in a consanguineous marriage. He was born at 38 weeks of gestation by caesarian delivery with no known complication during the pregnancy. His birth weight was 2650 g (10th percentile), length was 45 cm (third percentile), and the head circumference was 33.5 cm (10th-50th percentiles) (Fenton curves). His family admitted to our department for the first time at the age of 4 years.

The parents suspected of hearing loss when the child was 3 years old. The parents stated that he reacted to loud sounds only, could not speak and produced meaningless sounds. He was hypotonic, and had congenital developmental delay of kidneys, poor weight gain, scoliosis, deeply set eyes, high nasal bridge, prominent nose, flat malae, small mouth, pointed chins, generalized atrophic muscles, cervical hyperlordosis, mild finger contractures, abnormal posture, epilepsy disease, involuntary movements, strabismus, ocular apraxia, and small feet, which were consistent with NGLY1 deficiency.

*Corresponding author:

Email address: ogulcan.gundgd@gmail.com (İ Ogulcan Gundogdu)

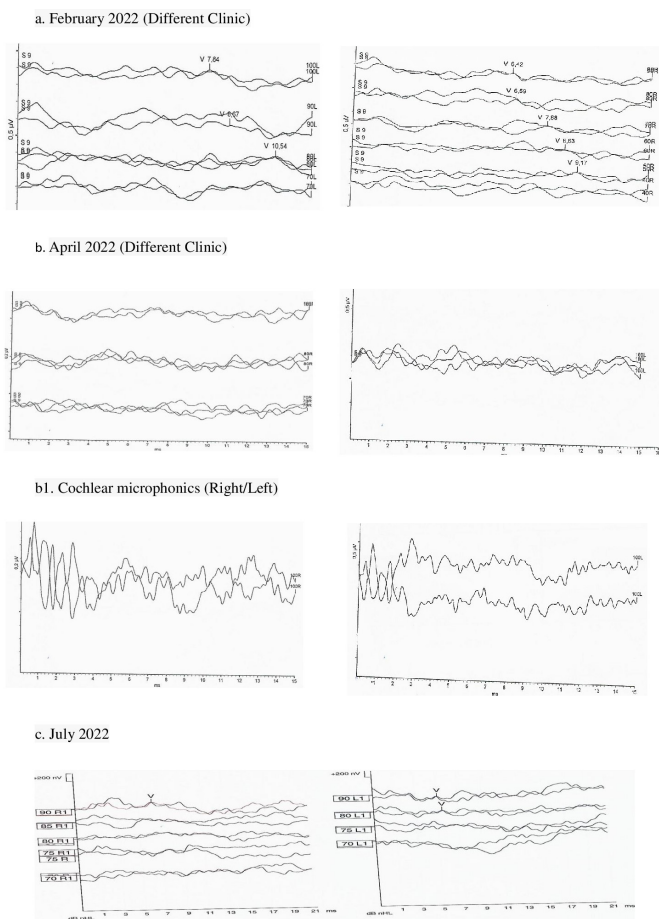


Figure 1. Wave morphologies and cochlear microphonics of the ABR tests.

In the last click ABR test performed in our clinic, wave V was observed at 80 dBnHL in the right ear and 90 dBnHL in the left ear. Also, cochlear microphonic was not obtained. While otoacoustic emissions were not obtained, no responses were observed in the ASSR test at 80 dBnHL (500,1000,2000 and 4000 Hz) (Figure 1).

Cranial MRI revealed findings consistent with enlargement of the subarachnoid space predominantly in the frontal areas bilaterally as well as triventricular hydrocephalus and thinning of the corpus callosum.

The patient had normal otoscopy and Type A tympanograms. He had four successive audiological assessments in different clinics, which showed progressive hearing loss and findings consistent with Auditory Neuropathy Spectrum Disorder (ANSD) (Table 1).

Discussion

NGLY1 deficiency is a rare congenital disorder of deglycosylation with a unique constellation of symptoms that include hypo- or alacrimalia, movement disorder, epilepsy, and severe intellectual disability [7].

Hearing loss could be seen in NGLY1 deficiency according to three case reported previously. Abudixukiuer et al., stated that I, III and V. waves of ABR could be obtained with normal interpeak latencies in 4-year-old child [5]. Lam et al. evaluated hearing in 11 children with

Table 1. Audiologic findings of the patient.

Date	ABR Threshold	TEOAE	DPOAE	
			Right	Left
February 2021	Right: 20dBnHL Left: 50 dBnHL distorted morphology	Right: + Left: -	1 kHz +	1 kHz X
			1.4 kHz +	1.4 kHz X
			2 kHz +	2 kHz X
			2.8 kHz +	2.8 kHz X
February 2022	wave V elongation and distorted morphology	Right: + Left: -	4 kHz +	4 kHz X
			1 kHz X	1 kHz X 1.5
			1.5 kHz X	kHz X 2
			2 kHz X	kHz X 3
			3 kHz +	kHz X 4
			4 kHz +	kHz X 5
			5 kHz +	kHz X 6
			6 kHz +	kHz X 8
April 2022	No response at 100dBnHL bilaterally CM: + (right)	Right: + Left: -	8 kHz +	kHz X
			1 kHz X	1 kHz X
			1.5 kHz X	1.5 kHz X
			2 kHz +	2 kHz X
			3 kHz +	3 kHz +
			4 kHz +	4 kHz X
			5 kHz +	5 kHz X
			6 kHz +	6 kHz X
July 2022	wave V elongation and distorted morphology CM:-	Right: - Left: -	8 kHz +	8 kHz X
			1 kHz X	1 kHz X
			1.4 kHz X	1.4 kHz X
			2 kHz X	2 kHz X
			3 kHz X	3 kHz X
			4 kHz X	4 kHz X
			6 kHz X	6 kHz X
			8 kHz X	8 kHz X

NGLY1 deficiency, and found hearing loss in 8 of 11 children. The most characteristics of hearing loss were the absence transmission paths of signals and/or desynchronization in the auditory brainstem or the 8th nerve [8]. They proposed that hearing loss could be caused by poor myelination [8]. It was also suggested that ANSD may be seen in the patients with NGLY-1 deficiency [9].

The previous studies reported hearing results on ABR testing. However, none of these studies had follow up results with ABR testing. In other words, the patients with NGLY-1 deficiency should be followed up for their hearing status since a hearing deterioration is possible in the follow up periods. Likewise, the child in our study was diagnosed as having hearing loss at the age of 3 years, which and presented with worsening of hearing thresholds.

Diagnosis of ANSD is based on evidence of abnormal ABRs, with a decreased or absent wave V, despite evidence of normal Outer Hair Cells (OHCs) functions, such as OAEs and/or CM [10]. It is also possible to find ANSD unilaterally or bilaterally in NGLY-1 deficiency. That is, a retrocochlear pathology may accompany to cochlear pathology in the patients. In our case, OAE responses and cochlear microphonic were not observed in last assessment. OAEs may reduce or disappear in 20 to 80% of the patients with time, particularly following hearing aid use

[10, 11]. In our case, the use of hearing aids might have caused OHC damage, and this situation can bring about disappeared OAE and CM responses. Alternatively, the outer hair cells might be damaged due to progression of cochlear pathology.

According to the MRI results, a thinning of the corpus callosum was observed in the patient. It is known that corpus callosum pathologies can affect some Central Auditory Processing (CAP) tests (Frequency Pattern Test, Duration Pattern Test) [12–14]. Therefore, it can be thought that there is a relationship between corpus callosum and CAP skills. Since thinning of the corpus callosum was observed according to MRI results, evaluation with CAP tests could provide important outcomes. However, CAP tests could not be performed due to the patient's physical and mental disabilities.

The NGLY1 deficiency may demonstrate a progressive hearing impairment. This hearing loss is attributable to cochlear and/or retrocochlear problems. It is also possible to diagnose ANSD in the patients. Hearing amplification with hearing aids seems the treatment of choice. However, regular audiological follow up is warranted due to progressive nature of the hearing loss.

References

- Dabaj I, Sudrié-Arnaud B, Lecoquierre F, et al (2021) NGLY1 Deficiency: A Rare Newly Described Condition with a Typical Presentation. *Life* (Basel, Switzerland) 11: <https://doi.org/10.3390/LIFE11030187>.
- Stuut T, Popescu O, Oviedo A (2021) N-Glycanase 1 Deficiency Is a Rare Cause of Pediatric Neurodegeneration With Neuronal Inclusions and Liver Steatosis. *Cureus* 13: <https://doi.org/10.7759/CUREUS.19126>.
- Need AC, Shashi V, Hitomi Y, et al (2012) Clinical application of exome sequencing in undiagnosed genetic conditions. *J Med Genet* 49:353–361. <https://doi.org/10.1136/JMEDGENET-2012-100819>.
- Ge H, Wu Q, Lu H, et al (2020) Two novel compound heterozygous mutations in NGLY1 as a cause of congenital disorder of deglycosylation: a case presentation. *BMC Med Genet* 21: <https://doi.org/10.1186/S12881-020-01067-1>.
- Abuduxikuer K, Zou L, Wang L, et al (2020) Novel NGLY1 gene variants in Chinese children with global developmental delay, microcephaly, hypotonia, hypertransaminasemia, alacrimia, and feeding difficulty. *J Hum Genet* 2020 654 65:387–396. <https://doi.org/10.1038/s10038-019-0719-9>.
- Kariminejad A, Shakiba M, Shams M, et al (2021) NGLY1 deficiency: Novel variants and literature review. *Eur J Med Genet* 64: <https://doi.org/10.1016/J.EJMG.2021.104146>.
- Nolan DK, Pastore MT, McBride KL (2022) Expanding the NGLY1 deficiency phenotype: Case report of an atypical patient. *Eur J Med Genet* 65:104558. <https://doi.org/10.1016/J.EJMG.2022.104558>.
- Lam C, Ferreira C, Krasnewich D, et al (2016) Prospective phenotyping of NGLY1-CDDG, the first congenital disorder of deglycosylation. *Genet Med* 2017 192 19:160–168. <https://doi.org/10.1038/gim.2016.75>.
- Lam C, Wolfe L, Need A, et al (2018) NGLY1-Related Congenital Disorder of Deglycosylation. *GeneReviews*®.
- De Siati RD, Rosenzweig F, Gersdorff G, et al (2020) Auditory Neuropathy Spectrum Disorders: From Diagnosis to Treatment: Literature Review and Case Reports. *J Clin Med* 9: <https://doi.org/10.3390/JCM9041074>.
- Shearer AE, Hansen MR (2019) Auditory synaptopathy, auditory neuropathy, and cochlear implantation. *Laryngoscope Investig Otolaryngol* 4:429–440. <https://doi.org/10.1002/LIO2.288>.
- Tuz D, Aslan F, Böke B, Yücel E (2020) Assessment of temporal processing functions in early period cochlear implantation. *Eur Arch Oto-Rhino-Laryngology* 277:1939–1947. <https://doi.org/10.1007/s00405-020-05935-7>.
- Balzan P, Tabone N (2017) Auditory Temporal Order And Resolution In Younger And Older Maltese Adults. *Malta J Heal Sci* 3–11. <https://doi.org/10.14614/AUDITEMP/8/17>.
- Delecrode, Camila Ribas Cardoso, Ana Cláudia Vieira Guida, Ana Cláudia Figueiredo Frizzo HL (2014) Pitch pattern sequence and duration pattern tests in Brazil: Literature Review. *Rev CEFAC* 16:283–293.