



# Approach to the intracranial aneurysm in patients with autosomal dominant polycystic kidney; Are current radiological screening recommendations applied?

☯Suna Sahin Ediz<sup>a,\*</sup>, ☯Umut Percem Orhan Soylemez<sup>b</sup>, ☯Basak Atalay<sup>b</sup>

<sup>a</sup>Kartal Dr. Lütfi Kırdar City Hospital, Department of Radiology, Istanbul, Türkiye

<sup>b</sup>Istanbul Medeniyet University, Prof. Dr. Süleyman Yalçın City Hospital, Department of Radiology, Istanbul, Türkiye

## Abstract

### ARTICLE INFO

#### Keywords:

Polycystic kidney  
Autosomal dominant  
Intracranial aneurysm  
Magnetic resonance angiography

Received: Dec 30, 2022

Accepted: May 15, 2023

Available Online: 26.05.2023

DOI:

[10.5455/annalsmedres.2022.12.398](https://doi.org/10.5455/annalsmedres.2022.12.398)

**Aim:** The frequency of intracranial aneurysm increases in autosomal dominant polycystic kidney disease (ADPKD); contrary to what was previously known, radiological screening for aneurysms is recommended for these patients in current studies. This study aimed to evaluate whether the recommended radiological screening is carried out in daily practice in patient follow-up, thereby creating awareness and providing an opportunity for early diagnosis and treatment.

**Materials and Methods:** 146 patients who were followed up in our hospital with the diagnosis of ADPKD between January 2016 and December 2021 were retrospectively reviewed and brain MRI, brain CT, Magnetic Resonance Angiography (MRA), Computed Tomography Angiography (CTA) scans were evaluated by two independent radiologists experienced in neuroradiology. Interobserver variability was also evaluated in terms of the presence and location of aneurysm by the kappa statistic.

**Results:** The mean age of the patients was  $57 \pm 16.19$  years. Cerebral MRA of 11 patients, CTA of one patient, brain MRI of 40 patients, brain CT of 4 patients and DSA examinations of 4 patients were determined. Aneurysm was detected in 7 patients, two of which were multiple.

**Conclusion:** The results of the study showed that periodic radiological scans of intracranial aneurysms are not performed in order to prevent subarachnoidal hemorrhage, which is the most mortal complication of ADPKD, and current approaches are not reflected in daily clinical practice.



Copyright © 2023 The author(s) - Available online at [www.annalsmedres.org](http://www.annalsmedres.org). This is an Open Access article distributed under the terms of Creative Commons Attribution-NonCommercial-NoDerivatives 4.0 International License.

## Introduction

Autosomal dominant polycystic kidney disease (ADPKD) is one of the most common hereditary disease and about 0.04-0.1% individuals in population affect with this disease [1].

ADPKD is one of the most common causes of end-stage renal disease. Vascular abnormalities are often present in patients with ADPKD, and these vascular anomalies can be seen in some regions such as aorta, coronary artery, splenic artery and popliteal artery. Apart from these vascular areas, one of the most frequently affected regions is intracranial arteries. Approximately 8-16% of patients with ADPKD may develop intracranial aneurysms [2-6]. Subarachnoid hemorrhage secondary to rupture of intracranial aneurysms is the most mortal complication of related with

ADPKD [7]. While routine screening for aneurysm was not recommended for these patients in previous years, 5-year follow-up with MR angiography is recommended for these patients in recent studies after the wide spread use of endovascular treatment and the developments in the non-contrast MR angiography technique but it is doubtful whether this is implemented or not [8]. In our country, there has been no study focused on this issue in the last 10 years. In a study conducted on 23 patients in 2007, the frequency of association between ADPKD and intracranial aneurysms was reported as 17.4% [9]. It is thought that there may be an increase in the frequency of intracranial aneurysms in ADPKD patients as a result of the increased availability and clinical use of MR angiography in recent years.

In this study, it was aimed to determine whether patients were radiologically screened for intracranial aneurysms, to determine the frequency of aneurysms in the study group,

\*Corresponding author:

Email address: [drsunasahinediz@gmail.com](mailto:drsunasahinediz@gmail.com) (☯Suna Sahin Ediz)

and to show how many patients actually missed an aneurysm diagnosis.

## Materials and Methods

This retrospective descriptive study was approved by the local Ethics Committee (Istanbul Medeniyet University Göztepe Training and Research Hospital Clinical Research Ethics Committee, Decision no: 2021/0305 Date: 16.06.2021) and conducted according to the Helsinki Declaration. Informed consent was obtained from each patient before the MRI examination.

All available radiological images of 146 patients who were followed up in our hospital with the diagnosis of ADPKD between January 2016 and December 2021 were retrospectively reviewed from Picture Archiving and Communication System (PACS). Brain MRI, brain CT, Magnetic Resonance Angiography (MRA), Computed Tomography Angiography (CTA) scans were checked. Patient images were evaluated by two radiologists with 8 and 5 years of experience in neuroradiology. The presence of aneurysm, in the presence the number, size and location of the aneurysm were noted. Interobserver variability was also evaluated in terms of the presence and location of aneurysm. Subarachnoid hemorrhage and surgical history were investigated in all patients.

In the study design; no subgroups or randomization or sampling were applied for the study. All the current ADPKD patients in PACS were evaluated retrospectively. CT, CTA, MRA, and DSA of ADPKD patients were evaluated for intracranial aneurysm and subarachnoid hemorrhage. The primary endpoint of the study was to determine the frequency of intracranial aneurysms in patients with ADPKD, and the secondary endpoint to evaluate the latest status/need in population screening.

Data analyses were performed using SPSS Statistics 20.0 software (SPSS Inc., Chicago, IL, USA). Quantitative variables were evaluated as ratios mean,  $\pm$  Standard deviation, qualitative variables were evaluated as ratios. The kappa statistic was used to test interrater reliability.

To discuss the our article; original articles and meta-analyses in the literature about intracranial aneurysm increases in autosomal dominant polycystic kidney disease were scanned from the PubMed database and evaluated.

## Results

One hundred and forty-six patients (81 males and 65 females) were included in the study. The mean age of the patients was  $57 \pm 16.19$  years. Cerebral MRA of 11 patients,

**Table 1.** Number of cranial imaging performed on patients.

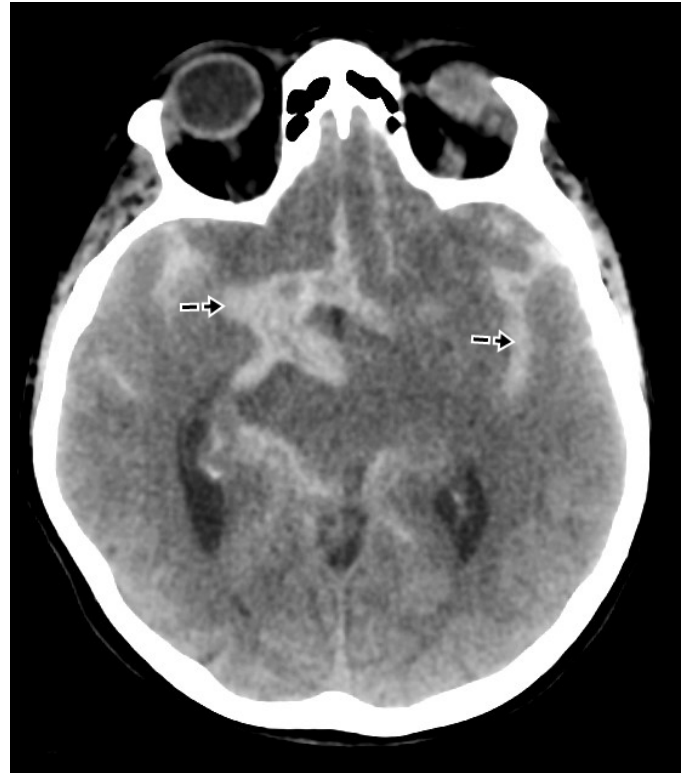	CT	MRI	CTA	MRA	DSA
Yes (number)	40	37	1	11	4
No (number)	106	109	145	135	142

CT: Computed Tomography, MRI: Magnetic Resonance Imaging, CTA: Computed Tomography Angiography, MRA: Magnetic Resonance Angiography, DSA: Digital Subtraction Angiography.

**Table 2.** Demographic characteristics of patients.

	Mean $\pm$ SD
Age	57 $\pm$ 16.19
	n (%)
Gender (M/F)	81 (55.5%) / 65 (44.5 %)
Hemodialysis treatment	9 (6.1%)
Subarachnoid hemorrhage	2 (1.3%)
Aneurysm	9 (6.1%)

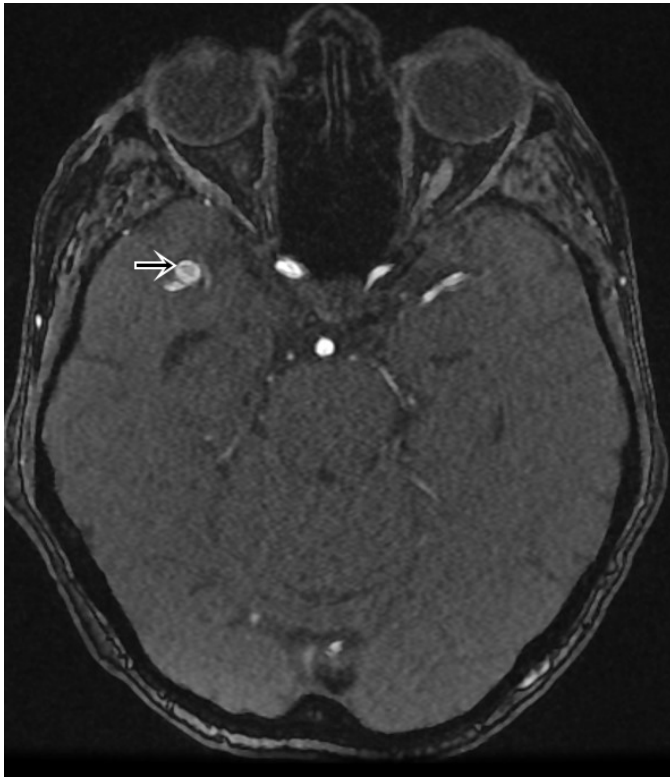SD: Standard Deviation.



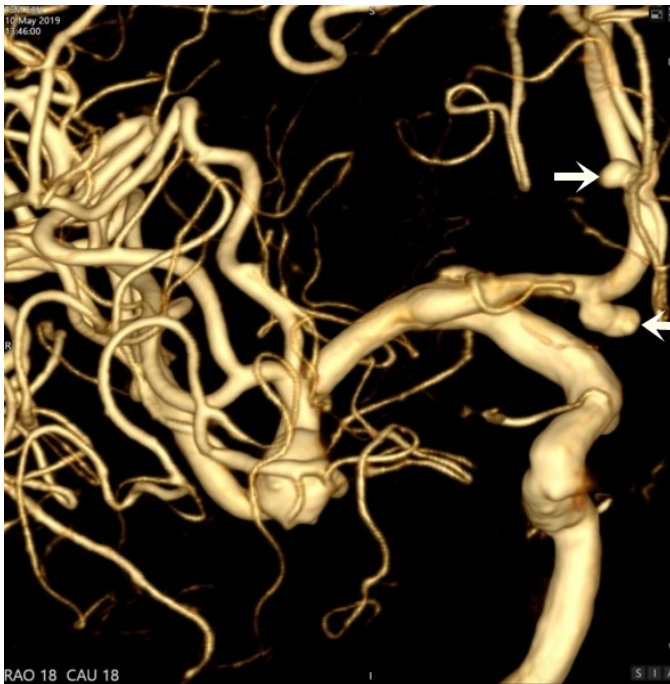
**Figure 1.** Subarachnoid hemorrhage secondary to intracranial aneurysm on CT image.

CTA of one patient, brain MRI of 40 patients, brain CT of 4 patients and DSA examinations of 4 patients were determined (Table 1). Aneurysm was detected in 7 patients; there were multiple aneurysms in 2 patients. Subarachnoid hemorrhage was detected in 2 patients, one of which was treated endovascularly and one of which was treated surgically (Figure 1) (Table 2). 2 Common carotid artery, 2 anterior communicating artery, 4 middle cerebral artery and 1 anterior cerebral artery aneurysms were detected (Figure 2 and 3). Aneurysm sizes ranged from 1.5 to 8 mm. There was near perfect agreement among the observers ( $\kappa=0.892$ ).

Nine patients were undergoing hemodialysis treatment due to end-stage renal disease. In terms of intracranial aneurysm, 2 patients had imaging with cranial MRI, and aneurysm with subarachnoid hemorrhage was detected both of them.



**Figure 2.** MRA image showing multiple aneurysms in ICA and ACA.



**Figure 3.** Right MCA aneurysm on MRA image.

## Discussion

Aneurysm was detected in 4.7% of the patient population screened in this study. This rate is lower than that reported in the literature. This is because the patients did not undergo brain imaging.

Autosomal dominant polycystic kidney disease is associated with vascular abnormalities, and the incidence of in-

tracranial aneurysm in these patients is increased compared to the general population. There is no definite information yet regarding the cause of the increased frequency of aneurysms in ADPKD patients. It has been reported that the abnormal production of polycystin 1 and 2 proteins are effective [2]. In a study by Lee et al., it was reported that patients' age, female sex, dolichoectasia, and mitral inflow DT were positively associated with high-risk aneurysms [3]. It has been reported that the incidence of aneurysms in ADPKD is 9%, and the probability of rupture is five times higher than in the normal population in presymptomatic scans [10]. In our study, the rate was 4.7% with 7 aneurysms in 146 patients, indicating that we were aware of only half of the patients with aneurysms. Moreover, some of these patients (28.5%) could be diagnosed because they bled. When available clinical information and radiological images were scanned, 8.2% of the patients were evaluated for the presence of intracranial aneurysm. Unfortunately, the rates reported in studies conducted in our country are not compatible with the literature due to the low number of patients. It seems that we are unaware of the aneurysm of 4% of patients at best and 10% of patients at worst. In the current study among patients with ADPKD, the prevalence of intracranial aneurysms and aneurysmal SAH was 16 and 1.2%, respectively. Two of the patients developed subarachnoid hemorrhage in our study population. Aneurysms are considered to be one of the most mortal complications of ADPKD. According to the results of the study by Li or Kataoka et al., Patients with low GCS score or worse renal function have a poor prognosis, which can lead to disability and even death [11, 12]. In our study, there was a parallelism between the degree of renal failure and the development of subarachnoid hemorrhage. However, in a study by Sorenson et al., they reported that aneurysm structures are relatively smaller than the general population and have a more fusiform structure than the saccular form, and they reported that the risk of rupture may not be as much as feared [13]. In line with this the aneurysm sizes ranged from 1.5 to 8 mm in our study population. The structure and location of the artery are the determining factors for the development of subarachnoid hemorrhage. In a study conducted in 2023, it was stated that the incidence of aneurysm development increased in anteriorly located vessels with increased caliber [14]. In our study, the aneurysm location was anterior in both patients, which was found to be consistent with the meta-analysis result.

In a meta-analysis including 15 studies published in 2017, it was stated that routine screening was not recommended for patients with ADPKD [15]. However, in recent studies, patients with aneurysms could follow-up five-year with MR angiography and endovascular aneurysm treatment were shown to be cost effective, and annual MR angiography screening was recommended to these patients [8, 16]. The scarcity of screening in current study shows that this is not reflected in daily practice and that old approaches are valid.

The limitations of the study include the possibility of not being able to reach some tests during the retrospective scan and the possibility of not detecting aneurysm in patients with conventional MR-CT examinations.

## Conclusion

Renal functions are closely followed in ADPKD, but the complication, which is the most common cause of mortality, is ignored. Radiologists who perform endovascular treatment and evaluate angiography have a greater share in this regard. For this reason, it is necessary to pioneer the use of contrast-free MR angiography.

## Acknowledgments

We would like to thank all the staff of the radiology department who contributed to the realization of the research.

## Ethical approval

This retrospective descriptive study was approved by the local Ethics Committee (Istanbul Medeniyet University Göztepe Training and Research Hospital Clinical Research Ethics Committee, Decision no: 2021/0305 Date: 16.06.2021).

## Conflict of interest

There is no conflict of interest.

## Financial disclosure

No financial support

## References

- Chebib FT, Torres VE. Autosomal Dominant Polycystic Kidney Disease: Core Curriculum 2016. *Am J Kidney Dis.* 2016;67(5):792-810.
- Cagnazzo F, Gambacciani C, Morganti R, Perrini P. Intracranial aneurysms in patients with autosomal dominant polycystic kidney disease: prevalence, risk of rupture, and management. A systematic review. *Acta Neurochir (Wien).* 2017;159(5):811-21.
- Irazabal MV, Huston J, 3rd, Kubly V, Rossetti S, Sundsbak JL, Hogan MC, et al. Extended follow-up of unruptured intracranial aneurysms detected by presymptomatic screening in patients with autosomal dominant polycystic kidney disease. *Clin J Am Soc Nephrol.* 2011;6(6):1274-85.
- Lee CH, Ahn C, Ryu H, Kang HS, Jeong SK, Jung KH. Clinical Factors Associated with the Risk of Intracranial Aneurysm Rupture in Autosomal Dominant Polycystic Kidney Disease. *Cerebrovasc Dis.* 2021;50(3):339-46.
- Perrone RD, Malek AM, Watnick T. Vascular complications in autosomal dominant polycystic kidney disease. *Nat Rev Nephrol.* 2015;11(10):589-98.
- Xu HW, Yu SQ, Mei CL, Li MH. Screening for intracranial aneurysm in 355 patients with autosomal-dominant polycystic kidney disease. *Stroke.* 2011;42(1):204-6.
- Corneec-Le Gall E, Alam A, Perrone RD. Autosomal dominant polycystic kidney disease. *Lancet.* 2019;393(10174):919-35.
- Malhotra A, Wu X, Matouk CC, Forman HP, Gandhi D, Sanelli P. MR Angiography Screening and Surveillance for Intracranial Aneurysms in Autosomal Dominant Polycystic Kidney Disease: A Cost-effectiveness Analysis. *Radiology.* 2019;291(2):400-8.
- Dervisoglu E, Yilmaz A, Sengul E, Anik Y. The Frequency of Intracranial Aneurysms in Autosomal Dominant Polycystic Kidney Disease. *Turkish J Nephrol.* 2007;16:140-3.
- Sanchis IM, Shukoor S, Irazabal MV, Madsen CD, Chebib FT, Hogan MC, et al. Presymptomatic Screening for Intracranial Aneurysms in Patients with Autosomal Dominant Polycystic Kidney Disease. *Clin J Am Soc Nephrol.* 2019;14(8):1151-60.
- Li Z, Luo S, Wang Y, Zhou Y, Xu S, Zuo K, et al. Clinical features and prognosis of autosomal dominant polycystic kidney disease with cerebrovascular complications. *Clin Nephrol.* 2023;99(5):237-46.
- Kataoka H, Akagawa H, Yoshida R, Iwasa N, Ushio Y, Akihisa T, et al. Impact of kidney function and kidney volume on intracranial aneurysms in patients with autosomal dominant polycystic kidney disease. *Sci Rep.* 2022;12(1):18056.
- Sorenson TJ, Brinjikji W, Jagani M, Wald JT, Lanzino G. Aneurysm morphology in patients with autosomal dominant polycystic kidney disease: A case-control study. *J Clin Neurosci.* 2019;69:220-3.
- Haemmerli J, Morel S, Georges M, Haidar F, Chebib FT, Morita A, et al. Characteristics and distribution of intracranial aneurysms in Autosomal Dominant Polycystic Kidney Disease patients compared to the general population: a meta-analysis. *Kidney360.* 2023.
- Zhou Z, Xu Y, Delcourt C, Shan J, Li Q, Xu J, et al. Is Regular Screening for Intracranial Aneurysm Necessary in Patients with Autosomal Dominant Polycystic Kidney Disease? A Systematic Review and Meta-analysis. *Cerebrovasc Dis.* 2017;44(1-2):75-82.
- Flahault A, Trystram D, Nataf F, Fouchard M, Knebelmann B, Grunfeld JP, et al. Screening for intracranial aneurysms in autosomal dominant polycystic kidney disease is cost-effective. *Kidney Int.* 2018;93(3):716-26.