



What the twenty-year series in children with disorders of sex development tells us?

Bengu Macit^{a,*}, Aysehan Akinci^b, Mehmet Demircan^c, Kubilay Gurunluoglu^c, Ahmet Sigirci^d

^aInonu University, Faculty of Medicine, Department of Pediatric Hematology and Oncology, Malatya, Türkiye

^bInonu University, Faculty of Medicine, Department of Pediatric Endocrinology, Malatya, Türkiye

^cInonu University, Faculty of Medicine, Department of Pediatric Surgery, Malatya, Türkiye

^dInonu University, Faculty of Medicine, Department of Radiology, Malatya, Türkiye

ARTICLE INFO

Keywords:

Sex
Development
Pediatrics
Endocrine

Received: Mar 26, 2022

Accepted: Sep 28, 2022

Available Online: 22.10.2022

DOI:

[10.5455/annalsmedres.2022.03.110](https://doi.org/10.5455/annalsmedres.2022.03.110)

Abstract

Aim: Although Disorders of sex development (DSD) are not a common pathology, they are destructive for individuals, families and society and require serious effort for the health personnel who treat and follow these patients. This study aims to evaluate the clinical, laboratory, genetic and radiological findings of our twenty-year series with DSD patients and to reveal remarkable issues.

Materials and Methods: This retrospective study and DSD patients who were detected were divided into three groups according to the Chicago classification. In this study, there were a total of 92 patients with DSD in the hospital records from 1999 to 2019 and all the data obtained were evaluated descriptive statistical. The distributions of the qualitative data were expressed by count and percentage in frequency tables.

Results: The mean presentation age of 92 patients with DSD was 9.45 ± 6.81 . These patients were admitted due to suspicious genitalia. Twenty-five out of all patients (27.1%) had sex chromosome DSD patients. The mean presentation age of these patients was 15 ± 0.83 years. We examined the etiologies of thirty-four 46 XY DSD patients. Totally 12 patients had androgen-insensitive syndrome. In our study we found thirty-three, 46 XX karyotypes DSD patients. Twenty seven out of the patients in the same group were found to have congenital adrenal hyperplasia (CAH).

Conclusion: The differences in DSD patients maybe are not noticed by both the family and the doctors they first consult. DSD patients may be diagnosed late and genetic analysis may be delayed because the first admission to these patients is delayed. These patients maybe are raised in different genders until they are diagnosed by their specialists. The delay in the diagnosis of the patient may also affect the content of the surgical procedure performed. DSD should be considered in every child who presents with suspicious genital anomalies.



Copyright © 2022 The author(s) - Available online at www.annalsmedres.org. This is an Open Access article distributed under the terms of Creative Commons Attribution-NonCommercial-NoDerivatives 4.0 International License.

Introduction

Disorders of sex development (DSD) is very important condition as well as for individuals, for families and community [1]. DSD occurs when there is a discrepancy between the genetic sex of the individual and the genital and gonadal sex development [2]. Genital anomaly occurs at 1 in 4,500 births [1].

If these patients are not provided with an appropriate approach by a multidisciplinary team in a correct and timely manner, they will have devastating effects on the individual, as well as the family and society [1].

The DSD is divided into three categories [3]. The first one

is that the genetic females are masculinized by excessive androgenic steroid production [3]. In the second category there is a lack of androgens production or effects of androgens in genetically males [3]. In the third category of males or females, due to genetic mutation on sex chromosome, incomplete or asymmetric gonadal differentiation occurs [3].

The management of children with DSD is still going to be controversial at some points, such as the time of definitive surgery [1, 3].

This study intends to analyze the clinical, laboratory, genetic and radiological findings of our twenty-year series with DSD patients and to share our experiences by comparing the literature

*Corresponding author:

Email address: benguhogsmade@hotmail.com (Bengu Macit)

Materials and Methods

This retrospective study commenced after approval by the Ethics Committee of Scientific Research and Publications of Inonu University (No: 2018/9-20). The records of all pediatric patients < 18 years of age who treatment and followed in our center from January 1999 to October 2019 due to DSD were examined. The inclusion criteria were:

1. A patient being diagnosed with DSD;
2. < 18 years of age;
3. Accessible clinic, laboratory, genetic, radiological findings and all other relevant information.

We created the sample size of our study by examining all patients enrolled within the 20-year period according to the inclusion criteria. The algorithm used for the determination of DSD patients is Figure 1 shown in the flowchart. The DSD patients who were detected were divided into three groups according to the Chicago classification [4]. We have found that after the first application, DSD patients were assessed by the multidisciplinary team. The members of this multidisciplinary team consisted of a pediatric urologist, a pediatric surgeon, a pediatric endocrinologist, a neonatologist, a pediatric radiologist, a pathologists and a pediatric psychiatrist. This multidisciplinary team's approach to a DSD patient is Figure 2 is shown. After the first appointment of a child sustained with DSD, meticulous and detailed phenotypic Figure (3-5), laboratory, radiologic, genetic evaluations were performed. If needed, it was evaluated as a result of laparoscopic gonad biopsies, and finally the multidisciplinary team decided on the gender of the patient to be admitted, in light of the findings obtained, with contribution of the patients' family. If the patient's phenotype is not appropriate, reconstructive surgery was performed according to determined gender. Then, the patient was followed up at regular intervals.

The main purposes of the surgical procedure in DSD patients were erectile, orgasmic functions as well as obtaining reproduction and continence. In the surgical procedure, it was important to have better functional results than cosmetic results. For this purpose, according to each patient type, according to male and male genitalia, laparotomy for diagnostic purposes, cystoscopy, separation of vagina and urethra for surgical reconstruction, vaginoplasty, clitoroplasty, perineoplasty, urethral reconstruction, falloplasty, vaginal dilatation, penile reconstruction, removal of müllerian residues were performed one or more of the procedures. When necessary for genitoplasty, a skin flap was usually used. Byars-1 and 2 techniques were frequently preferred for correction of hypospadias. Diagnostic surgical procedures and removal of müllerian residues were performed in the 1-2 age period, while reconstructive procedures were performed during puberty period. A female patient who applied at the age of 11 was diagnosed with complete absence of the vagina (also known as Mayer-Rokitansky syndrome). This patient underwent bowel vaginoplasty surgery (from the ileum). She recovered without complications. In this study, there were a total of 91 patients with DSD in the hospital records from 1999 to 2019 and all the data obtained were analyzed statistically.

Statistical analysis

The distributions of the qualitative data were expressed by count and percentage in frequency tables. Quantitative data is shown with an average \pm standard deviation.

Results

The mean presentation age of 92 patients with DSD was 9.45 ± 6.81 . The diagnostic and etiological distribution of DSD patients is shown in Tables 1 and 2 respectively.

Patients with sex chromosome DSD

Twenty-five out of all patients (27.1%) had sex chromosome DSD patients. The mean presentation age of these patients was 15 ± 0.83 years. When the etiologies of these patients were investigated, 22 (88%) of them were classic Turner's syndrome and variants, 2 (8%) of them were Klinefelter syndrome, and 1 (4%) mixed gonadal dysgenesis was found. Two patients with Klinefelter syndrome were admitted due to a complaint of gynecomastia. All 17 patients with classic Turner syndrome had specific dysmorphic features such as webbing of the neck, cubitus valgus and lymphedema. A patient with mixed gonadal dysgenesis was admitted because of the abnormal appearance of the external genital structure, although scrotum with testicles was present.

Patients with 46 XY karyotypes DSD

We examined the etiologies of thirty-four 46 XY DSD patients and 14 of them were mixed gonadal dysgenesis, 12 of them had *androgen-insensitivity syndrome*, 8 of them had androgen synthesis defects. Two of the 12 patients with *androgen insensitivity syndrome* had complete insensitivity, and 10 had incomplete insensitivity. Patients with androgen synthesis defects had *17 α -hydroxylase deficiency*

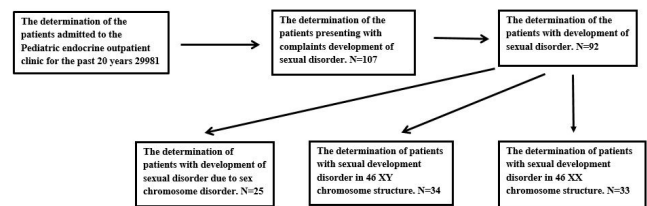


Figure 1. Flow chart showing the algorithm used to determination of the children with the disorder of sex development.

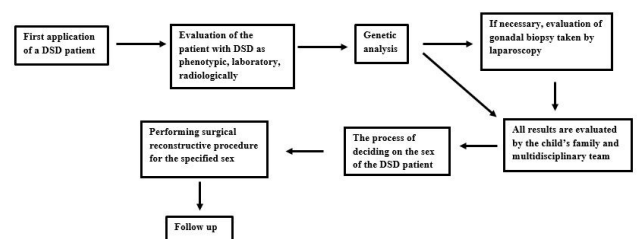


Figure 2. Flow chart of the multidisciplinary team's approach to children with disorder of sex development.

Table 1. Chromosome analysis and diagnosis age distribution of DSD patients.

Patients age at diagnosis	0-1 month	1month-1year	1-5 year	5-13 year	13-17 year	Total
Sex chromosome DSD	-	1	-	17	7	25
46,XY DSD	1	15	1	3	14	34
46,XX DSD	-	10	7	11	5	33

Table 2. Distribution of patients according to the DSD classification recommended by the Chicago consensus.

DSD classification	Number of patients
Sex chromosome DSD	
45,X (<i>Turner syndrome and variants</i>)	22
47,XXY (<i>Klinefelter syndrome and variants</i>)	2
45,X/46,XY (<i>mixed gonadaldysgenesis, ovotesticular DSD</i>)	17
46,XX/46,XY (<i>chimeric,ovotesticular DSD</i>)	
46,XY DSD	
Disorders of gonadal (testicular) development	
<i>Complete gonadal dysgenesis (Swyer syndrome)</i>	2
<i>Partial gonadal dysgenesis</i>	10
<i>Gonadal regression</i>	
<i>Ovotesticular DSD</i>	
Disorders in androgen synthesis or action	
<i>Androgen biosynthesis defect (17-hydroxysteroid dehydrogenase deficiency, 5α-reductasedeficiency)</i>	8
<i>Defect in androgen action (CAIS, PAIS)</i>	
<i>LH receptor defects (Leydig cell hypoplasia)</i>	
<i>Disorders of AMH and AMH receptor (persistent müllerian duct syndrome)</i>	
<i>Other (severe hypospadias, cloacalextrrophy)</i>	
46,XX DSD	
Disorders of gonadal (ovarian) development	
<i>Ovotesticular DSD</i>	
<i>Testicular DSD (SRY+, dup SOX9)</i>	
<i>Gonadal dysgenesis</i>	
Androgen excess	
<i>Fetal (21- or 11-hydroxylase deficiency)</i>	27
<i>Fetoplacental (aromatase deficiency, POR)</i>	
<i>Maternal (luteoma, exogenous)</i>	
<i>Other (cloacalextrrophy, MURCS, MRKH)</i>	4

DSD, disorder of sex development; CAIS, complete androgen insensitivity syndrome; PAIS, partial androgen insensitivity syndrome; LH, luteinizing hormone; AMH, anti-müllerian hormone; POR, cytochrome P450 oxidoreductase; MURCS, müllerian duct aplasia; renal aplasia, and cervicothoracic somite dysplasia, MRKH; Mayer-Rokitansky-Küster-Hauser syndrome.

in 3 patients, 5- α reductase deficiency in 4 patients, and Lipoid CAH (CAH) in 1 patient.

In all patients diagnosed with gonadal dysgenesis, it was detected that the uterus was present in the pelvis magnetic resonance images (MRI) (Figure 6). In the MRI images of only 3 of the 46 XY DSD patients diagnosed with gonadal dysgenesis, ovarian tissue was found.

Laparoscopy was performed on all 46 XY DSD patients diagnosed with gonadal dysgenesis, and all had intra-abdominal gonads (Figure 7). When histopathological examination was performed by taking gonadal biopsy of these some patients, ovarian-testicular tissue was found (Figure 8).

Totally, 12 patients had androgen-insensitive syndrome. These patients were admitted due to suspicious genitalia.

In 10 of these patients, complete androgen-insensitive syndrome was found. The increase in testosterone level was [196.8 \pm 136.7 ng/dL] found in patients with complete androgen-insensitive syndrome. The increase in the level of dihydrotestosterone was [98.7 \pm 106.5 ng/dL] found. In the genetic analysis of these patients, the AR gene mutation was found in two patients. Incomplete androgen-insensitive syndrome was found in two of 12 patients. The gender identity of these patients was female.

Three patients with 17 α -hydroxylase deficiency had hypokalemia, only 1 had hypertension.

A Lipoid CAH patient was admitted for the first time due to convulsion and the cause of convulsion was diagnosed while investigating. In this patient's physical examination, genital hyperpigmentation was seen and also hypona-

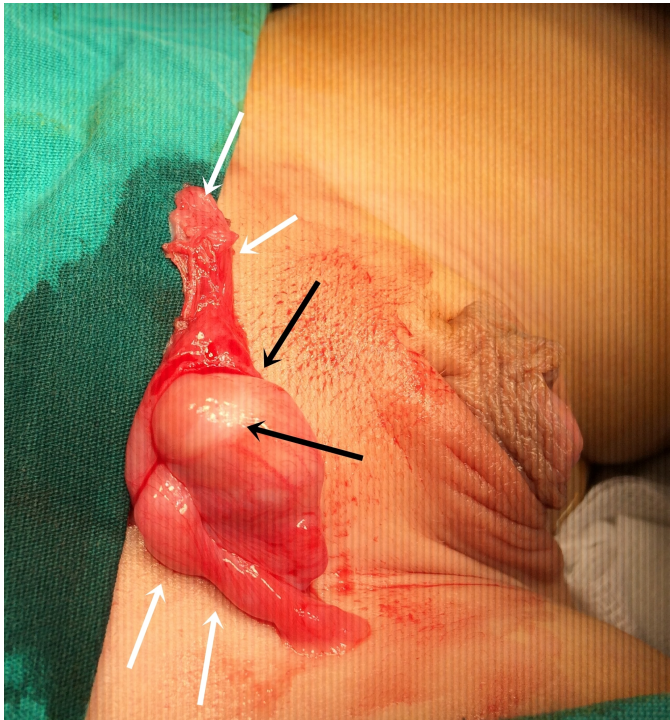


Figure 3. Inguinal exploration image of a 2 year-old boy with partial androgen insensitivity. Views of right gonad (black arrows), and tuba uterine and fimbria (white arrows).

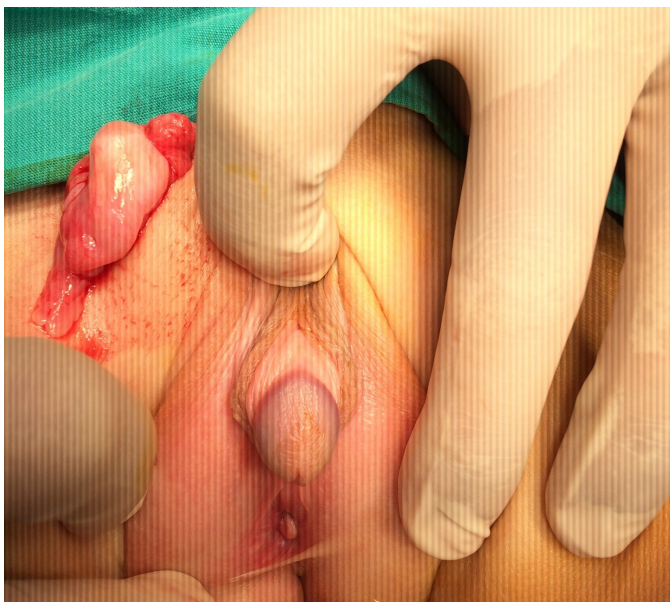

Figure 4. Appearance of the patient's external genitalia in Figure 3.

tremia and hypoglycemia were found in blood biochemistry. The Adrenocorticotrophic hormone value was above 1250 pg/ml in the blood at the moment of admission of this patient, and the level of cortisol was 1.21 µg/dl. Bilateral adrenal hyperplasia was detected in abdominal MRI. Genetic analysis of this patient was found mutation in the gene coding StAR protein.

The deficiency of 5α-reductase was found in 4 patients.

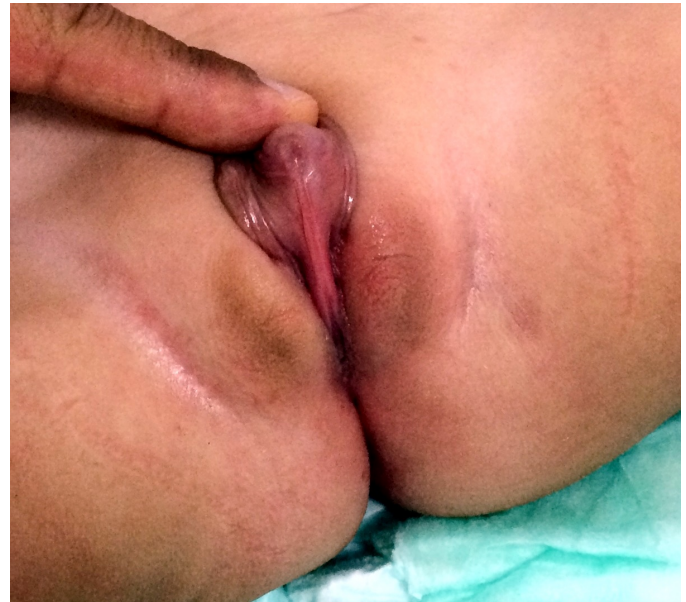

Figure 5. Appearance of the external genitalia which a 2-year-old girl with congenital adrenal hyperplasia.

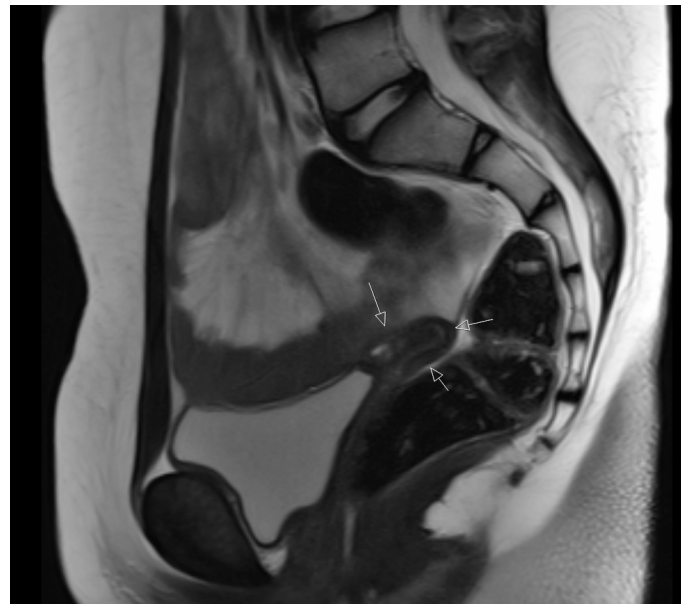


Figure 6. Pelvic MRI image of a 15-year-old patient with mixed gonadal dysgenesis. The patient's chromosome analysis results in 46 XY karyotype. The MRI shows the uterus (white arrows).

The first applications' causes of these patients were suspected genitalia. The blood hormone analysis of these patients was performed and the increase in the level of dihydrotestosterone and testosterone were detected respectively [16 ± 13.3], [685 ± 328.7]. Only 1 of these patients was genetically analyzed and heterozygote mutation was detected in Exon1 and Exon 4.

Patients with 46 XX karyotypes DSD

In our study we found 33, 46 XX karyotypes DSD patients. Two of these patients were mixed gonadal dysgenesis. These two patients admitted to the first hospital with

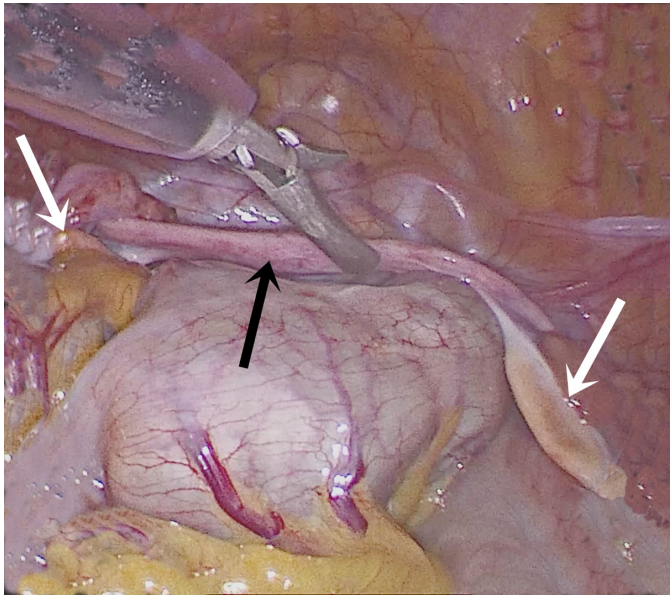


Figure 7. Laparoscopic image of a 16-year-old mixed gonadal dysgenesis patient. The patient's chromosome analysis results in 46 XY. The image shows rudimentary uterus (black arrow) and streak gonads (white arrows).

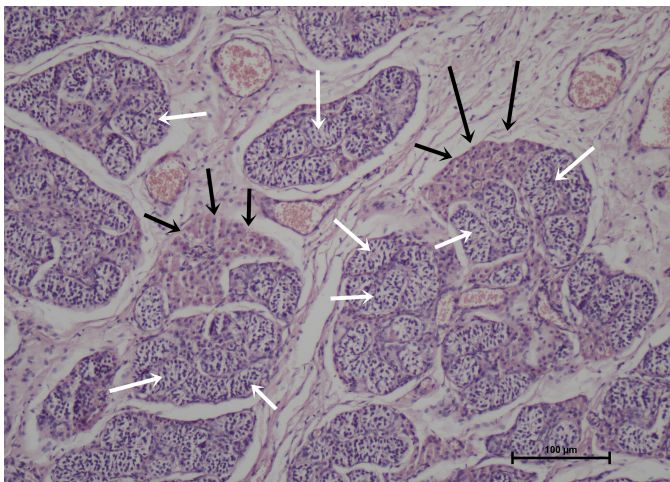


Figure 8. Histopathological image of gonadal tissue taken by laparoscopic biopsy in a 16-year-old patient with mixed gonadal dysgenesis (hematoxylin eosin examination). The patient's chromosome analysis results in 46 XY. Leydig cell groups with eosinophilic cytoplasm (black arrows). Immature seminiferous tubules (white arrows) consisting of Sertoli cells in groups surrounded by basal membrane.

complaints that the breast formation was delayed. The uterus was found when the pelvic MR images of these patients were examined.

Twenty-seven out of the patients in the same group were found to have CAH. Seventeen of these patients were found to have 21-hydroxylase enzyme deficiency, 10 of which were 11- β hydroxylase enzyme deficiency.

All patients with a 21-hydroxylase enzyme deficiency were admitted to the hospital due to suspicious genitalia. 11 of these patients were found to have a consanguineous mar-

riage between parents. 8 of these patients were found a similar history of disease in the family. In 8 of these patients, hyperpigmentation was found in the genital area. During the first hospital admission to these patients, the mean blood levels adrenocorticotrophic hormone, [223 ± 272.5 pg/ml]; the average blood cortisol, [7.4 ± 3.6 μ g/dl]; and the mean blood total testosterone, [457.2 ± 567.7 ng/dl] was found.

Genetic mutation was found in all patients with a 21-hydroxylase enzyme deficiency. A loss of salt was found in 6 patients, and 11 had a simple virilizing 21-hydroxylase enzyme deficiency. Fourteen patients had female gender identity, 3 of them had male gender identity. Medical treatment was given to all patients in this group. 2 patients received only hydrocortisone treatment, 15 patients were treated with both hydrocortisone and Fludrocortisone. 12 of 17 patients underwent clitoroplasty + vaginoplasty procedure.

A total of 11- β hydroxylase enzyme deficiency was found in 10 patients. 5 of these patients were found to have a consanguineous marriage between parents. 4 of these patients were found a similar history of disease in the family. Only 1 patient was found hypertension and was normotensive with medical treatment. During the first hospital admission to these patients was the mean blood Adrenocorticotrophic hormone level: [710.4 ± 580.6 pg/ml], the average blood Cortisol level [2 ± 0.9 μ g/dl], the mean blood Total testosterone level: [138 ± 60.4 ng/dl] was found. During the first hospital admission to these patients was the mean blood 11 deoxycorticosterone level: [48.5 ± 35.4 ng/ml], the average blood Aldosterone level: [282 ± 271.5 ng/ml], Plasma renin activity: [72.9 ± 65 ng/ml/hour] was found.

Five out of the 10 patients with 11 β hydroxylase enzyme deficiency had male gender identity, and 5 had female gender identity. Genetic mutation was found in all of these patients. Four out of these patients underwent clitoroplasty + vaginoplasty operation.

Müllerian agenesis was found in 3 patients. These patients first admitted to the hospital due to primary amenorrhea. Abdominal MRI of these patients were evaluated and the uterus and gonads were not detected.

Discussion

Many studies have been conducted on DSD diagnosis, management, follow-up, health status and approach.

The presence of genetic anomalies in patients with DSD has been investigated in many studies [5-11]. These studies point to the importance of genetic disorders at the root of DSD. As a result of these studies, a genetic disorder panel has been reported to be investigated in every patient with DSD [8]. It has been suggested that the outcome of the genetic disorder research may help to predict the prognosis of the patient [7]. In their work at Nixon et al. they investigated the prevalence of endocrine and genetic anomalies in boys with DSD patients [5]. They only conducted this study on DSD patients with 46 XY karyotypes [5]. They evaluated a total of 122 patients [5]. They did genetic analysis in terms of genetic anomalies associated with DSD [5]. They found endocrine hormonal disorders in 28 of these patients [5]. They found gonadal developmental disorders in 19 patients [5]. They found

Copy Number Variants (CNVs) in 13 patients [5]. They found a single gene anomaly in nine patients [5]. Hughes et al. described how a newborn with abnormal genitalia should be evaluated hormonally and genetically, as algorithmic [6]. Almoidah et al. claimed that finding the genetic cause of this disease is very important in estimating the prognosis of the disease in a DSD patient [7]. Eggers et al. found 28 diagnostic genes that emphasized the genetic spectrum of DSD disease in their largest international cohort study [8]. They found 93 previously undeclared DSD gene variants as a result of their research in 326 patients [8]. They found a possible genetic diagnosis in 43% of patients with 46 XY DSD [8]. In our study, we found that 33 of our patients had genetic anomalies. In our study, we found that not all of our patients were investigated for genetic anomalies. Of our patients with genetic anomalies, 17 were 21-hydroxylase enzyme deficiencies, 10 were 11- β hydroxylase enzyme deficiency, 2 were Androgen insensitivity syndrome, 2 of them 17- α hydroxylase enzyme deficiency 1 was 5- α reductase enzyme deficiency and 1 was Lipoid CAH.

Surgical management of patients with DSD has always been difficult [12]. It has some technical difficulties and it is difficult to decide the right technique [12]. There is no complete consensus yet on the type and timing of surgery in patients with DSD [13]. However, many experts agree that surgical decisions should be taken with a multidisciplinary approach [13]. In patients with DSD, it is very important to know the surgical techniques applied and the results of these techniques [14]. Nasir et al investigated 50 DSD patients in Nigeria [15]. They investigated their patients in terms of, clinical manifestation, surgical intervention and age at initial presentation [15]. The number of DSD patients included in our study was 91. The median age of application in their study is 20 months (IQR, 21 days, 7 years) [15]. In our study, we found that the average initial application age was 9.45 ± 6.81 . They diagnosed five patients in the neonatal period [15]. We found that two of our patients were diagnosed in the neonatal period, but anybody was not diagnosed in the prenatal period. We believe that the cause of this low number of patients diagnosed early is due to most patients in this group were born with normal births in rural countries of the country, some of which were inadequately evaluated during childbirth. They conducted karyotype analysis of only 13 patients due to logistical insufficiency in their study. As a result of this analysis, they found that 10 patients had 46 XX and 3 patients had 46 XY. We found that all the patients in our study had karyotype analysis. We found that 34 of our patients had 46, XY, 32 had 46, XX and 25 had sex chromosome disorders. In their study they found performed that 7 patients had gonadal excision, 5 patients had serial vaginal dilatation and clitoroplasty with vaginoplasty, 1 patient had clitoroplasty, 1 patient had excision of Müllerian structures (uterus, bilateral gonads), 2 patients had urethroplasty. We found that a total of 47 of our patients were operated on. In our study we found as of performed that 34 patients had biopsy and laparotomy, 34 patients had excision of Müllerian structures, 13 patients had clitoroplasty, 3 patients had clitoroplasty with vaginoplasty, 6 patients had serial vaginal dilatation. We

performed bowel vaginoplasty surgery (from the ileum) on a patient with complete absence of the vagina. In a recent study, Slowikowska et al investigated the results of fertility in individuals with DSD in different forms [16]. They evaluated 1040 patients aged ≥ 16 years [16]. They found that the mean age of the patients was 32 years, 33% lived with a partner, 7% had at least one child through assisted reproductive technology, and 4% had adopted children [16]. They found that 72% of DSD patients received adequate information about reproduction and 17% did not receive satisfactory information [16]. We think it's too early to assess the reproductive status of all the patients involved in our study. So, the mean age of our patients was 9.45 ± 6.81 years.

Among patients with DSD, there are important studies on diagnosis and follow-up approaches of patients with CAH (CAH) [11,17]. In these studies, hormonal reference values, timing of surgery, importance of two-stage or single-stage surgery were well defined in CAH patients [18-20]. Although not all patients of the same age applied, the mean surgical age of our patients was 1.9 ± 1.7 years. There is no scientific study determining the exact age of surgery in these patients [20]. All of our patients underwent surgery and a single-stage surgical procedure was performed. Gonzales and arc female CAH patients had an advantage to have two stages if surgery was necessary [21]. In our study, we performed one-stage surgery on 12 female CAH patients and 2 of them were then revisions were required.

We had some limitations in this study. First of all, this was a retrospective study. There was no control group. We may have been biased in collecting this data. The existing pathologies of the patients were varied. Demographic information on the age of the patients involved in this study, genetic and laboratory information, previous surgeries were not standard. Since the period of time in which the patients were examined was as long as 20 years, some information was obtained from the written records and some information was obtained from computer data. Since most of our patients were in the early stages of life, there were no long-term results.

Conclusion

The differences in DSD patients maybe are not noticed by both the family and the doctors they first consult. DSD patients may be diagnosed late and genetic analysis may be delayed because the first admission to these patients is delayed. These patients maybe are raised in different genders until they are diagnosed by their specialists. The delay in the diagnosis of the patient may also affect the content of the surgical procedure performed. DSD should be considered in every child who presents with genital anomalies such as hypospadias, undescended testicle, and cliteromegaly. A meticulous and detailed evaluation should be performed to determine the pathway in DSD patients. The team that evaluates the patients, determines and implements the appropriate approach is expected to be experienced. The treatment of the diagnosed DSD patient should be determined by a council consisting of pediatric urology, pediatric endocrine and family. In order to achieve the expected results in these patients, sexual func-

tions and continence as well as reproductive status should be taken into consideration and follow-up should be done in the adult period.

Ethics approval

Ethical approval for this study was obtained from the Inonu University Health Sciences Non-Interventional Clinical Research Ethics Committee (No: 2018/9-20).

References

- Hughes IA, Houk C, Ahmed SF, Lee PA. Consensus statement on management of intersex disorders. *Arch Dis Child.* 2006; 91(7): 554-563.
- Falhammar H, Claahsen-van der Grinten H, Reisch N, Slowikowska-Hilczer J, Nordenström A, Roehle R, et al. Health status in 1040 adults with disorders of sex development (DSD): a European multicenter study. *Endocr Connect.* 2018; 7(3): 466-478.
- Donahoe PK, Schnitzer JJ, Pieretti E. Ambiguous Genitalia. In Grosfeld J.L, O'Neil J.A, Coran A.G, Fonkalsrud E.W. *Textbook of Pediatric Surgery.* 6. St ed. Philadelphia: 2006. Vol 2, Chap.121: 1911-1934.
- Kim KS, Kim J. Disorders of sex development. *Korean J Urol.* 2012; 53(1): 1-8.
- Nixon R, Cerqueira V, Kyriakou A, Lucas-Hearld A, McNeilly J, McMillan M, et al. Prevalance of endocrine and genetic abnormalities in boys evaluated systemically for a disorder of sex development. *Hum Reprod.* 2017; 32(10): 2130-7.
- Hughes IA, Morel Y, McElreavy K, Rogol A. Biological assessment of abnormal genitalia. *J Pediatr Urol.* 2012; 8(6): 592-6.
- Alhomaidah D, McGowan R, Ahmed SF. The current state of diagnostic genetics for conditions affecting sex development. *Clin Genet.* 2017; 91(2): 157-62.
- Eggers S, Sadedin S, van den Bergen JA, Robevska G, Ohnesorg T, Hewitt J, et al. Disorders of sex development: insights from targeted gene sequencing of a largeinternational patient cohort. *Genome Biol.* 2016; 17(1): 243.
- Rocca MS, Ortolano R, Menabo S, Baronio F, Cassio A, Russo G, et al. Mutational and functional studies on NR5A1 gene in 46,XY disorders of sex development: identification of six novel loss of function mutations. *Fertil Steril.* 2018; 109(6):1105-13.
- Baxter RM, Arboleda VA, Lee H, Barseghyan H, Adam MP, Fechner PY, et al. Exome sequencing fort he diagnosis of 46,XY disorders of sex development. *J Clin Endocrinol Metab.* 2015; 100(2): 333-44.
- Özen S, Onay H, Atik T, Solmaz AE, Özkınay FF, Gökşen D, et al. Rapid molecular genetic diagnosis with next-generation sequencing in 46,XY disorders of sex development cases: efficiency and cost assessment. *Horm Res Paediatr.* 2017; 87: 81-7.
- Rangecroft L. Surgical management of ambiguous genitalia. *Arch Dis Child.* 2003; 88(9): 799-801.
- Mouriquand PD, Gorduza DB, Gay CL, Meyer-Bahlburg HF, Baker L, Baskin LS, et al. Surgery in disorders of sex development (DSD) with a gender issue: If (why), when, and how? *J Pediatr Urol.* 2016; 12(3): 139-49.
- Vidal I, Gorduza DB, Haraux E, Gay CL, Chatelain P, Nicolino M, et al. Surgical options in disorders of sex development (dsd) with ambiguous genitalia. *Best Pract Res Clin Endocrinol Metab.* 2010; 24(2): 311-24.
- Nasir AA, Abdur-Rahman LO, Adesiyun OO, Bamiqbola KT, Adeqboye MB, Raji HO, et al. Analysis of presentations and outcomes of care of children with Disorders of Sex Development in a Nigerian Hospital. *J Pediatr Adolesc Gynecol.* 2019; 32(1): 21-6.
- Slowikowska-Hilczer J, Hirschberg AL, Claahsen-van der Grinten H, Reisch N, Bouvattier C, Thyen U, Cohen Kettenis P, et al. Fertility outcome and information on fertility issues in individuals with different forms of disorders of sex development: findings from the dsd-LIFE study. *Fertil Steril.* 2017; 108(5): 822-31.
- Parsa AA, New MI. Steroid 21-hydroxylase deficiency in CAH. *J Steroid Biochem Mol Biol.* 2017; 165: 2-11.
- Bulsari K, Falhammar H. Clinical perspectives in CAH due to 11 β -hydroxylase deficiency. *Endocrine.* 2017; 55(1): 19-36.
- New MI, Lorenzen F, Lerner AJ, Kohn B, Oberfield SE, Polack MS, et al. Genotyping steroid 21-hydroxylase deficiency: hormonal reference data. *J Clin Endocrinol Metab.* 1983; 57(2): 320-6.
- Eckoldt-Wolke F. Timing of surgery for feminizing genitoplasty in patients suffering from CAH. *Endocr Dev.* 2014; 27: 203-9.
- Gonzalez R, Ludwikowski BM. Should the genitoplasty of girls with CAH be done in one or two stages? *Front Pediatr.* 2014; 10(1): 54.