



# A comparative and retrospective study on the efficacy of caudal epidural steroid injection plus ganglion impar block versus ganglion impar block in patients with coccydynia

Samet Sancar Kaya<sup>a,\*</sup>, Erkan Yavuz Akcaboy<sup>a</sup>, Seref Celik<sup>a</sup>, Hamit Goksu<sup>b</sup>, Muge Baran<sup>c</sup>, Gokhan Yildiz<sup>a</sup>, Mustafa Yemliha Ayhan<sup>a</sup>, Saziye Sahin<sup>a</sup>

<sup>a</sup>University of Health Sciences, Ankara City Hospital, Department of Pain Medicine, Ankara, Türkiye

<sup>b</sup>University of Health Sciences, Dr. Abdurrahman Yurtaslan Ankara Oncology Training and Research Hospital, Department of Pain Medicine, Ankara, Türkiye

<sup>c</sup>Agri Training and Research Hospital, Department of Pain Medicine, Agri, Türkiye

## ARTICLE INFO

### Keywords:

Coccydynia  
Ganglion impar block  
Caudal epidural  
Coccydynia treatment

Received: Jul 20, 2022

Accepted: Nov 02, 2022

Available Online: 23.12.2022

### DOI:

[10.5455/annalsmedres.2022.07.217](https://doi.org/10.5455/annalsmedres.2022.07.217)

## Abstract

**Aim:** Coccydynia is defined as pain in the area of the coccyx. The initial treatment is conservative therapy, although several interventional treatments can be performed in patients who do not respond well. The purpose of this study is to evaluate the efficacies of ganglion impar blocks and caudal epidural steroid injections in the treatment of coccydynia.

**Materials and Methods:** From January 2019 to June 2021, a retrospective review was conducted on 65 patients who underwent ganglion impar block (n = 25) or ganglion impar block and caudal epidural steroid injection (n = 40) for coccydynia. Pain scores at baseline and at the first and third months after the procedure were compared between two groups.

**Results:** In both groups, a statistically significant decrease was found at the first and third months when post-injection Visual Analog Scale (VAS) scores were compared to the basal VAS scores (p < 0.05). However, no statistically significant difference was found between the groups at the first and third months (p = 0.39 and p = 0.82, respectively).

**Conclusion:** Ganglion impar block is effective for patients with coccydynia in providing pain relief. However, the addition of caudal epidural steroid injection to the ganglion impar block in patients with coccydynia has no additional contribution to pain relief.



Copyright © 2022 The author(s) - Available online at [www.annalsmedres.org](http://www.annalsmedres.org). This is an Open Access article distributed under the terms of Creative Commons Attribution-NonCommercial-NoDerivatives 4.0 International License.

## Introduction

Coccydynia is the kind of pain typically felt around the coccyx, and is often due to excessive mobility of the coccyx and increased by pressure [1]. Those living with coccydynia find that it negatively affects their quality of life. Trauma, number of births, advanced age (degenerative changes in the sacrococcygeal joint), obesity, rapid weight loss, interventions such as colonoscopy, coccyx structure and sports such as ice skating and cycling are risk factors for coccydynia [2,3].

Conservative treatment is the first-line choice for coccydynia. However, in cases that are not responsive to conservative treatment, caudal epidural steroid injections (CESI), ganglion impar blocks (GIB), radiofrequency ablation of sacral nerves, and coccygectomy can be applied [4]. The

ganglion impar is a sympathetic ganglion located around the sacrococcygeal joint that provides nociception and sympathetic innervation of the perineal region [4]. GIB can be performed with computerized tomography, fluoroscopy, and ultrasonography (using the transsacrococcygeal or Plancarte technique) [5].

In many pain clinics, CESI are commonly performed for coccydynia, although this is not adequately supported by published research [6,7]. However, there is limited clinical evidence on what the outcomes may be for these interventions.

In this study, we aimed to contribute to the literature by comparing the effectiveness of GIB and GIB plus CESI in patients with coccydynia.

## Materials and Methods

This study retrospectively reviewed medical records of patients with coccydynia presented to the algology clinic (January 2019 – June 2021) after they did not respond

\*Corresponding author:

Email address: [sametsancarkaya@hotmail.com](mailto:sametsancarkaya@hotmail.com) ( Samet Sancar Kaya)

to conservative treatments. This protocol was reviewed and approved by the Institutional Review Board (Ankara City Hospital, No. 1 Clinical Research Ethics Committee. Reference number: E1-21-2249, Date: 29.12.2021).

#### Inclusion criteria

1. 18 years of age and over
2. Coccydynia patients who failed to respond to conservative treatments for at least 3 months
3. Patients who underwent CESI and/or transsacroco-  
cyeal GIB under fluoroscopy and had routine coccyx  
radiographs before the procedure.

#### Exclusion criteria

1. Previous surgery to the lumbar or coccygeal region
2. Coccydynia associated with cancer metastasis
3. No optimal fluoroscopy images during injection
4. Failure to block with appropriate doses of drugs
5. Missing information in the patient's file.

A total of 91 patients who had undergone either fluoroscopic-guided GIB or fluoroscopic-guided GIB and CESI were enrolled into the study. Age, gender, duration of pain, history of trauma and Visual Analog Scale (VAS) scores before and at 1 and 3 months after the procedure were collected from the medical records.

#### Technique

The injections were performed in an operating room. Each patient was monitored and vital signs were observed throughout the entire procedure (blood pressure, heart rate, SpO<sub>2</sub>).

#### Fluoroscopic-guided ganglion impar block

After the intergluteal area was prepared with sterile aseptic precautions while the patient was lying prone, the sacrococcygeal area was identified in the lateral position under C-arm fluoroscopy. The area was infiltrated with 2-3 mL 1% lidocaine using a 25G needle. A 22-gauge spinal needle was inserted from the midline at the sacrococcygeal junction. In the lateral fluoroscopic view, when the tip of the needle was anterior to the coccyx, its location was confirmed by 1 mL non-ionic contrast spread in the shape of a "comma" (Figure 1). After confirmation, 3 mL of 0.25% bupivacaine and 2 mL of 8 mg dexamethasone were injected.

#### Fluoroscopic-guided caudal epidural steroid injection

Following skin preparation, the sacral cornua was visualized on the lateral fluoroscopic image. The area was infiltrated with 2-3 mL 1% lidocaine using a 25G needle. A 18-gauge tuohy needle was placed between the sacral cornu at about 45°, with the tip of the needle facing ventrally until contact with the sacrum was made in the "sacral triangle". The needle was then redirected more cephalad, horizontal, and parallel to the table, advancing it into the sacral canal through the sacrococcygeal ligament and into the epidural space. After confirming with nonionic contrast spread in

lateral and AP fluoroscopic imaging (Figure 2), 8 mg dexamethasone, 2 ml 0.25% bupivacaine and 6 ml saline were given into the caudal epidural space.

The level of pain was assessed with Visual Analogue Scale (VAS) (0 = "no pain" and 10 = "worst imaginable pain") during the pre-procedure and again at the first and third months of follow up. A reduction in VAS scores greater than 50% was defined as successful block.

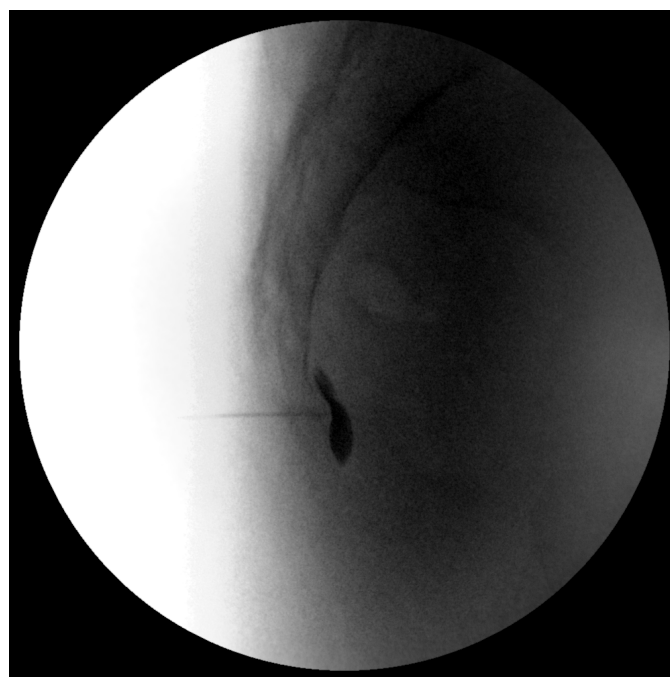Follow-up data of the patients were obtained through a retrospective scan of the digital patient files in the hospital system.

#### Statistical analysis

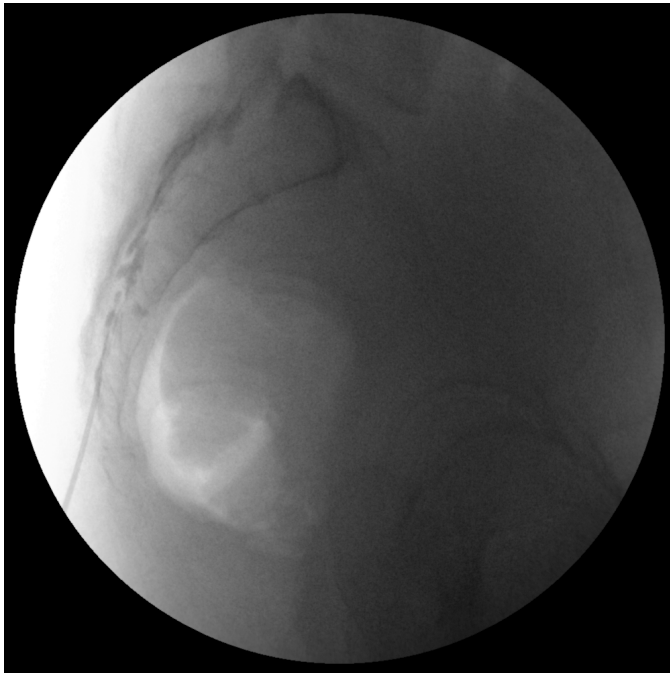
All analyses were carried out using IBM SPSS Version 25.0 (IBM®, USA). Mean and standard deviation are used to represent quantitative data. The quantitative data were analyzed with the t test. To compare statistical VAS score reduction between groups two-factor ANOVA test was used. To detect relationship between statistical VAS score decrease and pain duration between groups binary logistic regression was used. Post-hoc power analysis showed that with 0.054 effect size and  $\alpha = 0.05$  significance level 76.0% power was calculated. A statistical significance threshold of  $p < 0.05$  is considered significant.

#### Results

Figure 3 shows the CONSORT of patients. The study included 28 females and 9 males in Group GIB and 27 females and 13 males in Group GIB plus CESI. The mean duration of pain was  $24.68 \pm 29.20$  months and  $20.38 \pm 22.64$  months in Group GIB and Group GIB + CESI, respectively. Both groups were similar in terms of age, gender and trauma history (Table 1). When the patient's VAS values were analyzed, the mean before injection was



**Figure 1.** Lateral fluoroscopic view of ganglion impar block.



**Figure 2.** Contrast spread in caudal epidural space.

**Table 1.** Descriptive features of patients.

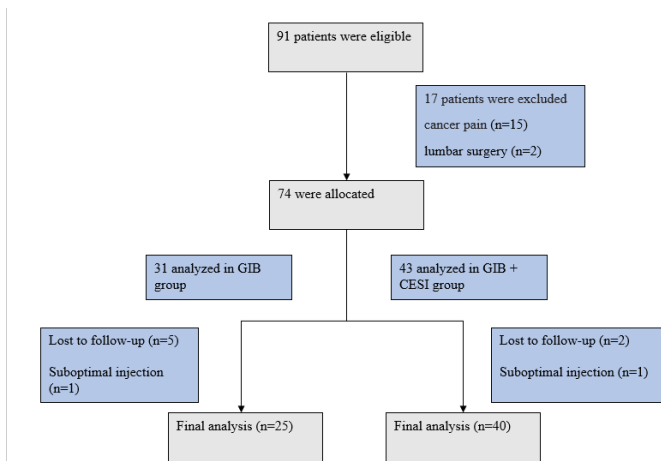
		GIB (n=25)	GIB + CESI (n=40)	p
Age (mean ± sd)		42.48 ± 16.33	43.73 ± 12.67	0.732
Gender n (%)	Male	6 (24)	13 (32.5)	0.464
	Female	19 (76)	27 (67.5)	
Duration of pain (months) (mean±sd)		24.68 ± 29.20	20.38 ± 22.64	0.508
History of trauma n (%)	Yes	13 (52)	19 (47.5)	0.724
	No	12 (48)	21 (52.5)	

Ganglion impar blocks, CESI: Caudal epidural steroid injections.

**Table 2.** Comparison of VAS scores.

	GIB	GIB + CESI	p
VAS baseline	7.52 ± 1.00	7.65 ± 0.84	0.574
VAS 1st month	4.24 ± 3.15	3.60 ± 2.73	0.390
VAS 3rd month	5.04 ± 2.90	4.90 ± 2.15	0.825

GIB: Ganglion impar blocks, CESI: Caudal epidural steroid injections, VAS: Visual Analog Scale.



GIB: Ganglion impar blocks, CESI: Caudal epidural steroid injections.

**Figure 3.** Consort flowchart of the studied patients.

7.52 ± 1.00 in Group GIB and 7.65 ± 0.84 in Group GIB + CESI. There was no statistically significant difference between pain levels in both groups before injection (p = 0.574) (Table 2). In both groups, a statistically significant decrease was found in both the first and third month post-injection VAS values when compared to the basal VAS values (p < 0.05) (Table 2).

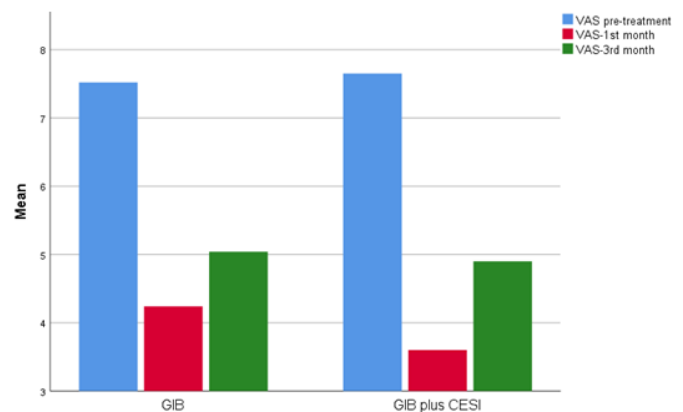
However, no statistically significant difference was found between the two groups themselves (p > 0.05) (Figure 4). For Group GIB, 56% saw their pain reduced by half at the first month and 44% of the patients continued to feel that way at the third month post-procedure. For Group GIB and CESI, 55% and 30% of the patients had pain reduction greater than 50% at the first and third months, respectively. There was no significant meaningful pain reduction difference between the groups at either the first or third month (p > 0.05). Evidence of a correlation between

pain duration and injection success in both groups was undetectable with logistic regression analysis. No complications were recorded during follow-up.

**Discussion**

Coccydynia is a painful condition that radiates to the sacral and perineal regions around the coccyx. The pathophysiology of the pain is often unknown, but trauma is the most common cause of coccydynia. It is more common in females than males [8,9]. As consistent with the literature, 70.2% of our patients with coccydynia were women and a history of trauma was present in 50.8%.

Conservative treatment remains the mainstay for coccydynia. Several interventional therapies have been introduced to treat patients with coccydynia who do not respond to initial conservative therapy, but there is no consensus on



GIB: Ganglion impar blocks, CESI: Caudal epidural steroid injections, VAS: Visual Analog Scale.

**Figure 4.** VAS scores before and after injection for the two groups.

which is the best option. In addition, the success rates of interventional procedures in existing studies are inconsistent. In this study, we aimed to investigate whether the CESI added to the GIB provides an additional benefit in the treatment of coccydynia. This was necessary because there is a need for more data on interventional procedures in the treatment of coccydynia.

Although pericoccygeal injections have a significant effect, there is no consensus in the literature regarding the injection site [2]. The reason for this is that the pain mechanism in coccydynia has not been clearly explained.

Since the event leading to coccydynia often involves trauma, it is reasonable to assume a mechanical etiology for the pain. Although the trauma rate in the etiology of chronic coccydynia is around 50% in the literature, repetitive microtraumas caused by inadequate body position such as long-term cycling and motorcycle use and sitting for a long time can also cause chronic sprain of the coccyx [10,11]. Chronic inflammatory changes caused by damage to post-traumatic pericoccygeal structures (such as bone, fascia, ligament) may lead to hypermobility or subluxation of the coccyx [11-13]. Therefore, corticosteroid infiltration can suppress inflammation and reduce pain. It is known that in addition to the pathology in the pericoccygeal structures, excessive activity or sensitivity of the ganglion impar plays a role in the pain mechanism of coccydynia, but it is unclear which pathology is more prominent [14].

Impar ganglion block is frequently applied in cases where conservative treatment is insufficient. GIB can lessen pain levels by both reducing the excessive activity and sensitivity of ganglion impar and suppressing pericoccygeal inflammation. In addition, the movement of some of the pain nerves of the coccyx together with the sympathetic nerves is another reason for the use of GIB in the treatment of coccydynia.

Caudal epidural steroid injections are frequently used in the treatment of coccydynia, although there is insufficient evidence. Plancarte et al. [15] recommended the application of epidural infiltration of steroids via the peridural caudal route together with GIB block in patients who did not respond adequately to the first GIB. Sáenz et al. [6] obtained a successful response in 13 of 21 patients with coccydynia who applied GIB. They performed CESI with GIB in eight patients who had an unsatisfactory response, and they achieved a successful pain reduction in three of these eight patients. Govardhani et al. [7] compared the effectiveness of CESI and manipulation with GIB and manipulation. They observed that GIB with manipulation was more effective than CESI with manipulation to improve pain sensation in patients with coccydynia. In this study, a significant reduction in pain was achieved with GIB in patients with coccydynia at the first and third months after injection, but it seemed there were no additional benefit of adding CESI to GIB.

The success rate of GIB in coccydynia has been reported differently in the literature. Gunduz et al. [11] achieved more than 50% pain reduction with GIB in 18 of 19 patients with traumatic coccydynia. Kim et al. [16] reported a reduction of more than 4 units in VAS with GIB in 17% of patients with non-cancer-related coccyx pain. This study

found at least 50% improvement in VAS in 56% of patients with coccydynia at the first month. There are several reasons for inconsistent data on GIB in the literature. The anatomical variability of the location of the ganglion impar and application of the GIB at the sacrococcygeal or intercoccygeal disc level may result in different success rates [14]. The history of post-traumatic coccydynia in patients included in the studies may also affect the results. The higher success rates reported by Gunduz et al. compared to Kim et al. may be related to the application of GIB by Gunduz et al. to patients with posttraumatic coccydynia. In the current study, the effect of GIB by the third month was 63.6% and 46.9% in patients with and without trauma history, respectively. Patients with a history of trauma had a higher success rate with GIB.

Malhotra et al. [17] found both GIBs applied by the transsacrocoxygeal and transintercoccygeal approach to be effective, but they did not report any significant difference between the two groups. There is evidence that the sacrococcygeal joint and intercoccygeal joint may be a source of pain in coccydynia [18-20]. In addition to demonstrating the presence of mechanoreceptors in intercoccygeal discs, there are also studies showing that coccyx pain may be disc-derived in coccyx discography [18, 20]. It is also known that the sacrococcygeal joint is in close proximity to the ganglion impar [21, 22]. For these reasons, we chose the sacrococcygeal joint as the entry level for GIB. We think that GIB at this level can block both sympathetic fibers and suppress pericoccygeal and possible sacrococcygeal disc-derived inflammation.

The major limitations of our study are a limited follow-up period of three months, the retrospective nature, and the absence of functional parameters such as painless sitting time and Oswestry disability index. In addition, the number of patients in the GIB group was relatively low.

## Conclusion

In conclusion, GIB is an effective treatment procedure with a low complication rate for patients with coccydynia in providing pain relief by the transsacrocoxygeal technique. Adding caudal epidural steroid injection to the impar ganglion block has no additional contribution in terms of pain relief in patients with coccydynia.

## Ethics approval

Ethical approval for this study was obtained from Ankara City Hospital, No. 1 Clinical Research Ethics Committee (Reference number: E1-21-2249, Date: 29.12.2021).

## References

- Emerson SS, Speece AJ. Manipulation of the coccyx with anesthesia for the management of coccydynia. *J Osteopat Med.* 2012;112(12):805-7. doi:10.7556/jaoa.2012.112.12.805.
- Nathan S, Fisher B, Roberts C. Coccydynia: a review of pathoanatomy, aetiology, treatment and outcome. *J Bone Joint Surg Br.* 2010;92(12):1622-7. doi:10.1302/0301-620X.92B12.25486.
- Bauer P. Chronic anoperineal pain: diagnosis and strategy for evaluation. *J Chir.* 2004;141(4):225-31. doi:10.1016/s0021-7697(04)95598-6.
- Lirette LS, Chaiban G, Tolba R, Eissa H. Coccydynia: an overview of the anatomy, etiology, and treatment of coccyx pain. *Ochsner J.* 2014;14(1):84-7.

5. Scott-Warren JT, Hill V, Rajasekaran A. Ganglion impar blockade: a review. *Curr Pain Headache Rep.* 2013;17(1):1-6. doi:10.1007/s11916-012-0306-7.
6. Sáenz MC, Cerrillo JL, Colomo CV, et al. Infiltration of impar and caudal ganglia in the management of traumatic coccydynia refractory to conventional analgesic treatment. *Rev Esp Cir Ortop Traumatol (Engl Ed).* 2011;55(5):340-5. doi:10.1016/j.recote.2011.05.004.
7. Govardhani Y, RamMohan G, Abhijith S, Savithri B. A comparative retrospective study of the efficacy of caudal epidural with manipulation versus ganglion impar block with manipulation in patients with coccydynia. *Indian J Pain.* 2021;35(1):42. doi:10.4103/ijpn.ijpn\_152\_20.
8. Karadimas EJ, Trypsiannis G, Giannoudis PV. Surgical treatment of coccygodynia: an analytic review of the literature. *Eur Spine J.* 2010;20:698-705. doi:10.1007/s00586-010-1617-1.
9. Howard PD, Dolan AN, Falco AN, et al. A comparison of conservative interventions and their effectiveness for coccydynia: a systematic review. *J Man Manip Ther.* 2013;21(4):213-9. doi:10.1179/2042618613Y.0000000040.
10. Frazier L. Coccydynia: a tail of woe. *N C Med J.* 1985;46(4):209-12.
11. Gunduz OH, Sencan S, Kenis-Coskun O. Pain relief due to transsacrococcygeal ganglion impar block in chronic coccygodynia: a pilot study. *Pain Med.* 2015;16(7):1278-81. doi:10.1111/pme.12752.
12. Patel R, Appannagari A, Whang PG. Coccydynia. *Curr Rev Musculoskelet Med.* 2008;1:223-6. doi:10.1007/s12178-008-9028-1.
13. Fogel GR, Cunningham III PY, Esses SI. Coccygodynia: evaluation and management. *JAAOS- J Am Acad Orthop Surg Glob Res Rev.* 2004;12(1):49-54. doi:10.5435/00124635-200401000-00007.
14. Oh C-S, Chung I-H, Ji H-J, Yoon D-M. Clinical implications of topographic anatomy on the ganglion impar. *J Am Soc Anesth.* 2004;101(1):249-50. doi:10.1097/00000542-200407000-00039.
15. Plancarte R. Presacral blockade of the ganglion of Walthers (ganglion impar). *Anesthesiology.* 1990;73:751. doi:10.1097/00000542-199009001-00749.
16. Kim C-S, Jang K, Leem J-G, et al. Factors associated with Successful Responses to Ganglion Impar Block: A Retrospective Study. *Int J Med Sci.* 2021;18 (13):2957-63. doi:10.7150/ijms.60962.
17. Malhotra N, Goyal S, Kumar A. Comparative evaluation of transsacrococcygeal and transcoccygeal approach of ganglion impar block for management of coccygodynia. *Journal Anaesthesiol Clin Pharmacol.* 2021;37(1):90. doi:10.4103/joacp.JOACP\_588\_20.
18. Maigne J-Y, Guedj S, Straus C. Idiopathic coccygodynia. Lateral roentgenograms in the sitting position and coccygeal discography. *Spine* 1994;19(8):930-4. doi:10.1097/00007632-199404150-00011.
19. De Andrés J, Chaves S. Coccygodynia: a proposal for an algorithm for treatment. *J Pain* 2003;4(5):257-66. doi:10.1016/S1526-5900(03)00620-5.
20. Trollegaard A, Aarby N, Hellberg S. Coccygectomy: an effective treatment option for chronic coccydynia: retrospective results in 41 consecutive patients. *The J Bone Joint Surg Br.* 2010;92(2):242-5. doi:10.1302/0301-620X.92B2.23030.
21. Foye PM. Ganglion impar blocks via coccygeal versus sacrococcygeal joints. *Reg Anesth Pain Med.* 2008;33(3):279. doi:10.1016/j.rapm.2007.12.011.
22. Foye PM. New approaches to ganglion impar blocks via coccygeal joints. *Reg Anesth Pain Med* 2007; 32 (3): 269. doi:10.1016/j.rapm.2006.12.005.