

# Comparison of laser and piezo incisions to accelerate orthodontic tooth movement - A pilot rat model study

 Hilal Yilanci<sup>1</sup>,  Burcak Kara<sup>2</sup>,  Sabri Ilhan Ramoglu<sup>3</sup>

<sup>1</sup>Department of Orthodontics, Faculty of Dentistry, Medipol University, Istanbul, Turkey

<sup>2</sup>Private practice, Istanbul, Turkey

<sup>3</sup>Department of Orthodontics, Faculty of Dentistry, Altinbas University, Istanbul, Turkey

Copyright@Author(s) - Available online at [www.annalsmedres.org](http://www.annalsmedres.org)

Content of this journal is licensed under a Creative Commons Attribution-NonCommercial 4.0 International License.



## Abstract

**Aim:** The aim of this study was to determine changes in bone structure after laser and piezo incisions evaluated with micro-computed tomography (micro-CT).

**Materials and Methods:** Forty-eight adult male Sprague Dawley rats were randomly divided into 4 groups: no additional intervention to accelerate tooth movement (n=15), laser incision (n=15), piezocision (n=15), and control (n=3). These groups were divided into subgroups based on duration of applied force: 0, 3, 7, 14, 21, and 28 days. Piezo and laser incisions were made vertically on the mesial palatal side of the left maxillary molar without flap elevation. Tooth movement, bone volume, and bone mineral density were evaluated with micro-CT. P values less than 0.05 were considered statistically significant.

**Results:** There were no significant differences in bone mineral density, bone volume, or amount of tooth movement between time points in any of the groups. The amount of tooth movement was significantly different between the groups at day 21.

**Conclusion:** These findings provide some initial basic understanding of changes in the bone following tooth movement alone and with piezocision and laser incisions. Larger sample sizes are needed to better elucidate their effects.

**Keywords:** Er-YAG lasers; orthodontic tooth movement; piezosurgery; X-Ray microtomography

## INTRODUCTION

A successful orthodontic treatment comprises short treatment period and stable results with minimal histological damage and pain. Prolonged treatment time not only affects the patient psychosocially but also increases the risk of periodontal disease, caries, and root resorption. There have been many attempts to shorten treatment time by accelerating tooth movement using methods such as dentoalveolar distraction osteogenesis, (1-4) periodontal ligament distraction, (5,6) corticotomies, (7-9) and corticision (10).

It has been reported that surgical injury to the cortical bone initiates biochemical changes leading to rapid tooth movement, which was described by Frost as regional acceleratory phenomenon (11). These injuries lead to an increase of anabolic and catabolic activity in the medullary bone and dramatic tissue turnover. This temporary osteopenia leads to rapid tooth movement (12,13).

The first documented corticotomy was described by Kole in 1959. The author emphasized that the cortical bone is the main cause of resistance and that disrupting this

unity will accelerate orthodontic tooth movement (14-16). In 2001, Wilcko et al. (7) introduced periodontally accelerated osteogenic orthodontics, which is a series of corticotomies followed by bone grafting procedures to prevent dehiscence and increase bone volume.

The main disadvantage of corticotomy is patient refusal because the procedure is highly invasive and requires flap elevation, and extensive osseous surgery leads to postoperative discomfort, swelling, and pain. Therefore, minimally invasive surgical procedures without extensive flap elevations were introduced, such as corticision, (10,17) piezopuncture (18,19) and micro-osteoperforations (20-22).

In 2007, Vercellotti and Podesta (23) combined piezosurgery and corticision and reported that the duration of treatment had significantly shorten. However, this technique was still invasive due to flap elevation. Dibart et al. (24) introduced a new minimally invasive procedure that they called 'Piezocision' which is flapless and uses a piezosurgery blade to make cuts on buccal cortical bone.

**Received:** 05.03.2020 **Accepted:** 08.06.2020 **Available online:** 22.03.2021

**Corresponding Author:** Hilal Yilanci, Department of Orthodontics, Faculty of Dentistry, Medipol University, Istanbul, Turkey

**E-mail:** [hilalkaramehmetoglu@gmail.com](mailto:hilalkaramehmetoglu@gmail.com)

More recently, surgical lasers have been utilized in flapless corticotomy procedures. However, there are very few studies in the literature about laser-assisted cortical bone incisions. Seifi et al. (25) performed cortical incisions with Er,Cr:YSGG lasers and reported a significant increase in the rate and amount of orthodontic tooth movement. A clinical trial by Alfawal et al. (26) comparing the effectiveness of piezocision and laser incision showed that there were no significant difference between the two techniques regarding canine retraction rate, canine rotation rate, or anchorage loss. Salman and Ali (27) reported rapid canine retraction in 15 patients with cortical bone perforations performed with Er:YAG laser.

Micro-computed tomography (micro-CT) offers high-resolution imaging at 1 micron per pixel and is widely used to visualize changes in bone structure, root resorption, and tooth movement. This new imaging technology provides three-dimensional qualitative as well as quantitative data, leading to a better understanding of changes in alveolar bone microstructure (28,29).

The aim of this study was to determine changes in bone structure after laser and piezo incisions evaluated with micro-CT.

## MATERIALS and METHODS

This study was approved by the Laboratory Animals Local Ethics Committee of Bezmialem Vakif University (protocol approval number 2013/137). The animals were kept at the Laboratory Animal Facility. Forty-eight adult male Sprague Dawley rats were randomly divided into four groups: no additional intervention to accelerate tooth movement (TM; n=15), laser incision (TM-L; n=15), piezocision (TM-P; n=15), and a control group (C; n=3) (Figure 1). The tooth movement procedure was applied on each animal's left side, with no treatment on the right side.

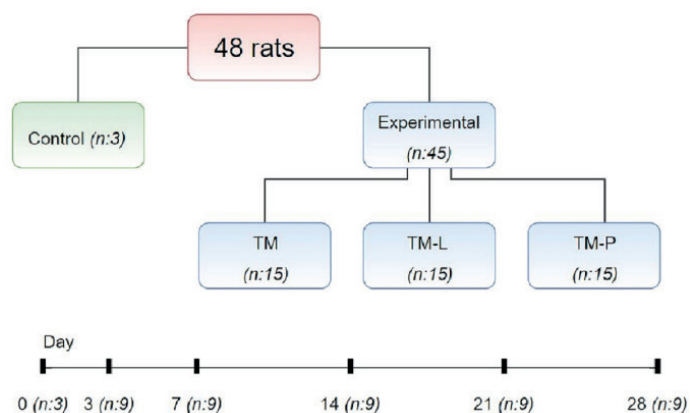


Figure 1. Flowchart diagram

Rats were provided standard laboratory feed and housed in standard cages at room temperature with 12 hours of light per day and 55–70% humidity. Three animals in the control group were euthanized on day 0, while the animals in the other groups were euthanized at 3, 7, 14, 21, and 28 days after the interventions.

All surgical procedures were performed under sterile surgical conditions following proper aseptic and antiseptic technique. The animals were anesthetized by intraperitoneal injection of 3 mg/kg xylazine hydrochloride (Rompun, Bayer, Germany) and 35 mg/kg ketamine hydrochloride (Ketasol 10%, Richter Pharma AG, Austria).

After anesthesia, a 25-g superelastic Ni-Ti closed coil spring (G&H Orthodontics, Franklin, USA) was applied to the left maxillary first molar to move it mesially. The 25-g force was measured by a caliper force gauge (30). The coil was ligated around the left maxillary molar and incisor. Ligation wires were covered with flowable composite (3M Espe, St.Paul, USA) to protect the animal from injury (Figure 2).

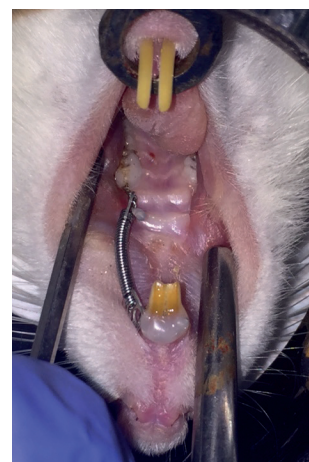


Figure 2. Force application with the closed coil spring

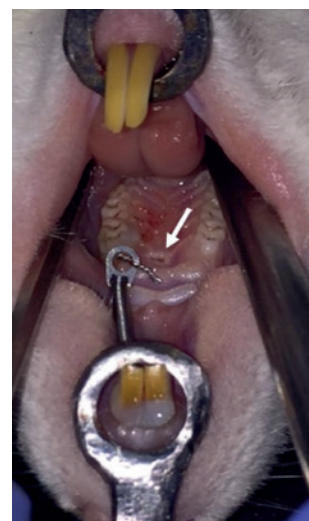

Figure 3. Cortical incision to accelerate tooth movement

Laser incisions were made with an Er,Cr:YSGG laser (2780 nm wavelength; Waterlase MD, Biolase Technology, Inc., Irvine, CA) at 3.0 W, 20 Hz with 50/80% water-air spray. The tip used in the present study was MZ6, 600 µm in diameter and 6 mm length. The beam spot size was 28.26x10-2 mm2. Power density was 1061.6 W/cm2. Laser ablation was performed in contact mode with slightly contact with the mucosa for 15 s.

Piezocisions were made with the Piezotome (Satelec, Acteon group, Merignac, France) by insertion of a BS1 tip. The depth of the vertical penetration was confirmed with the drop felt when reaching the cancellous bone. Incisions were made under saline irrigation. Both piezo and laser incisions were made vertically on the mesial palatal side of the left maxillary molar without flap elevation (Figure 3).

The rats were killed using intraperitoneal injection of high-dose (200 mg/kg) sodium pentothal (Pentothal, Abbott, USA) after the test periods (0, 3, 7, 14, 21, and 28 days). Maxillae were removed and stored in 10% formalin.

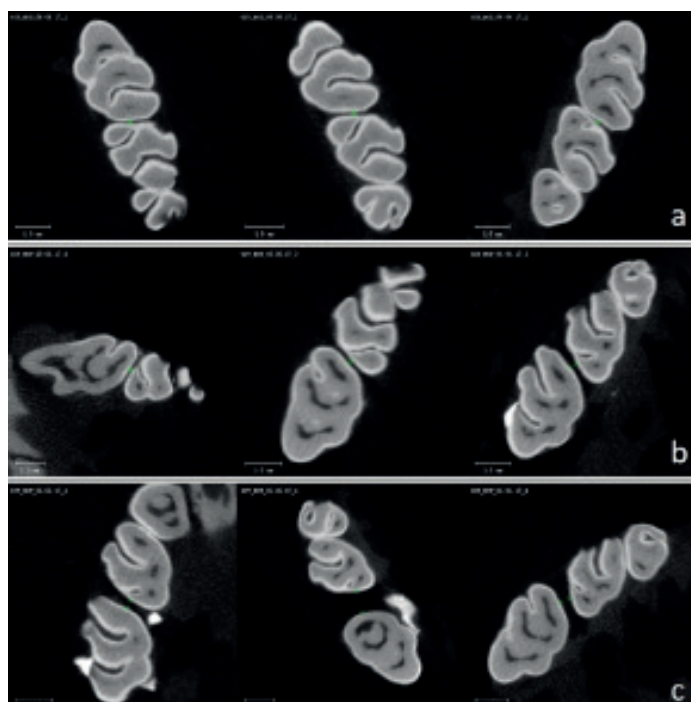


Figure 4. Micro-CT images for day 21. a)TM, b)TM-L c)TM-P

**Micro-CT evaluation**

Micro-CT analysis (Scanco  $\mu$ CT 50, Scanco Medical, Bassersdorf, Switzerland) was performed at 70 kV and 200  $\mu$ A with an exposure time of 300 ms. Micro-CT images with resolution (voxel size) of 20  $\mu$ m were used for quantitative

analysis of bone changes in the region of the maxillary first molar using the  $\mu$ CT Evaluation Program v6.5. (Scanco Medical, Bassersdorf, Switzerland). Measurements were performed according to Baloul et al.'s study (30). Tooth movement and alveolar bone parameters (bone volume and mineral density) were evaluated. The amount of tooth movement was assessed on two-dimensional transverse sections and measured at the interproximal heights of contour between the first and second molars (the distance between the most mesial point of the second molar crown and the most distal point of the first molar crown). Micro-CT images for day 21 were shown in Figure 4. Changes in the alveolar bone were studied by analyzing the interradicular area of the maxillary first molar. A region of interest (ROI) was defined as the inter-radicular area of the maxillary first molar contoured in a transverse plane. In vertical plane, it was contoured as the most occlusal point of the furcation to the apex of the maxillary roots. Bone mineral density was measured with a standard hydroxyapatite.

**Statistical analysis**

Descriptive statistics including mean, standard deviation (SD), and minimum and maximum values were calculated using the SPSS software program (ver. 22.0; SPSS Inc., Chicago, USA). Bone mineral density, bone volume, and tooth movement for each group were evaluated with Friedman test. These variables were compared at each time period using Kruskal–Wallis test. *Post hoc* analysis was used to evaluate the significance of differences in tooth movement at day 21 between the groups. P values less than 0.05 were considered statistically significant.

**RESULTS**

The mean and SD values for bone mineral density, bone volume, and tooth movement in each group are shown in Table 1. There were no significant changes in bone mineral density, bone volume, or amount of tooth movement between time points in any of the groups. Amount of tooth movement was significantly higher in the TM-P group at day 21 compared to the other groups (p=0.027) (Table 2).

Table 1. Comparison of bone mineral density, bone volume and tooth movement amount in each group with Friedman test

	Bone Mineral Density (mg HA/cm <sup>3</sup> )				Bone Volume (mm <sup>3</sup> )				Tooth Movement (mm)				
	25% per.	Median	75% per.	p	25% per.	Median	75% per.	p	25% per.	Median	75% per.	p	
TM	Day 0	1017.78	1032.1	1052.2	0.308	9.38	9.42	9.46	0.525	0.03	0.04	0.05	0.253
	Day 3	1059.78	1078.53	1107.44		8.05	8.24	9.14		0.09	0.1	0.12	
	Day 7	1116.55	1138	1146.78		8.33	8.36	9.11		0.06	0.07	0.08	
	Day 14	1074.33	1094.58	1105.94		8.58	8.65	8.66		0.15	0.21	0.51	
	Day 21	1096.6	1107.78	1116.36		8.52	8.68	8.93		0.06	0.063	0.07	
	Day 28	597.08	1091.13	1091.2		8.97	9.13	9.41		0.17	0.28	0.39	
TM-L	Day 0	1017.78	1032.1	1052.2	0.053	9.38	9.42	9.46	0.059	0.03	0.04	0.05	0.126
	Day 3	1059.47	1060.3	1089.44		9.06	9.21	9.86		0.09	0.1	0.18	
	Day 7	1090.41	1110.7	1133.95		9.54	9.79	10.07		0.15	0.17	0.19	
	Day 14	1113.96	1123.45	1194.29		8.93	8.99	10.38		0.45	0.47	0.48	
	Day 21	1085.76	1094.05	1123.83		9.26	9.48	9.67		0.1	0.11	0.16	
	Day 28	1135.19	1146.93	1149.37		8.87	9.07	9.16		0.2	0.36	0.48	

TM-P	Day 0	1017.78	1032.1	1052.2	0.371	9.38	9.42	9.46	0.711	0.03	0.04	0.05	0.099
	Day 3	1069.08	1085.43	1087.56		8.12	8.48	8.73		0.11	0.12	0.18	
	Day 7	1123.57	1144.76	1154.17		9.55	9.74	9.76		0.1	0.16	0.19	
	Day 14	1074.1	1077.48	1083.03		9.07	9.23	9.61		0.11	0.17	0.25	
	Day 21	1107.7	1110.7	1146.78		9.23	9.27	9.3		0.29	0.33	0.55	
	Day 28	1068.18	1081.83	1094.61		8.57	8.85	9.21		0.35	0.37	0.39	

TM: Tooth movement; TM-L: Laser+Tooth movement; TM-P: Piezo+Tooth movement

Table 2. Comparison of bone mineral density, bone volume and tooth movement amount in each group with Kruskal Wallis test

		Median	p	Median	p	Median	p	Median	p	Median	p
Bone Mineral Density (mg HA/cm <sup>3</sup> )	TM	1078.53		1138		1094.58		1107.78		1091.13	
	TM-L	1060.3	1.000	1110.7	0.733	1123.45	0.099	1094.05	0.561	1146.93	0.066
	TM-P	1085.43		1144.76		1077.48		1110.7		1081.83	
Bone Volume (mm <sup>3</sup> )	TM	8.24		8.36		8.65		8.68		9.13	
	TM-L	9.21	0.288	9.79	0.528	8.99	0.066	9.48	0.141	9.07	0.733
	TM-P	8.48		9.74		9.23		9.27		8.85	
Tooth movement (mm)	TM	0.1		0.07		0.21		0.063		0.28	
	TM-L	0.1	0.646	0.17	0.252	0.47	0.202	0.11	0.027*	0.36	0.837
	TM-P	0.12		0.16		0.17		0.33		0.37	

TM: Tooth movement; TM-L: Laser+Tooth movement; TM-P: Piezo+Tooth movement; \*p<0.05

Table 3. Comparison of tooth movement amount at day 21 in each group with post hoc analysis

Post-Hoc	Day 21 p
TM vs. TM-L (mm)	0.100
TM-L vs. TM-P	0.100

Mann-Whitney U test (p>0.016 Bonferroni correction)

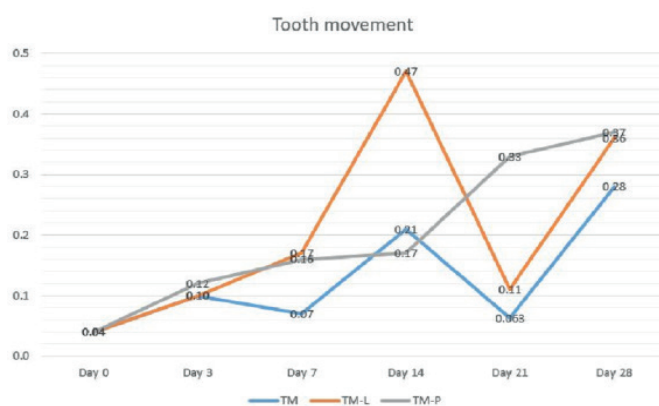


Figure 5. Graph for tooth movement

However, *post hoc* analysis revealed no significant difference in tooth movement between the groups at day 21 (Table 3). The acceleration record of tooth movement amount that occurs between the intervals was shown in the Figure 5. TM and TM-L groups showed a similar rate of acceleration and deceleration. The peak amount of tooth movement observed at day 14 for TM and TM-L groups, after 2 weeks for TM-P group.

## DISCUSSION

To the best of our knowledge, this is the first animal study in the literature comparing piezocision and laser incisions with micro-CT evaluation. The aim of this study was to determine the effects of piezo and laser incisions on bone mineral density, bone volume, and tooth movement. The results showed that the only statistical difference between the groups was significantly greater tooth movement at day 21 in the piezocision group.

In the literature, a study by Alfawal et al. (26) is the only clinical trial comparing piezocision and laser incision in canine retraction. They showed that there were no significant differences between the piezocision and laser incision groups in the overall duration and rate of canine retraction. Both of these minimally invasive corticotomy techniques, performed with advanced tools without the need for flap elevation or suturing, accelerate bone turnover rate.

In the present study, there were no significant differences between the groups in any of the studied variables at any of the time points except amount of tooth movement at day 21. The TM-P group showed higher values than the other groups at day 21, but the difference was not significant in *post-hoc* analysis. This finding is consistent with the results reported by Alfawal et al. (26)

Baloul et al. (30) examined alveolar bone structure after orthodontic tooth movement with or without corticotomy using micro-CT. They reported that bone volume was significantly decreased in the combined corticotomy and tooth movement group at 14 days compared with baseline, while there were no statistically significant differences in bone mineral density among groups at any time point. In

the present study, we observed no significant differences in bone mineral density or bone volume in any of the groups during the study period. This could be due to our low sample numbers.

At day 21, our piezocision group showed approximately 3 times more tooth movement compared with the laser group and 8 times more than the control group. Wilcko et al. (31) reported that this phenomenon showed a model of acceleration that peaked after 4–8 weeks and continued for another 2–4 months. Similarly, in our study, the rate of tooth movement peaked after the first month.

Dibart et al. (32) compared the biological response of bone to different corticotomies made in the calvaria using a piezoelectric blade, bur, and hand-held screw device. Their results showed that the piezoelectric blade generated a much greater degree of demineralization when compared to the bur or hand-held screw device. The authors speculated that this may be due to the additional effect of the high frequency vibrations caused by piezotome on the osteocytes, which is associated with the natural response to surgical damage and increases the natural response. In addition, in the second phase of the RAP, piezoelectric blade enhanced bone apposition compared to the other two devices. This enhanced demineralization effect may explain the increased tooth movement in the piezocision group in our study.

This pilot study provides an initial basic understanding of changes in the bone following tooth movement alone and with piezo and laser incisions. The major limitation of this preliminary study is the small sample size. Based on the findings from this pilot study, a more extensive study is being planned with a large sample size and additional histomorphometric analyses.

## CONCLUSION

Our preliminary results suggest that tooth movements with piezocision and laser incision are successful for accelerated tooth movement. Based on the results and limitations of our pilot study, a more comprehensive study is planned to shed more light on the differences between piezotome-generated incisions and laser incisions and their effects on tooth movement.

*Acknowledgements: Special thanks to Dr.Elif KESER, from Boston University Goldman School of Dental Medicine, for critical review and improvement of the research method.*

*Competing interests: The authors declare that they have no competing interest.*

*Financial Disclosure: This research was supported by Scientific Research Projects Unit of Bezmialem University, Istanbul, Turkey (Project no: 12.2013/13).*

*Ethical approval: This study was approved by the Laboratory Animals Local Ethics Committee of Bezmialem Vakif University (protocol approval number 2013/137).*

## REFERENCES

1. Kisnisci RS, Iseri H, Tuz H, et al. Dentoalveolar distraction osteogenesis for rapid orthodontic canine retraction. *J Oral Maxillofac Surg* 2002;60:389-94.
2. Nakamoto N, Nagasaka H, Daimaruya T, et al. Experimental tooth movement through mature and immature bone regenerates after distraction osteogenesis in dogs. *Am J Orthod Dentofacial Orthop* 2002;121:385-95.
3. Kurt G, Iseri H, Kisnisci R. Rapid tooth movement and orthodontic treatment using dentoalveolar distraction (DAD). Long-term (5 years) follow-up of a Class II case. *Angle Orthod* 2010;80:597-606.
4. Iseri H, Kisnisci R, Bzizi N, et al. Rapid canine retraction and orthodontic treatment with dentoalveolar distraction osteogenesis. *Am J Orthod Dentofacial Orthop* 2005;127:533-41.
5. Liou EJ, Huang CS. Rapid canine retraction through distraction of the periodontal ligament. *Am J Orthod Dentofacial Orthop* 1998;114:372-82.
6. Bilodeau JE. Nonsurgical treatment with rapid mandibular canine retraction via periodontal ligament distraction in an adult with a Class III malocclusion. *Am J Orthod Dentofacial Orthop* 2005;128:388-96.
7. Wilcko WM, Wilcko T, Bouquot JE, et al. Rapid orthodontics with alveolar reshaping: two case reports of decrowding. *Int J Periodontics Restorative Dent* 2001;21:9-19.
8. Gantes B, Rathbun E, Anholm M. Effects on the periodontium following corticotomy-facilitated orthodontics. Case reports. *J Periodontol* 1990;61:234-8.
9. Fischer TJ. Orthodontic treatment acceleration with corticotomy-assisted exposure of palatally impacted canines. *Angle Orthod* 2007;77:417-20.
10. Kim SJ, Park YG, Kang SG. Effects of Corticision on paradental remodeling in orthodontic tooth movement. *Angle Orthod* 2009;79:284-91.
11. Frost HM. The regional acceleratory phenomenon: a review. *Henry Ford Hosp Med J* 1983;31:3-9.
12. Frost HM. The biology of fracture healing. An overview for clinicians. Part I. *Clin Orthop Relat Res* 1989:283-93.
13. Frost HM. The biology of fracture healing. An overview for clinicians. Part II. *Clin Orthop Relat Res* 1989:294-309.
14. Kole H. Surgical operations on the alveolar ridge to correct occlusal abnormalities. *Oral Surg Oral Med Oral Pathol* 1959;12:277-88 contd.
15. Kole H. Surgical operations on the alveolar ridge to correct occlusal abnormalities. *Oral Surg Oral Med Oral Pathol* 1959;12:413-20 contd.
16. Kole H. Surgical operations on the alveolar ridge to correct occlusal abnormalities. *Oral Surg Oral Med Oral Pathol* 1959;12:515-29 concl.

17. Kim SJ, Moon SU, Kang SG, et al. Effects of low-level laser therapy after Corticision on tooth movement and paradental remodeling. *Lasers Surg Med* 2009;41:524-33.
18. Omidkhoda M, Radvar M, Azizi M, et al. Piezopuncture-Assisted Canine Distalization in Orthodontic Patients: Two Case Reports. *J Dent (Shiraz)* 2018;19:74-82.
19. Kim YS, Kim SJ, Yoon HJ, et al. Effect of piezopuncture on tooth movement and bone remodeling in dogs. *Am J Orthod Dentofacial Orthop* 2013;144:23-31.
20. Raptis M. Micro-Osteoperforation as an Adjunct for the Correction of Negative Anterior Overjet in an Adolescent Patient with Missing Upper Lateral Incisors. *J Clin Orthod* 2017;51:47-53.
21. Tsai CY, Yang TK, Hsieh HY, et al. Comparison of the effects of micro-osteoperforation and corticision on the rate of orthodontic tooth movement in rats. *Angle Orthod* 2016;86:558-64.
22. Alikhani M, Raptis M, Zoldan B, et al. Effect of micro-osteoperforations on the rate of tooth movement. *Am J Orthod Dentofacial Orthop* 2013;144:639-48.
23. Vercellotti T, Podesta A. Orthodontic microsurgery: a new surgically guided technique for dental movement. *Int J Periodontics Restorative Dent* 2007;27:325-31.
24. Dibart S, Sebaoun JD, Surmenian J. Piezocision: a minimally invasive, periodontally accelerated orthodontic tooth movement procedure. *Compend Contin Educ Dent* 2009;30:342-4, 6, 8-50.
25. Seifi M, Younessian F, Ameli N. The innovated laser assisted flapless corticotomy to enhance orthodontic tooth movement. *J Lasers in Medical Sciences* 2012;3:20.
26. Alfawal AMH, Hajeer MY, Ajaj MA, et al. Evaluation of piezocision and laser-assisted flapless corticotomy in the acceleration of canine retraction: a randomized controlled trial. *Head Face Med* 2018;14:4.
27. Salman LH, Ali FA. Acceleration of canine movement by laser assisted flapless corticotomy: An innovative approach in clinical orthodontics. *Journal of Baghdad College of Dentistry* 2014;325:1-10.
28. Martin-Badosa E, Amblard D, Nuzzo S, et al. Excised bone structures in mice: imaging at three-dimensional synchrotron radiation micro CT. *Radiology* 2003;229:921-8.
29. Waarsing JH, Day JS, van der Linden JC, et al. Detecting and tracking local changes in the tibiae of individual rats: a novel method to analyse longitudinal in vivo micro-CT data. *Bone* 2004;34:163-9.
30. Baloul SS, Gerstenfeld LC, Morgan EF, et al. Mechanism of action and morphologic changes in the alveolar bone in response to selective alveolar decortication-facilitated tooth movement. *Am J Orthod Dentofacial Orthop* 2011;139:S83-101.
31. Wilcko MT, Wilcko WM, Pulver JJ, et al. Accelerated osteogenic orthodontics technique: a 1-stage surgically facilitated rapid orthodontic technique with alveolar augmentation. *J Oral Maxillofac Surg* 2009;67:2149-59.
32. Dibart S, Alasmari A, Zanni O, et al. Effect of corticotomies with different instruments on cranial bone biology using an ex vivo calvarial bone organ culture model system. *Int J Periodontics Restorative Dent* 2016;36 Suppl:s123-36.