



# Maquet osteotomy for isolated patellofemoral arthritis, a forgotten surgical technique

✉ Murat Danisman<sup>a,\*</sup>, ✉ Muhammet Bozoglan<sup>b</sup>, ✉ Tugcan Demir<sup>a</sup>

<sup>a</sup>Giresun University, Faculty of Medicine, Department of Orthopedics and Traumatology, Giresun, Türkiye

<sup>b</sup>University of Health Sciences, Izmir Tepecik Training and Research Hospital, Department of Orthopedics and Traumatology, Izmir, Türkiye

## Abstract

### ARTICLE INFO

#### Keywords:

Maquet  
Osteotomy  
Patellofemoral arthritis

Received: Oct 04, 2021

Accepted: Jan 12, 2022

Available Online: June 24, 2022

DOI:

[10.5455/annalsmedres.2021.10.575](https://doi.org/10.5455/annalsmedres.2021.10.575)

**Aim:** The focus of this study is to publish the results of Maquet osteotomy for patients who are classified as physiologically young and suffering from anterior knee pain which is unresponsive to conservative treatment.

**Materials and Methods:** We performed a retrospective review of 11 consecutive patients (5 [45.5%] males, 6 [54.5%] females; mean age, 51.8 years) who underwent Maquet osteotomy for isolated patellofemoral osteoarthritis between May 2017 and August 2018. Thirteen osteotomies were performed in 11 patients; 2 patients underwent bilateral procedures. All patients were clinically rated before surgery and at the final follow-up using International Knee Documentation Committee Subjective Knee Evaluation Form (IKDC 2000) and the Kujala Anterior Knee Pain Scale. Also complications were reported.

**Results:** The median follow-up duration was 25 (range=19-33) months. The median preoperative IKDC score was 50 (range = 42-54) points, which had increased to 67 (range=61-72) points at the final follow-up visit ( $p < .001$ ). The median preoperative Kujala score was 59 (range=48-65) points, which had increased to 77 (range = 67-86) points at the final follow-up ( $p < .001$ ). We observed 1 major and 1 minor complication in 13 procedures.

**Conclusion:** Although it looks like an extensile surgery, Maquet osteotomy is applicable, safe, easy and a strong alternative for arthroplasty in patellofemoral arthritis.



Copyright © 2022 The author(s) - Available online at [www.annalsmedres.org](http://www.annalsmedres.org). This is an Open Access article distributed under the terms of Creative Commons Attribution-NonCommercial-NoDerivatives 4.0 International License.

## Introduction

Isolated patellofemoral osteoarthritis is a rarer condition than primary tricompartmental osteoarthritis. Most common etiologic factors in patellofemoral osteoarthritis are primary osteoarthritis, recurrent patellar instability and secondary osteoarthritis due to fracture of the patella. The signs and symptoms of patellofemoral arthritis are non-specific. Most patients feel a discomfort or pain on the anterior part of the knee which is aggravated by ascending or descending stairs and prolonged bent knee positions. Some patients describe a catching or giving way sensation with activity. Physical examination may also demonstrate crepitation, effusion, and facet tenderness. In the early stages of this pathology routine radiographs of the knee are usually within normal limits; rarely, axial views of the patella demonstrate localized or asymmetric subchondral sclerosis. In this situation MRI could help recognition of

early pathological changes in patellar or femoral chondral surfaces. When arthritis progress over time, classic irreversible changes will be seen in radiographs like joint space narrowing, osteophytes and subchondral sclerosis [1, 2].

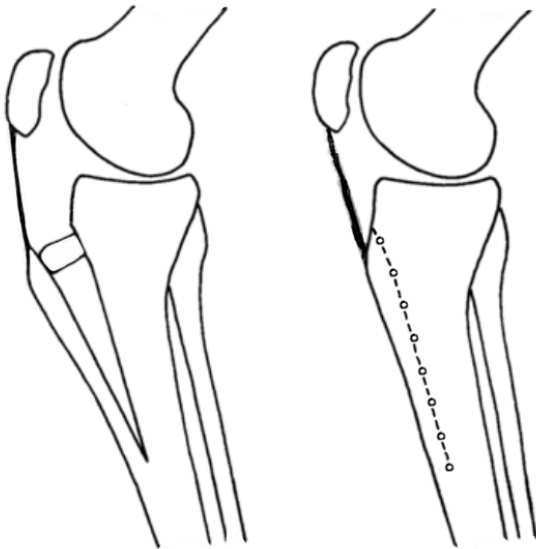
Initial treatment of patellofemoral osteoarthritis is always conservativen such as antiinflammatory medications, quadriceps exercises, hamstring stretching, bracing, taping and orthotics. Also activity modification is necessary. If conservative treatment fails, surgical treatment methods can be administered. In 1963 Paul Maquet [3, 4] described surgical treatment of patellofemoral osteoarthritis by anterior displacement of the patellar tendon (Figure 1).

In the normal knee, patellar tendon and quadriceps tendon are opposite moment arms of force which compresses the patella against the femur. By elevating the patellar tendon, the moment arm of the patella is increased and thus decreasing the contact stresses at the patellofemoral joint [4-6]. (Figure 2)

Despite early results being clinically beneficial, complications like iatrogenic tibia fracture, nonunion, collapse or

\*Corresponding author:

Email address: [murat.danisman@yahoo.com](mailto:murat.danisman@yahoo.com) (✉Murat Danisman)



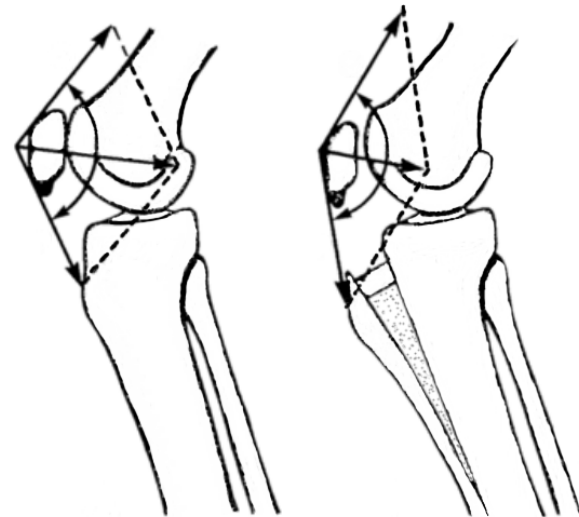
**Figure 1.** Advancement of the tibial tuberosity by elevation of the tibial crest.

loss of correction in time and most of all wound problems were reported up to 20% in those studies [4, 7-11]. Because of these problems and improvements in orthopedic implant technology, surgeons tendency to usage of total knee arthroplasty has increased, and eventually this osteotomy has been abandoned. Patients who were too young to undergo arthroplasty surgeries continued to present problems for surgeons. The purpose of this study is to present our results of the Maquet osteotomy for isolated patellofemoral arthritis in this population.

## Materials and Methods

Patients, who underwent Maquet osteotomy for patellofemoral arthritis, in a single institution between, May 2017 and August 2018, were retrospectively reviewed. The inclusion criteria for surgery were patellofemoral arthritis which was unresponsive to at least one year of conservative treatment consisting of various combinations of medication: activity restriction, weight reduction, intraarticular injection and knee physiotherapy. The patient age was between 40 and 60, Kellgren-Lawrence grade 2 or more patellofemoral arthritis appearance on radiographs, intact medial and lateral compartmental articular cartilage on MRI. Patients with findings which suggested recurrent subluxation or dislocation, abnormal Q angles (more than  $10^\circ$  in men and  $15^\circ$  in women) and had flexion contracture greater than  $15^\circ$  preoperatively were excluded from study.

A total of 13 knees in 11 patients that met our criteria were evaluated. There were 5 males and 6 females who had surgery on 7 right and 6 left knees. There were two bilateral cases. Postoperative follow-up periods ranged from 19 to 33 months, with a mean follow-up period of 25 months. The mean age of the patients at follow-up was 51.8 years (range, 45 to 58). The predisposing factors of patellofemoral arthritis are primary osteoarthritis in 11 cases and sequela of patella fracture in 2 cases. 3 patients had operative procedures prior to the operation



**Figure 2.** Vector representation of the forces acting upon the patella before and after elevation of the tibial tubercle.

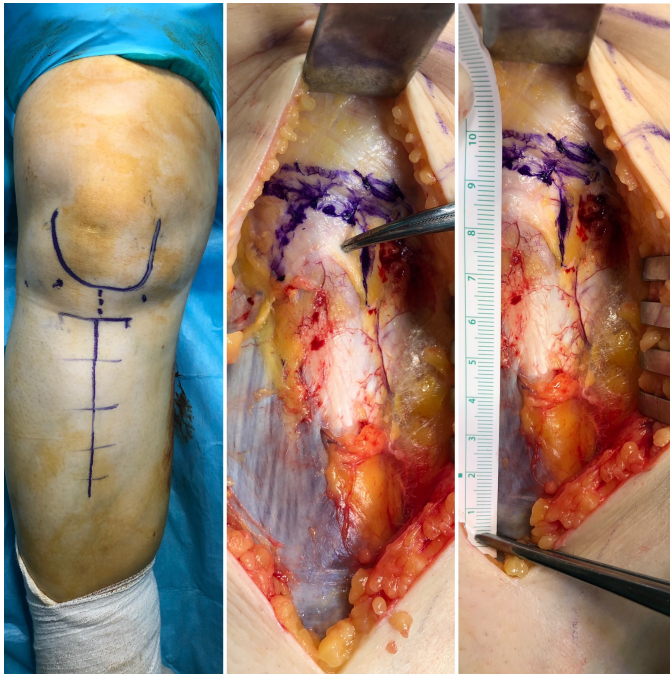
under study; 1 patella fracture surgery, 2 medial meniscus surgery. 10 cases had not had any prior surgical treatment.

## Surgical technique

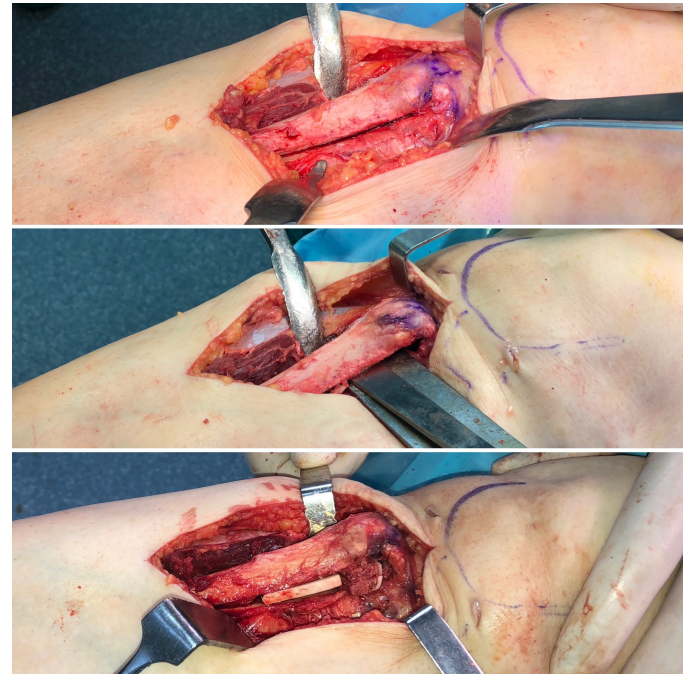
Patients were placed supine on a fluoroscopy table and routinely prepped and draped with a tourniquet. Diagnostic knee arthroscopy was carried out to rule out associated intraarticular pathologies and grading of pathology with using International Cartilage Repair Society (ICRS) grading system [12]. No intervention was made to the patellofemoral pathology during arthroscopy as the aim was only to evaluate the outcome of extraarticular osteotomy. Subsequently, a classic longitudinal straight midline incision was made which extended from a point 2 cm above the superior pole of the patella to 10 cm below the level of the tibial tubercle (Figure 3).

A proximally deep surgical dissection was done without arthrotomy and therefore the patella was not rotated. Distally the anterior compartment musculature dissected off from the proximal tibia and routine fasciotomy of the anterior compartment was done with a Mayo scissors through the distal end of the incision to prevent postoperative compartment syndrome. The tibial tubercle was osteomized to a distance approximately 10 cm below the patellar tendon attachment. Borders of osteotomy site marked with oscillating saw and osteotomy was done with osteotomes. The osteotomy site slowly elevated with larger osteotomes, care was taken to avoid deattachment of distal part. Three cortical strut (5x50 mm) allografts were placed under the elevated tubercle to catch on the targeted elevation of 12 mm with predictable loss due to graft resorption (Figure 4).

The bone graft was maintained firmly in position by the compressive force of the elevated tibial tubercle shingle. Anteroposterior and lateral x-rays were obtained and the range of motion was checked to make sure that there was no instability. A hemovac drain was inserted before wound closure. Tendon insertion was not medialized in the coronal plane. A hinged knee brace was applied for six weeks



**Figure 3.** Planning osteotomy of a right knee.



**Figure 4.** Maquet procedure of a right knee.

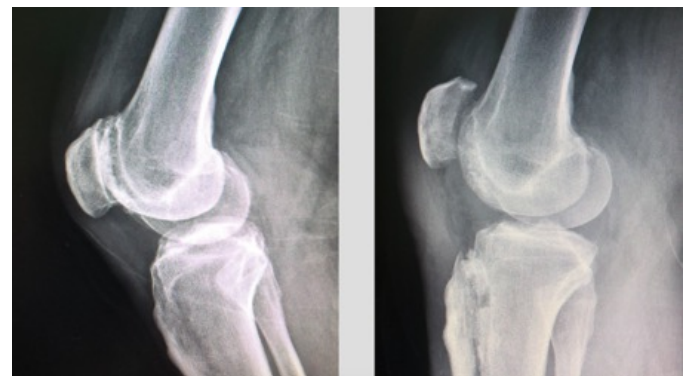and active movements were begun gradually one week after the operation with under control of this brace. Weight bearing with crutches was allowed as rapidly as tolerated. When healing was observed radiologically, patients were allowed to return to full activities. All procedures were performed by the same surgeon (M.B) using similar technique and similar postoperative management (Figure 5).

Patients were clinically assessed preoperatively and at the final assessment postoperatively using the International Knee Documentation Committee Subjective Knee Evaluation Form (IKDC 2000) (13) and the Kujala Anterior Knee Pain Scale (14). Also at the final assessment all patients were reviewed for postoperative complications and radiographic evaluation such as wound problems, nonunion, osteomyelitis, progressing of osteoarthritis, magnitude of tubercle elevation and complications of graft placement.

Data were analyzed using IBM SPSS Statistics (version 21.0 for Windows; SPSS Inc, Chicago, IL). The normality of distribution of continuous variables was determined with the Kolmogorov-Smirnov test. Paired t test was used to determine the statistical significance of differences between preoperative and at the final assessment clinical measurements (IKDC 2000 and Kujala). The relationship between age, amount of elevation, arthroscopic ICRS Grade and IKDC-Kujala scores were analyzed using Pearson's correlation coefficient (for normally distributed variables) and Spearman's rho correlation coefficient (for non-normally distributed variables). P values < 0.05 were considered to be statistically significant. The study protocol was approved by local ethics committee (approval number: E-90139838-000-14821). The study was conducted in accordance with the principles of the Declaration of Helsinki.

## Results

Twelve of 13 cases in this study obtained a clinical union of the osteotomy site by the eighth postoperative week. All



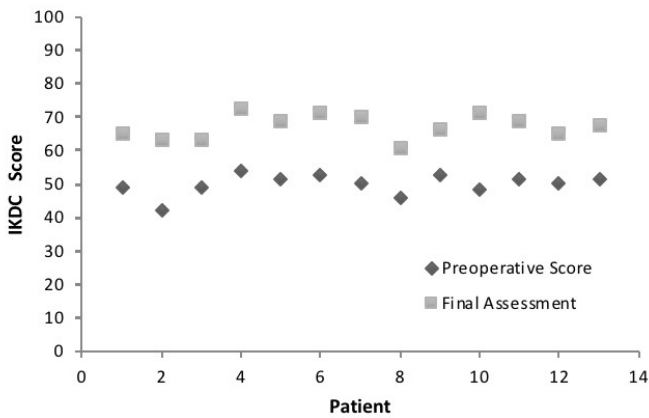
**Figure 5.** Pre-and postoperative lateral x-rays of a right knee.

of the operated knees regained their preoperative range of motion three months after surgery. At last follow-up, tibial tubercle elevation on radiographic evaluation ranged from 7 to 11 mm (mean, 9.4 mm). All patients had elevations less than targeted elevation, 12 mm.

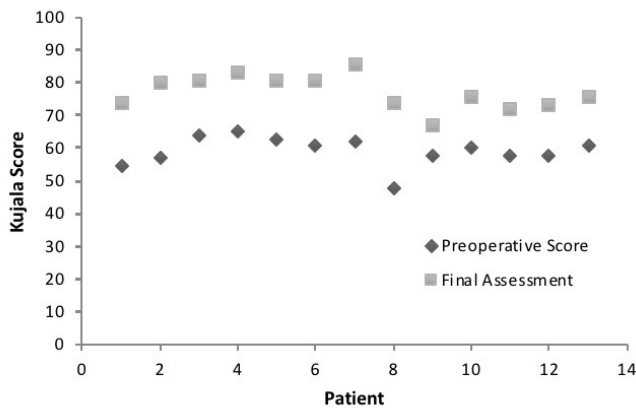
The mean IKDC 2000 score increased from 50.1 preoperatively to 67.4 at the final assessment ( $p < 0.001$ ) and the mean Kujala Anterior Knee Pain Scale score increased from 59.2 preoperatively to 77.2 at the final assessment ( $p < 0.001$ ) (Table 2, Figure 6 and 7)

Signs of progressive osteoarthritis in patellofemoral compartment founded in 3 knees but no difference in outcome was detected ( $p > 0.05$ ). The patients that high intraoperative ICRS grades has bad preoperative IKDC scores ( $p < 0.05$ ) and that is not any relation between intraoperative ICRS grades and postoperative IKDC and Kujala scores ( $p > 0.05$ ). Also age and amount of elevation was not related with outcome scores ( $p > 0.05$ ).

The Maquet osteotomy is known for causing a relatively high incidence of complications: we observed 1 major and



**Figure 6.** Longitudinal analysis of IKDC scores preoperatively and at the final assessment.



**Figure 7.** Longitudinal analysis of Kujala scores preoperatively and at the final assessment.

1 minor complication in 13 procedures. We encountered one persistent wound drainage due to allograft after three weeks postoperatively and regard as nonunion. She was treated with replacement of allograft with iliac crest autograft and went on to union successfully. Minor delay in wound healing occurred in one patient, and it was resolved with further intervention. There were no other complications, such as osteomyelitis, iatrogenic fracture, bone graft displacement, thromboembolic complications, and so on.

## Discussion

When local conditions and healthcare system are not suitable for a surgical technique, an inexpensive and implant-free alternative should come to mind. The purpose of this study is to consider such an alternative.

Osteotomies around the knee have been established as effective surgical procedures for the treatment of degenerative arthritis. The contact stress can be reduced with osteotomies by correcting joint alignment and increasing the weight-bearing area. In 1965 Coventry described the high tibial osteotomy for degenerative arthritis of the knee. After the success of this osteotomy, similar protocols on other joints have become more popular [15].

Arthroscopic debridement, local excision of defects with drilling of the subchondral bone, patellectomy, patellar resurfacing, patellofemoral arthroplasty and Maquet osteotomy have been using for isolated patellofemoral osteoarthritis. Benefits of arthroscopic debridement and open shaving depend on excision of damaged cartilage. By those procedures fibrillated and fragmented cartilage excised and secondary inflammation or synovitis could decrease. However, in this method there is no direct intervention to pathophysiology of disease. Patellectomy is no longer used in patellofemoral osteoarthritis and at the present time it has historical significance. Removal of the patella may reduce the pain at the patellofemoral joint but also diminishes the power and function of the quadriceps mechanism. Patellofemoral resurfacing and patellofemoral arthroplasty are effective surgical procedures in patellofemoral osteoarthritis but aseptic loosening and periprosthetic infection are common problems in these procedures despite improvements in bearing surface materials [1, 2].

In 1963 [3], Maquet introduced a method of advancement of the tibial tubercle designed to reduce the joint reactive force in the patellofemoral articulation. Biomechanically, altered position of the tibial tubercle results in increasing the angle formed by the vectors of the quadriceps and patellar tendons, thereby diminishing the compressive force. In addition, the anteriorly displaced patellar tendon now acts at the end of a longer level arm that results in an increased mechanical advantage.

There is controversy about the amount of anterior elevation of the Maquet procedure. Maquet [4] calculated that a 50% reduction of the patellofemoral compressive force achieved by 2 cm advancement of the patellar tendon. Because of high rates of skin problems in various studies, some authors had started to investigate the efficiency of different amounts of anterior elevation. Ferguson et al. [7] biomechanically analyzed anterior tubercle advancement using intra-articular pressure transducers, found that patellofemoral stress was relieved more than 80% at 1.25 cm elevation of the tibial tubercle and no significant decrease was achieved by further elevations. In another study, Pan et al [16] found that 2 cm elevation of the anterior tibial tubercle lowers the patellofemoral anterior articular pressure more successfully than does a 1 cm elevation in an invitro experimental study. They also investigated the effect of tibial shingle length on patellofemoral pressures and they found that usage of short tibial shingle could deteriorate clinical results. In our surgical procedure we elevated tibial tubercle approximately 12 mm in order to avoid wound complications as this elevation has been reported effective in the literature. Our results seem to concur with the previous studies and good functional results were achieved.

We used cortical strut allografts in order to elevate the tibial tubercle unlike the previous reports of Maquet osteotomy which were done by iliac autografts. Using allografts prevented morbidity of obtaining autograft from iliac crest and reduced postoperative pain. Our results showed no difference regarding to osteotomy site union compared to autogenous grafting in previous reports. Only in one case did we have to replace allograft with iliac crest

autograft due to persistent wound drainage three weeks postoperatively.

As expected, that is a correlation between intraoperative bad ICRS grade and preoperative bad IKDC and Kujala scores, this show that patients' patellar cartilage damages directly affect the patients activity level and anterior knee pain. But postoperative IKDC and Kujala scores are not affected from primarily intraoperative ICRS grades. In our opinion patients expectations from surgery and compliance to physiotherapy were the other factors that affect the postoperative knee scores.

We did not observe as many wound complications as previously published articles. [4, 8, 17, 18]. Because of this problem Kadambande [19] described an anterolateral incision which preserves the blood supply and lymphatic drainage and minimizes the risk of infection and osteomyelitis. We think that our incision which extends up to quadriceps tendon was adequate length and so the flaps of incision preserves their vascularity despite elevated tibial tubercle. After surgery the elevated tubercle became more prominent like Osgood-Schlatter's disease, but none of the patients had a complaint about this appereance.

Maquet osteotomy was criticized by some of authors because of being ineffectual over time. Radin et al [20] evaluated the long-term results of maquet procedure which had 6.1 years follow-up period. In their study the sum of excellent and good results was 86%. Also Schmid [21] investigated 30 patients after ten to 20 years (mean 16 years) from maquet osteotomy surgery. He found 80% of patients were rated very good or good results. The last long-term research on this procedure was investigated by Fonseca et al [22]. The postoperative follow-up period of 23 patients were  $27.2 \pm 3.1$  years. They found that 10 patients (40%) were pain free after more than twenty years and others had an average period without pain of  $19.1 \pm 6.1$  years. The weakness of this article was 80% of the initial population (116 patients) was lost during follow-up. When we look at these long-term studies, we can say that Maquet osteotomy is an effective procedure. Despite the loss of elevation according to graft resorption, our results show similar results with previous reports [3, 8, 9, 11, 17, 20, 21, 23].

There are several limitations to our study. This study was limited by its retrospective design and small number of patients included. Another limitation is the relatively short follow-up time. Also we did not use a control group to compare the results and we did not evaluate the radiologic outcomes. However, we think that we have reached our purpose by bringing this forgotten surgical technique back to mind.

## Conclusion

Despite being abandoned in recent years, this osteotomy should be kept in mind because of its positive effect on clinical outcomes. Although it looks like an extensile surgery, by careful patient selection and careful surgical technique, this osteotomy is a strong alternative for arthroplasty in isolated patellofemoral arthritis.

## Ethical approval

The study protocol was approved by the Giresun University Ethics Committee (Approval Number: E-90139838-000-14821).

## References

1. Dejour D, Saggin PR, Kuhn VC. Disorders of the patellofemoral joint. In: Scott WN (ed): Insall & Scott, surgery of the knee. Philadelphia: Elsevier, 2012, pp. 843-884.
2. Miller RH, Azar FM. Knee injuries. In: Azar FM (ed): Campbell's operative orthopaedics. Philadelphia: Elsevier, 2017, pp. 2122-2297.
3. Maquet P. Biomechanical treatment of femoro-patellar arthrosis: advancement of the patellar tendon. Rev Rhum Mal Osteoartic 1963, 30(Dec):779-83.
4. Maquet P. Advancement of the tibial tuberosity. Clin Orthop Relat Res 1976; 115:225-30.
5. Cox AJ. Biomechanics of the patello-femoral joint. Clinical Biomechanics 1990; 5(3):123-30.
6. Levine RB, Stassi J, Karasick D. The maquet principle. Anterior displacement of the tibial tubercle in the treatment of patellofemoral disorders: radiologic appearance. Skeletal Radiol 1985; 13(4):291-4.
7. Ferguson AB, Brown TD, Fu FH, Rutkowski R. Relief of patellofemoral contact stress by anterior displacement of the tibial tubercle. J Bone Joint Surg Am 1979; 61(2):159-66.
8. Hirsh DM, Reddy DK. Experience with maquet anterior tibial tubercle advancement for patellofemoral arthralgia. Clin Orthop Relat Res 1980; 148:136-9.
9. Hadjipavlou A, Helmy H, Dubravcik P, Heller L, Kerner M. Maquet osteotomy for chondromalacia patellae: avoiding the pitfalls. Can J Surg 1982; 25(3):342-5.
10. Liebau J, Nehring G, Hohle B, Hesse B. Results of the maquet/bandi tibial tuberosity ventralization. Zentralbl Chir 1983; 108(1):17-25.
11. Heatley FW, Allen PR, Patrick JH. Tibial tubercle advancement for anterior knee pain. A temporary or permanent solution. Clin Orthop Relat Res 1986; 208:215-24.
12. Brittberg M, Winalski CS. Evaluation of cartilage injuries and repair. J Bone Joint Surg Am 2003; 85-A Suppl 2:58-69.
13. Anderson AF, Irrgang JJ, Kocher MS, Mann BJ, Harrast JJ. The international knee documentation committee subjective knee evaluation form: normative data. Am, J. Sports Med 2006; 34(1):128-35.
14. Kujala UM, Jaakkola LH, Koskinen SK, Taimela S, Hurme M, Nelimarkka O. Scoring of patellofemoral disorders. Arthroscopy 1993; 9(2):159-63.
15. Coventry MB. Osteotomy of the upper portion of the tibia for degenerative arthritis of the knee. A preliminary report 1965 Jul; 47:984-90.
16. Pan HQ, Kish V, Boyd RD, Burr DB, Radin EL. The maquet procedure: effect of tibial shingle length on patellofemoral pressures. J Orthop Res 1993; 11(2):199-204.
17. Radin EL. The Maquet procedure-anterior displacement of the tibial tubercle. Indications, contraindications, and precautions. Clin Orthop Relat Res 1986; 213:241-8.
18. Mendes DG, Soudry M, Iusim M. Clinical assessment of maquet tibial tuberosity advancement. Clin Orthop Relat Res 1987; 222:228-38.
19. Kadambande SS, Auyeung J, Ghandour A, Mintowt-Czyz W. A review of wound healing following maquet osteotomy. Knee 2004; 11(6):463-7.
20. Radin EL, Pan HQ. Long-term follow-up study on the maquet procedure with special reference to the causes of failure. Clin Orthop Relat Res 1993; 290:253-8.
21. Schmid F. The maquet procedure in the treatment of patellofemoral osteoarthritis. Long-term results. Clin Orthop Relat Res 1993; 294:254-8.
22. Fonseca F, Oliveira JP, Marques P. Maquet III procedure: what remains after initial complications-long-term results. J Orthop Surg Res 2013; 8:11.
23. Rappoport LH, Browne MG, Wickiewicz TL. The maquet osteotomy. Orthop Clin North Am 1992; 23(4):645-56.