



Intra-Abdominal injuries in isolated thoracolumbar transverse process fractures

Levent Sahin^{a,*}, Murat Kayabas^b

^aKafkas University, Medical School, Department of Emergency Medicine, Sehitler Street, Kars 36100, Turkey

^bKafkas University, Medical School, Department of Neurosurgery, Sehitler Street, Kars 36100, Turkey

Abstract

ARTICLE INFO

Keywords:

Vertebra; isolated transverse process fracture; intra-abdominal injury

Received: Oct 19, 2021

Accepted: Jan 11, 2022

Available Online: Mar 18, 2022

DOI:

[10.5455/annalsmedres.2021.10.591](https://doi.org/10.5455/annalsmedres.2021.10.591)

Aim: We aimed to investigate the frequency of intra-abdominal injury in posttraumatic isolated transverse process fractures (iTPF) and the factors affecting the injury, especially the effect of the size of the fracture on the injury.

Materials and Methods: Patients' age, gender, trauma type determined by Computed Tomography (CT), fracture localization, separation distance of the fracture from the vertebral body, neurological status, and non-vertebral organ injury, if any, were evaluated retrospectively.

Results: Intra-abdominal injury was detected in 16 of 70 patients with iTPF included in the study. The most common cause of iTPF was falls. Those with multiple TPF had a higher rate of intra-abdominal injury. Liver injury was the most common type of intra-abdominal injury. The separation distance of iTPFs from the vertebral body was mean 5.81 ± 1.9 mm in patients with intra-abdominal injury and 3.90 ± 1.69 mm in patients without intra-abdominal injury, and the separation distance was statistically significantly higher in patients with intra-abdominal injury ($p < 0.05$).

Conclusion: This study showed that intra-abdominal injury may be common in cases of iTPF. The severity of the trauma, the high number of fractures, and the length of the fracture distances have caused organ damage to be seen more frequently.



Copyright © 2022 The author(s) - Available online at www.annalsmedres.org. This is an Open Access article distributed under the terms of Creative Commons Attribution-NonCommercial-NoDerivatives 4.0 International License.

Introduction

Transverse processes (TP) are the vertebral sections that protrude to the sides, support the spine, and are attached to strong muscles [1]. Isolated transverse process fractures (iTPF) are fractures that do not spread into the lamina, pedicle or facet and are considered stable [2, 3]. iTPFs detected in the post-traumatic emergency department are generally accepted as fractures that do not require neurosurgery, or orthopedic intervention and do not cause neurological deficits [4].

Transverse process fractures (TPF) often occur after high-energy trauma [5]. The preference for direct radiographs has decreased due to overlooked existing fractures in diagnosis, and the detection of TPFs has increased further with the widespread use of computed tomography (CT) scanning [6]. TPF was detected in 7.3% of patients in post-traumatic CT scans [7]. As a result of mild clinical course, neurological stability, low hospitalization requirement, and symptomatic treatment; the demand for orthopedic or neurosurgery consultations for iTPF patients is

decreasing [8]. However, it has been reported that intra-abdominal, genitourinary, or retroperitoneal injuries accompanying iTPF cases are common [8, 9].

We have seen that the relationship between the separation distance of the fracture from the vertebral body and intra-abdominal injury has not been investigated in previous studies on iTPFs. Our study aimed to evaluate the frequency and types of intra-abdominal injuries and the factors that may affect the injury in thoracolumbar iTPF cases.

Materials and Methods

In this study, which was approved by the Ethics Committee of Kafkas University Faculty of Medicine, date 22.09.2021 and number 200, thoracolumbar iTPF cases detected by CT between 2018 and 2021 were examined. The patient population consisted of patients who applied to emergency department after acute vertebra trauma. Patient information was obtained from the hospital database and archive files. iTPF; It was defined as the absence of a fracture in the lamina, corpus, facet, or pedicle other than the transverse process. Patients whose images could

*Corresponding author:

Email address: levsahin44@gmail.com (Levent Sahin)

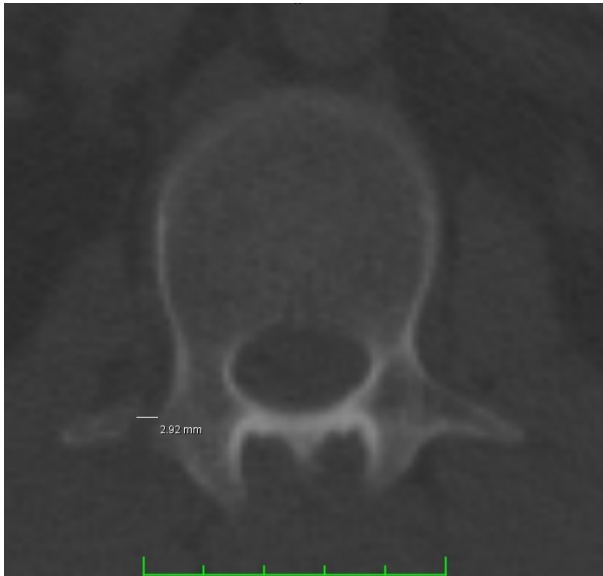

Figure 1. Right T12 TPF (axial section)

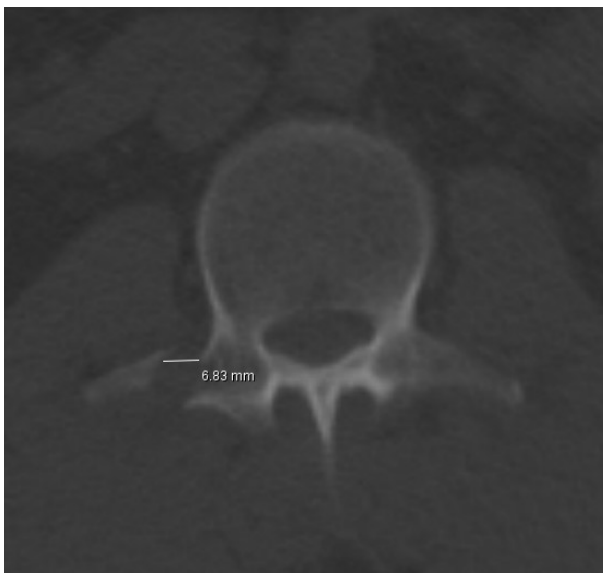

Figure 2. Right L2 TPF (axial section)

not be accessed in the radiological report system, who had multiple injuries, having a diagnosis of neoplastic or a previous pathological fracture, were under the age of 18 were excluded from the study.

The age, gender, trauma type, fracture location, number of fractures (single or two or more were considered as multiple fractures), a distance of the fracture from the vertebral body, and non-vertebral organ injury status of the patients with iTPF were evaluated from the medical records. Neurosurgeons measured the separation distance of the fracture from the vertebral body. These measurements were also confirmed by the report of the radiologists. Non-vertebral organ injuries were detected by radiologist reports. The separation distance of the fracture from the vertebral body was measured in millimeters in axial sections using the PACS system (Figure 1, Figure 2).

In patients with multiple fractures, the fracture with the highest separation distance measurement was included in

Table 1. Average age of the groups

	iTPF	Abdominal injury + iTPF	Surgical Treatment	Conservative Treatment
Fe- male	42.91 n=24	44.8 n=5	51.5 n=2	40.33 n=3
Male	43.15 n=46	40.45 n=11	40.5 n=4	40.47 n=7
To- tal	43.07 n=70	41.81 n=16	44.16 n=6	40.4 n=10

(iTPF : Isolated transverse process fractures)

Table 2. Fracture etiologies and localizations

Parameters	iTPF %(n)	Abdominal injury %(n)
Male	65.8 (n=46)	68.75 (n=11)
Female	34.2 (n=24)	31.25 (n=5)
Fall	41.4 (n=29)	43.7 (n=7)
MVA	35.7 (n=25)	37.5 (n=6)
Blunt trauma	22.9 (n=16)	18.7 (n=3)
Lumbar single	28.5 (n=20)	18.7 (n=3)
Lumbar multiple	48.5 (n=34)	56.5 (n=8)
Thoracic single	2.9 (n=2)	6.25 (n=1)
Thoracic multiple	2.9 (n=2)	0
Thoracic + Lumbar	17.2 (n=12)	18,7 (n=3)
Single fracture	31,4 (n=22)	25 (n=4)
Multiple fractures	68,6 (n=48)	75 (n=12)

(iTPF: Isolated transverse process fractures, MVA: Motor vehicle accident)

the evaluation.

Statistical Analysis

IBM SPSS 22 program was used for statistical analysis of the data. Frequency distributions and crosstabs were used as analysis methods. Statistical analyzes were performed using the significance test (T-test) of the difference between the two means. The result of $p < 0.05$ was considered statistically significant in the tests.

Results

A total of 70 patients with iTPF were included in the study. The mean age for all patients was 43.07 years (18-84 years). Intra-abdominal injuries were detected in a total of 16 patients, 5 female, and 11 male. There was no statistical difference between genders in the frequency of iTPF and intra-abdominal injury (Table 1).

Considering the etiology of iTPF patients, the most common cause was falling with 41.4%. The most common type of trauma causing intra-abdominal injury was falling with 43.8%. Their localization was in the lumbar region with 84.3% TPF and 68.6% of patients had TPF two or more. TPF was most common in the lumbar region in patients with intra-abdominal injuries, and it was two or more in 75% of these patients. We have seen that as the number

Table 3. Characteristics of 16 patients with intra-abdominal injury after iTPF

Cases	Sex	Age	Side	Localization	Single / Multipl	Organ	Treatment
1 Fall	F	63	Right	L1-2	Multiple	Liver	Conservative
2 Fall	F	51	Right	L2-3-4	Multiple	Liver	Surgery
3 Fall	F	26	Right	L2-3	Multiple	Kidney	Conservative
4 Fall	M	25	Right	L1-2	Multiple	Liver	Conservative
5 Fall	M	56	Left	T12-L1-L2	Multiple	Spleen	Conservative
6 MVA	F	32	Left	L1-2-3	Multiple	Spleen	Conservative
7 MVA	M	44	Right	L3-4	Multiple	Liver	Conservative
8 MVA	M	33	Right	T12-L1-L2	Multiple	Liver	Surgery
9 MVA	M	36	Right	L2-3	Multiple	Kidney	Surgery
10 MVA	M	38	Right	L3-4	Multiple	Kidney	Conservative
11 Blunt trauma	M	27	Right	T11-12-L1	Multiple	Liver	Surgery
12 Blunt trauma	M	48	Left	L1-2	Multiple	Spleen	Surgery
13 Fall	M	45	Right	T12	Single	Liver	Surgery
14 Fall	M	34	Left	L3	Single	Kidney	Conservative
15 MVA	F	52	Left	L3	Single	Ureter	Surgery
16 Blunt trauma	M	59	Left	L1	Single	Spleen	Conservative

(MVA: Motor vehicle accident, L: Lumbar, T: Thoracal, K: Kidney)

Table 4. T-test of study data

	iTPF	Abdominal injury + iTPF	Surgical Treatment	Conservative Treatment
Fe- male	42.91 n=24	44.8 n=5	51.5 n=2	40.33 n=3
Male	43.15 n=46	40.45 n=11	40.5 n=4	40.47 n=7
Total	43.07 n=70	41.81 n=16	44.16 n=6	40.4 n=10

Groups N Mean Ss sd t p

of fractures increases, the probability of intra-abdominal bleeding increases. However, this result did not differ statistically. When we examined 16 patients with intra-abdominal injuries; there were liver injuries in 7 (41.2%) patients, kidney in 4 (29.4%) patients, spleen in 4 (23.5%) patients, and ureter in 1 (5.9%) patient. Surgery was performed in seven patients. Mortality did not occur in any patient (Table 2, Table 3).

When the measurements of the separation of TPFs from the vertebral body were made, it was found that the separation distance from the vertebral body was 4.32 ± 1.91 mm on average, 5.81 ± 1.9 mm in patients with intra-abdominal injuries and 3.90 ± 1.69 mm in those without intra-abdominal injuries. There was a significant difference between the mean separation distance of TP from the vertebral body in patients with intra-abdominal injury and the mean separation distance of TP from the vertebral body in patients without intra-abdominal injury ($t=3.836$, $p < 0.05$). (Figure 3).

The calculated effect value ($d=0.93$) shows that the difference is large. In patients with intra-abdominal injury, the separation distance of the TP from the vertebral body is greater. According to this result, it can be said that the increase in the separation distance of the TP from the vertebral body is effective on intra-abdominal bleeding (Table

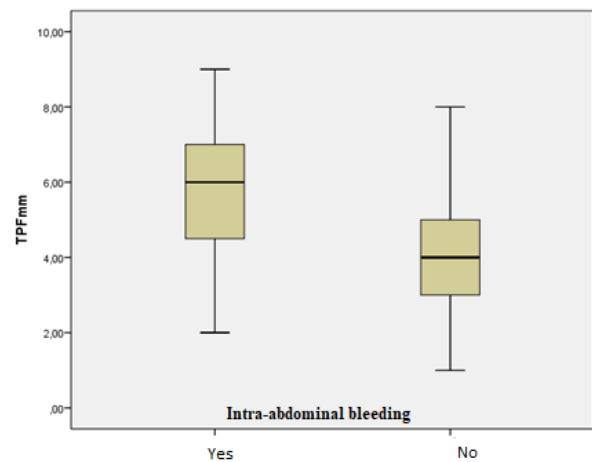


Figure 3. The relationship between TPF dimensions and the presence of intra-abdominal injury

4).

Otherwise, it was observed that there was no neurological deficit in the retrospective examination notes of the patients included in the study.

Discussion

Thoracolumbar iTPF is important injuries as they occur in approximately 10% of patients with severe vertebral trauma [10]. Motor vehicle accidents (MVA) followed by falls have been reported as the most common cause of iTPFs. Although less common, assault, bicycle accidents, penetrating injuries, and sports accidents are also included in the etiology [11]. In our study, falls were the most common cause, followed by MVA. iTPFs are not associated with neurological deficit or structural instability [12, 13].

In this study, no signs of neurological damage were observed in any patient with iTPF. Physical therapy support is rarely recommended with symptomatic treatments such as painkillers, muscle relaxants, and orthoses in TPFs

where mechanical stabilization is considered unnecessary [5, 9]. Most studies have shown that surgical intervention or corset application is not required in iTPF [4, 14]. Similar to the literature, no surgical intervention was performed for fracture in the iTPF patients of our study. Patients with no additional pathology were discharged with analgesia and corset recommendations.

Since TPFs generally occur after high-energy trauma, the number of fractures indicates the severity of the injury and is often seen in the lumbar vertebrae [16]. The reason for this is that the psoas major and quadratus lumborum muscles create a load on the TPs with strong traction during trauma [17]. The fact that L2 and L3 TPs are thin, long, and do not have structures to provide support causes more fractures. The other frequently broken lumbar vertebra is L1 [13]. iTPFs are stable spinal fractures of minimal concern for neurological impairment and, although biomechanically insignificant, multiple sites of injury can be observed because they are associated with high-speed mechanisms [3]. The high rate of intra-abdominal injuries detected in iTPF in our study indicates that additional pathologies that are clinically overlooked should be paid attention to in these cases. In the presence of TPF, hemodynamic parameters should be monitored and ultrasonography (USG) or contrast-enhanced abdomen CT of should be used for a possible intra-abdominal injury [18]. However, USG is not sensitive enough to exclude intra-abdominal injury, so CT is preferred for definitive diagnosis [19].

Non-vertebral organ injuries are more common especially in TPFs of lumbar vertebrae [7]. The results we obtained in this study are consistent with the literature, and TPF was present in the lumbar vertebrae in 93% of patients with intra-abdominal injuries.

In iTPFs, liver, kidney or spleen injuries can be seen most commonly, and rarely bladder rupture and ureteral injuries [1, 7]. In our study, the most common liver injury was seen at a similar rate. We also found that the presence of multiple iTPF increased intra-abdominal injury.

There is no previous study examining the relationship between the separation distance of TPs from the vertebral body and intra-abdominal injury in iTPFs. Our study is a first in this context. In the data we obtained, we observed that the separation distance of TPFs from the vertebral body is greater in patients with intra-abdominal injuries. We can say that the increase in separation distance is effective on the intra-abdominal injury.

Limitations

Since the study was retrospective and the information on the Injury Severity Scale was not included in every patient in the epicrisis notes, it was not used as data in the study. Another limitation is the inability to follow-up the patients after discharge because they did not come to the controls.

Conclusions

In this study, it was shown that in addition to the large number of iTPFs, an increase in the separation distance

of the TP from the vertebral body may increase intra-abdominal injury. Especially in the presence of iTPF, emergency physicians should be more careful.

References

1. Miller CD, Blyth P, Civil IDS. Lumbar transverse process fractures—a sentinel marker of abdominal organ injuries. *Injury* 200; 31(10): 773-776.
2. Arena JD, Kvint S, Ghenbot Y, et al. Thoracolumbar Transverse Process Fractures Are More Frequently Associated with Non-spinal Injury than Clinically Significant Spine Fracture. *World Neurosurgery* 2021; 146: 1236-1241.
3. Bui TT, Nagasawa DT, Lagman C, et al. Isolated Transverse Process Fractures and Markers of Associated Injuries: The Experience at University of California, Los Angeles, *World Neurosurgery* 2017; 104: 82-88.
4. Bradley LH, Paullus WC, Howe J, Litofsky NS. Isolated transverse process fractures: spine service management not needed. *Journal of Trauma and Acute Care Surgery* 2008; 65(4): 832-836.
5. Homnick A, Lavery R, Nicastrro O, Livingston DH, Hauser CJ. Isolated thoracolumbar transverse process fractures: call physical therapy, not spine. *Journal of Trauma and Acute Care Surgery* 2007; 63(6): 1292-1295.
6. Hauser CJ, Visvikis G, Hinrichs C, et al. Prospective validation of computed tomographic screening of the thoracolumbar spine in trauma. *Journal of Trauma and Acute Care Surgery* 2003; 55(2): 228-235.
7. Patten RM, Gunberg SR, Brandenburger DK. Frequency and importance of transverse process fractures in the lumbar vertebrae at helical abdominal CT in patients with trauma. *Radiology* 2000;215:831-4.
8. Nagasawa DT, Bui TT, Lagman C, et al. Isolated transverse process fractures: a systematic analysis. *World Neurosurg* 2017;100:336-341.
9. Gültekin G, Yılmaz H, Atcı İB. Psoas Muscle Hematoma Related to Multi-Level Lumbar Vertebrae Transverse Process Avulsion Fracture: A case report. *Türk Nöroşir Der* 2016; 26(1): 75-78
10. Dai LY, Yao WF, Cui YM. Thoracolumbar fractures in patients with multiple injuries: diagnosis and treatment- A review of 147 cases. *J Trauma* 2004;56:348–355.
11. Akinpelu BJ, Zuckerman SL, Gannon SR, Westrick A, Shannon C, Naftel RP. Pediatric isolated thoracic and/or lumbar transverse and spinous process fractures. *J Neurosurg Pediatr* 2016; 17:639-644.
12. National Spinal Cord Injury Statistical Center. Spinal cord injury: facts and figures at a glance. Available at: www.spinal-cord.uab.edu. Accessed December 17, 2009.
13. Agrawal A, Srivastava S, Kakani A. Isolated transverse process fracture of the lumbar vertebrae. *Journal of Emergencies, Trauma and Shock* 2009; 2(3): 217.
14. Tian X, Ji-Wei T, Shuang-Hai D, Lei W, Qing-Hua Z. Non-spinal-associated injuries with lumbar transverse process fractures, *Journal of Trauma and Acute Care Surgery* 2013; 74(4): 1108-1111.
15. Gertzbein SD, Khoury D, Bullington A, St John TA, Larson AI. Thoracic and lumbar fractures associated with skiing and snowboarding injuries according to the AO Comprehensive Classification. *Am J Sports Med* 2012; 40: 1750-1754.
16. Boulter JH, Lovasik BP, Baum GR, et al. Implications of isolated transverse process fractures: is spine service consultation necessary? *World Neurosurgery* 2016; 95: 285-291.
17. Holmes JF, Miller PQ, Panacek EA, Lin S, Horne NS, Mower WR. Epidemiology of thoracolumbar spine injury in blunt trauma. *Acad Emerg Med* 2001;8: 866-872.
18. Barker PJ, Urquhart DM, Story IH, Fahrner M, Briggs CA. The middle layer of lumbar fascia and attachments to lumbar transverse processes: implications for segmental control and fracture. *Eur Spine J* 2007; 16: 2232-2237.
19. Dağlar B, Bayrakçı K, Taşbaş BA, et al. Importance of lumbar vertebra transverse process fractures in multi trauma patients who had undergone emergent laparotomy. *Turkish Journal Of Trauma & Emergency Surgery* 2005; 11(1): 58-63.
20. Mama N, Jemni H, Achour NA, et al. Abdominal trauma imaging. *Abdominal Surgery*, Ed: Derbel F. 2012. Doi: 10.5772/50426