



# Knotted all-suture anchors and knotted titanium suture anchors are not clinically superior to each other in isolated type II slap tear repair: A minimum 2-year follow-up

Bertan Cengiz\*

Acibadem Kayseri Hospital Department of Orthopaedics and Traumatology, Kayseri, Turkey

## ARTICLE INFO

### Keywords:

Shoulder arthroscopy; suture anchors; SLAP

Received: Sep 06, 2021

Accepted: Nov 02, 2021

Available Online: Mar 18, 2022

### DOI:

[10.5455/annalsmedres.2021.09.543](https://doi.org/10.5455/annalsmedres.2021.09.543)

## Abstract

**Aim:** This study aimed to compare the mid-term clinical outcomes of using knotted titanium suture anchors (TSA) and knotted all-suture anchors (ASA) in the surgical repair of type II superior labral anterior to posterior (SLAP) lesions.

**Materials and Methods:** In this retrospective cohort study, data of patients who underwent isolated SLAP repair in a single center between 2014 and 2019 were examined. American Shoulder and Elbow Surgery (ASES) score, University of California Los Angeles (UCLA) shoulder score, and visual analog scale (VAS) were used for functional assessment preoperatively and at the final follow-up.

**Results:** SLAP repair was performed with ASA in 24 of 44 patients, while 20 received treatment with TSA. Overall, 61.4% of the patients were male and the mean age was  $34.95 \pm 10.67$  years. No significant difference was found between the groups in terms of gender, age, affected side, sports activity, and follow-up time ( $p = 0.865$ ,  $p = 0.865$ ,  $p = 1.0$ ,  $p = 0.967$ , and  $p = 0.846$ , respectively). ASES, UCLA, and VAS scores at the last follow-up were significantly better than the preoperative scores in both groups ( $p < 0.001$ , for all). No significant difference was noted between the groups in terms of both preoperative and last follow-up scores ( $p > 0.05$ ). Re-rupture was detected in one patient in each group, and tenotomy was performed as revision surgery.

**Conclusions:** The mid-term clinical results of using knotted TSAs or knotted ASAs in arthroscopic surgery for isolated type II SLAP lesions were comparable. No significant difference was found between the groups in terms of functionality, satisfaction, and pain.



Copyright © 2022 The author(s) - Available online at [www.annalsmedres.org](http://www.annalsmedres.org). This is an Open Access article distributed under the terms of Creative Commons Attribution-NonCommercial-NoDerivatives 4.0 International License.

## Introduction

The increasing use of arthroscopy in the diagnosis and treatment of shoulder pathologies has enabled the identification of new, more specific pathologies. Superior labral anterior to posterior (SLAP) lesions located in the immediate vicinity of the insertion of the long head of the biceps tendon constitute a substantial portion of these newly described lesions. The site where the long head of the biceps attaches to the superior glenoid in the shoulder joint is called SLAP, and tears of this structure are called SLAP lesions [1, 2].

The classification of SLAP lesions was performed by dividing patients into four subtypes by Snyder, who was also the first to describe SLAP repair based on its morphological patterns [3]. Type II SLAP lesion is the most common type and has a marked degenerative appearance and

wear that involves the superior labrum. The prominent finding that distinguishes type II tear from other SLAP lesion types is the detachment of the biceps anchor from the superior glenoid tubercle, and thus, the biceps–labral complex is unstable. Patients mostly complain of shoulder pain and a ‘catching’ sensation during overhead activities, which is caused by compression of the unstable area [2]. Clinical diagnosis of SLAP lesions is quite difficult, as they may be masked by other pathologies. Owing to the complex structure of the labrum and variations in normal anatomy, shoulder arthroscopy is accepted to be the gold standard for diagnosis [4]. Conservative treatments have limited efficacy in type II SLAP cases, so arthroscopic surgery (especially in young people) is often performed [5]. Suture anchor options that can be applied in arthroscopic SLAP repair vary, and their superiority over each other is still being investigated. Although various studies have reported that the type of suture anchors used in lesion repair may affect clinical results [6, 7], some other studies have

\*Corresponding author:

Email address: [drbertan@gmail.com](mailto:drbertan@gmail.com) ( Bertan Cengiz)

reported limited effects and the authors suggested that the most appropriate suture anchoring option should be determined by considering other advantages and disadvantages [8-12].

To the best of our knowledge, no study has compared post-operative results according to the type of suture anchors used in treatment in cases with isolated type II SLAP tears. Our hypothesis was that the type of anchor used in surgery might affect clinical outcomes. Thus, in this study, we aimed to compare the mid-term clinical outcomes of using knotted titanium suture anchors (TSA) or knotted all-suture anchors (ASA) in type II SLAP lesion repair.

## Materials and Methods

In this retrospective cohort study, the records of patients who underwent isolated SLAP repair at our clinic between 2014 and 2019 were examined. This study complied with the Declaration of Helsinki and was approved by the Ethics Committee and Institutional Review Board of Acibadem University (Date: 26.05.2021, No: 2021-09/44), and informed consent was obtained from each individual participant.

### Patients

#### Inclusion criteria

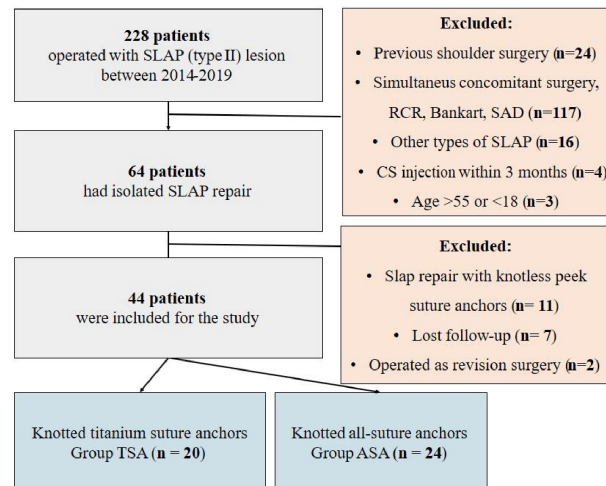
- Aged 18–55
- Minimum of 2-year follow-up
- Isolated SLAP lesion repair, without accompanying lesion
- No history of previous shoulder surgery
- Positive result in preoperative O'Brien test
- Type II SLAP lesion

#### Exclusion criteria

- Age < 18 or > 54 years
- Follow-up period less than two years
- Previous shoulder surgery
- Concomitant Bankart or rotator cuff lesion
- Active joint or systemic infection
- Corticosteroid injection within three months before surgery
- Other types of SLAP lesion except type II

Between 2014 and 2019, a total of 228 patients underwent arthroscopic SLAP lesion repair, and these patients had attended follow-up for a minimum of 24 months. Among these 228 patients, 64 had isolated SLAP tears, and 44 of these patients met the inclusion criteria (Figure 1).

While TSAs were used in SLAP repair procedures performed in our clinic between 2014 and 2016, ASAs were



**Figure 1.** Flow chart of the study. SLAP, superior labral anterior to posterior; TSA, titanium suture anchors; ASA, all-suture anchors; RCR, rotator cuff repair; SAD, sub-acromial decompression; CS, corticosteroid

used between 2017 and 2019. As such, patients were divided into two groups according to the type of suture anchors as follows: the ASA group, comprised of individuals who underwent repair with knotted ASAs (n = 24), and the TSA group, comprised of individuals who underwent repair with knotted TSAs (n = 20).

### Measurements

The variables recorded in the study included the characteristics of the patient (age, gender, and sports activity status), operational features (intervention side and the type and number of suture anchors), and clinical features (follow-up time, clinical scores, pain score, and complications).

#### Clinical assessment

The American Shoulder and Elbow Surgery (ASES) score, University of California Los Angeles (UCLA) shoulder score, and visual analog scale (VAS) scores were calculated and used for functional and clinical assessment preoperatively and at the final follow-up.

#### VAS score

Patients were asked to rate the level of pain they felt between 0 (no pain) and 10 (most severe pain).

#### ASES score

ASES score was calculated by evaluating daily functions and the pain level (VAS) (50% pain, 50% function). Higher scores indicate better functional outcomes [13].

#### UCLA shoulder score

UCLA is a summary assessment of physical examination findings and patients' pain, satisfaction level, and function. Higher scores indicate better outcomes [13].

### Operative technique

All arthroscopic type II SLAP lesion repair procedures were performed using either ASA (2.9 mm; JuggerKnot®, Biomet Inc., Warsaw, IN, USA) or TSA (3.5 mm; TWIN-FIX™, Smith & Nephew Inc., Andover, MA, USA). Depending on the lesion width, 1 or 2 suture anchors were used. In all procedures, the primary surgeon was the senior author (B.C.). Patients were placed in the lateral decubitus position in all procedures, and the posterior, anterior, and anterolateral portals were established in a standard manner to allow access to the SLAP lesion. The posterior portal was used for viewing, and anterior portals were used as working portals.

### Statistical analysis

All analyses were performed on SPSS version 21 (IBM Corp., Armonk, NY, USA). For the normality check, the Shapiro–Wilk test was used. Data are given as mean  $\pm$  standard deviation or median (1st quartile–3rd quartile) for continuous variables according to the normality of distribution and frequency (percentage) for categorical variables. Normally distributed variables were analyzed with independent samples t-test. Non-normally distributed variables were analyzed with the Mann-Whitney U test. Categorical variables were evaluated using Chi-square tests. Since parametric assumptions were not met in paired comparisons, the Wilcoxon signed-rank test was used to analyze non-normally distributed variables in repeated measurements. Between-group comparisons of these variables were performed by analyzing the differences between measurements with the Mann-Whitney U test. Two-tailed p values of less than 0.05 were considered significant.

### Results

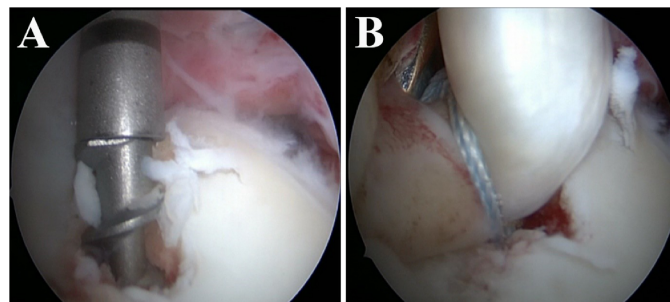
In this study, 24 of the 44 patients who underwent SLAP repair were in the ASA group, and 20 were in the TSA group. Overall, 61.4% of the patients were male, and the mean age was  $34.95 \pm 10.67$  years. No significant difference was found between the groups in terms of gender, age, side, sports activity, and follow-up time ( $p = 0.865$ ,  $p = 0.865$ ,  $p = 1.0$ ,  $p = 0.967$ , and  $p = 0.846$ , respectively) (Table 1).

The ASES, UCLA, and VAS scores at the last follow-up were significantly better than the preoperative scores in both groups ( $p < 0.001$ , for all). No significant difference was found between the two groups in terms of neither preoperative nor last follow-up scores ( $p > 0.05$ ) (Table 2).

In addition, re-rupture developed in one patient in each group, and tenotomy was performed as the revision surgery for both individuals.

### Discussion

Orthopedics and traumatology surgical material options continue to increase with development in medical technology. Thus, orthopedists find it very difficult to choose the option that will achieve the best results. The selection of optimal suture anchors in terms of applicability and clinical results in SLAP operation is one of these ongoing discussions. This study evaluated the effect of the suture



**Figure 2.** Chondral damage (A) During insertion of the TSA into the glenoid. (B) After TSA insertion and SLAP repair. TSA, titanium suture anchor; SLAP, superior labral anterior to posterior.

anchor type applied in the repair of isolated type II SLAP lesions on mid-term clinical outcomes. We observed that the use of TSA or ASA did not significantly affect the clinical results, and a satisfactory level of improvement occurred in the use of both suture anchors.

Many parameters and properties of suture anchors, such as accessibility, applicability, healing, cost-effectiveness, and effect on clinical results, contribute to the clinician's preference regarding their use. In this study, the mid-term clinical outcomes of using TSA or ASA in isolated type II SLAP operations were found to be comparable. However, considering our experience and the relevant literature, metallic suture anchors, which are among the suture anchor options in SLAP operation, have some disadvantages caused by their rigid structure. Compared with the use of ASAs, the use of metallic suture anchors is associated with a greater degree of chondral damage and more frequent migration and loosening [14, 15] (Figure 2).

In addition, while metallic suture anchors cause serious image distortion in postoperative magnetic resonance imaging (MRI), this is not the case for ASAs, and postoperative MRI can be easily performed in cases with ASA application [7, 8, 16, 17]. All-suture anchors, which are a relatively new type of suture anchor, have many advantages—including the fact that they are not rigid and consist entirely of flexible suture materials. In addition, the need for smaller holes during application reduces damage to the bone structure and allows for more comfortable movement and fixation of a greater number of suture anchors (Figure 3).

In addition, ASAs are inexpensive and easier to reimplant [17–19]. However, ASAs have some rarely encountered disadvantages, such as cyst formation and tunnel expansion caused by micro-movements [8, 20]. In the light of the successful clinical results with both suture anchors presented in this study and the findings of previous studies, ASA application can be considered as a reliable and preferable suture anchor option in isolated type II SLAP lesion repair procedures.

To our knowledge, only a few studies have compared ASA and metallic suture anchors. Two studies have compared the application of metallic suture anchors and ASA in traumatic anterior shoulder instability and showed that the short-term and mid-term clinical results of the suture an-

**Table 1.** Summary of patient characteristics with regard to treatment groups

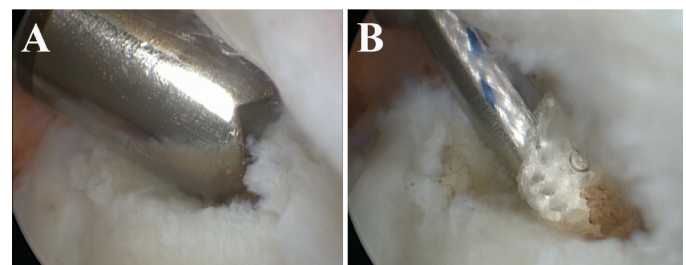
	Group			P
	ASA (n = 24)	TSA (n = 20)	All (n = 44)	
Gender				
Male	15 (62.5%)	12 (60.0%)	27 (61.4%)	0.865
Female	9 (37.5%)	8 (40.0%)	17 (38.6%)	
Age (year)	35.21 ± 11.47	34.65 ± 9.91	34.95 ± 10.67	0.865
Side				
Left	12 (50.0%)	10 (50.0%)	22 (50.0%)	1.0
Right	12 (50.0%)	10 (50.0%)	22 (50.0%)	
Sport activity				
Absent	8 (33.3%)	6 (30.0%)	14 (31.8%)	0.967
Competitive	6 (25.0%)	5 (25.0%)	11 (25.0%)	
Frequent	10 (41.7%)	9 (45.0%)	19 (43.2%)	
Follow-up time (month)	53.50 ± 19.79	54.60 ± 17.02	54.00 ± 18.38	0.846

Data are given as mean ± standard deviation for continuous variables, and frequency (percentage) for categorical variables. Abbreviations: ASA, All-suture anchor; TSA, titanium suture anchor.

**Table 2.** Table 2. Summary of clinical outcomes with regard to treatment groups

	Group		p*
	ASA (n = 24)	TSA (n = 20)	
Number of anchors			
1	17 (70.8%)	13 (65.0%)	0.679
2	7 (29.2%)	7 (35.0%)	
ASES			
Preoperative	42 (40 - 48)	44 (39 - 48)	0.852
Last follow-up	88 (87 - 90)	90 (87 - 90)	0.808
p**	< 0.001	< 0.001	
UCLA			
Preoperative	14 (14 - 16)	14 (13 - 16)	0.639
Last follow-up	30 (28 - 32)	31 (30 - 34)	0.382
p**	< 0.001	< 0.001	
VAS			
Preoperative	8 (7 - 8)	8 (7 - 8)	0.936
Last follow-up	3 (3 - 3.5)	3 (2 - 4)	0.859
p**	< 0.001	< 0.001	

Data are given as median (1st quartile - 3rd quartile), \*Between groups, \*\*Within group, Abbreviations, ASA, All-suture anchor; TSA, titanium suture anchor; ASES, The American Shoulder and Elbow Surgery score; UCLA, University of California Los Angeles shoulder score; VAS, visual analog scale



**Figure 3.** (A) Creating a tunnel with a specific guide to reduce chondral damage before ASA placement (B) Occurrence of chondral damage is minimal during ASA insertion. ASA, superior labral anterior to posterior

chor groups were comparable, consistent with the results of our study [8, 9]. Studies comparing these two suture anchors in the repair of lesions in other sites have reported that TSA and ASA are not clinically superior to each other and can be used interchangeably [10-12]. When we examined studies on the use of ASA without comparison to other methods, a study evaluating the results of arthroscopic repair of glenoid labral lesions with ASA was found to have reported satisfactory postoperative clinical results [21]. Another study evaluating the results of arthroscopic stabilization with ASA in anterior shoulder instability reported clinically excellent results in nearly all cases without any complications or recurrences [22]. Similarly, other studies have shown successful pain and functional outcomes following the use of ASA in shoulder surgery [23]. Consistent with all these studies, we present good levels of mid-term success with ASA in terms of pain, function, and satisfaction; however, as mentioned before, TSA and ASA were not superior to each other in terms of clinical results.

This retrospective single-center study has important limitations. Differences in the experience and skill levels of surgeons may create inconsistencies when comparing the results of different studies. However, the similar outcomes of our research when compared to prior literature may indicate that these minor variations can be ignored. The

number of cases per group limited the detectability and comparability of rare complications between groups. Results of future studies with more cases will likely differ in this respect. The heterogeneity of the final follow-up time among cases may have also altered results due to temporal effects.

### Conclusion

Mid-term clinical outcomes were comparable with the use of knotted TSA or knotted ASA in the arthroscopic treatment of isolated type II SLAP lesions. No significant difference was found between the groups in terms of functionality, satisfaction, and pain. Considering the potential benefits of ASA in SLAP lesion repair, it appears that ASA application may be a reliable and satisfactory alternative to metallic suture anchors. Future studies are recommended to include more cases and examine long-term results of using ASA in SLAP lesion repair.

### References

1. Kibler WB, Sciascia A. Current practice for the surgical treatment of SLAP lesions: A systematic review. *Arthroscopy* 2016;32(4):669-83.
2. Sullivan S, Hutchinson ID, Curry EJ, et al. Surgical management of type II superior labrum anterior posterior (SLAP) lesions: a review of outcomes and prognostic indicators. *Phys sportsmed* 2019;47(4):375-86.
3. Snyder SJ, Karzel RP, Del Pizzo W, et al. SLAP lesions of the shoulder. *Arthroscopy* 1990;6(4):274-9.
4. Kibler WB, Sciascia A. Current practice for the diagnosis of a SLAP lesion: systematic review and physician survey. *Arthroscopy* 2015;31(12):2456-69.
5. Schröder CP, Skare Ø, Reikerås O, et al. Sham surgery versus labral repair or biceps tenodesis for type II SLAP lesions of the shoulder: a three-armed randomised clinical trial. *Br J Sports Med* 2017;51(24):1759-66.
6. Knapik DM, Kolaczko JG, Gillespie RJ, et al. Complications and Return to Activity After Arthroscopic Repair of Isolated Type II SLAP Lesions: A Systematic Review Comparing Knotted Versus Knotless Suture Anchors. *Orthop J Sports Med* 2020;8(4):2325967120911361.
7. Nolte P-C, Midtgaard KS, Ciccotti M, et al. Biomechanical comparison of Knotless all-suture anchors and knotted all-suture anchors in type II SLAP lesions: a cadaveric study. *Arthroscopy* 2020;36(8):2094-102.
8. Uluyardımcı E, Öggüder DA, Bozkurt İ, et al. All-suture anchors versus metal suture anchors in the arthroscopic treatment of traumatic anterior shoulder instability: A comparison of mid-term outcomes. *Jt Dis Relat Surg* 2021;32(1):101-7.
9. Sevimli R, Aslantürk O, Ergen E, et al. Mid-Term Outcomes of Arthroscopic Treatment in Patients with a Stiff Elbow. *Cureus*. 2018 May 15;10(5):e2630.
10. Otto A, Mehl J, Obopilwe E, et al. Biomechanical comparison of onlay distal biceps tendon repair: all-suture anchors versus titanium suture anchors. *Am J Sports Med* 2019;47(10):2478-83.
11. Otto A, Dicosmo AM, Baldino JB, et al. Biomechanical evaluation of proximal hamstring repair: all-suture anchor versus titanium suture anchor. *Orthop J Sports Med* 2019;8(1):2325967119892925.
12. Midtgaard KS, Nolte P-C, Miles JW, et al. Pullout Strength of All-Suture and Metallic Anchors in Repair of Lateral Collateral Ligament Injuries of the Elbow. *Arthroscopy* 2021 37(9):2800-06
13. Wylie JD, Beckmann JT, Granger E, et al. Functional outcomes assessment in shoulder surgery. *World J Orthop* 2014;5(5):623-33.
14. Park HB, Keyurapan E, Gill HS, et al. Suture Anchors and Tacks for Shoulder Surgery, Part II: The Prevention and Treatment of Complications. *Am J Sports Med* 2006 2006;34(1):136-44.
15. Dhawan A, Ghodadra N, Karas V, et al. Complications of bioabsorbable suture anchors in the shoulder. *Am J Sports Med* 2012 ;40(6):1424-30.
16. Dwyer T, Willett TL, Dold AP, et al. Maximum load to failure and tensile displacement of an all-suture glenoid anchor compared with a screw-in glenoid anchor. *Knee Surg Sports Traumatol Arthrosc* 2016;24(2):357-64.
17. Nakagawa S, Hirose T, Tachibana Y, et al. Postoperative recurrence of instability due to new anterior glenoid rim fractures after arthroscopic Bankart repair. *Am J Sports Med* 2017;45(12):2840-48.
18. Godry H, Jettkant B, Seybold D, et al. Pullout strength and failure mode of industrially manufactured and self-made all-suture anchors: a biomechanical analysis. *J Shoulder Elbow Surg* 2020;29(7):1479-83.
19. Ntalos D, Huber G, Sellenschloh K, et al. Biomechanical analysis of conventional anchor revision after all-suture anchor pullout: a human cadaveric shoulder model. *J Shoulder Elbow Surg* 2019;28(12):2433-37.
20. Pfeiffer FM, Smith MJ, Cook JL, et al. The histologic and biomechanical response of two commercially available small glenoid anchors for use in labral repairs. *J Shoulder Elbow Surg* 2014;23(8):1156-61.
21. Gül O, Okutan AE, Ayas MS. Arthroscopic glenoid labral lesion repair using all-suture anchor for traumatic anterior shoulder instability: Short-term results. *J Shoulder Elbow Surg* 2019;28(10):1991-7.
22. Devgan A, Singh SK, Behera KC, et al. Outcome of Arthroscopic Stabilization of Anterior Shoulder Instability using All-Suture Anchor Technique. *J Pak Orthop Assoc* 2020;32(01):24-28.
23. Willemot L, Elfadalli R, Jaspars KC, et al. Radiological and clinical outcome of arthroscopic labral repair with all-suture anchors. *Acta Orthop Belg* 2016;82(2):174-8.