

# Comparison of loose silk and tightenable polypropylene seton placement in treatment of complex anal fistula

Yahya Celik<sup>1</sup>, Mehmet Zeki Buldanli<sup>2</sup>

<sup>1</sup>Department of General Surgery, Gebze Fatih State Hospital, Kocaeli, Turkey

<sup>2</sup>Department of General Surgery, Gulhane Training and Research Hospital, University of Health Sciences, Ankara, Turkey

Copyright@Author(s) - Available online at [www.annalsmedres.org](http://www.annalsmedres.org)

Content of this journal is licensed under a Creative Commons Attribution-NonCommercial 4.0 International License.



## Abstract

**Aim:** Treatment of complex anal fistula is a challenging task due to the risk of recurrence and development of incontinence and there is no consensus over how to treat this condition. We aimed to compare the results in our patients whom we have applied loose silk or tightenable polypropylene seton.

**Materials and Methods:** Demographic characteristics, duration of hospital stay, duration of operation, duration between two operations in patients requiring second operation, time to healing, recurrence, pain assessment by using Visual Analogue Scale (VAS) during follow-up exams and gas and/or stool incontinence of patients with complex anal fistula diagnosis who were treated by loose silk or tightenable polypropylene seton between March 2017 and March 2019 in our clinic were examined.

**Results:** In this study, 81 (86.2%) male and 13 (13.8%) female patients with a total of 94 were included. In 58 (61.7%) of these patients polypropylene and in 36 (38.3%) silk seton was used. The mean age of the patients was 42.5±12.1 years. Mean follow-up was 17.2±6.5 months. Recovery time in polypropylene group (9.9±1.3 weeks) was shorter than silk seton group (12.7±2.7 weeks) ( $p<0.001$ ). Pain VAS average was higher in polypropylene group (6.3±0.9) compared to silk seton group (5.1±0.7) ( $p<0.001$ ). There was no significant difference between two groups for recurrence and incontinence.

**Conclusion:** For the treatment of complex anal fistula, placement of tightenable polypropylene compared to loose silk seton has advantages such as shorter healing time and less need for second operation but it causes more pain during follow-up exams.

**Keywords:** Complex anal fistula; polypropylene seton; silk seton

## INTRODUCTION

It's supposed that anal fistulas usually develop as a result of anorectal criptoglandular area inflammation (1). In clinical practice, according to Parks classification fistulas are called as 'intersphincteric', 'transsphincteric', 'suprasphincteric' and 'extrasphincteric' and according to their association with the sphincter anal fistulas are called as 'simple' and 'complex' (2). In contrast to simple fistula, complex anal fistulas require longer treatment duration and higher patient compliance (3). Complex anal fistulas have various complications such as anal pain during or after the treatment, deterioration of life quality, abscess, recurrence, incontinence and need for additional surgery (3). There is no consensus over the treatment of anal fistula due to several factors such as the location of the fistula track, its association with the sphincter and choice of the surgeon. There are various surgical options such as seton placement, flap advancement and using several fistula plugs like fibrin glue (4-6). Various surgical materials such as 'loose' and 'tight' silicon,

silk, polypropylene, elastic and rubber bands and suture can be used in seton applications. The main objective in seton placement is to disrupt fistula tract by 'iceberg effect' without damage to the anal sphincters (7,8). Loose seton is usually used in inflammatory bowel diseases (IBD) or perianal abscess requiring long-term treatment but tight seton is used in conditions where rapid healing is expected (9). However, it was shown in various studies that need for tightening in certain periods during tight seton placement has interfered with patient comfort due to the pain experienced by the patient during follow-up exams (10). Therefore, the aim of this study was compare the results of loose silk seton placement and tightenable polypropylene seton placement in treatment of complex anal fistula.

## MATERIALS and METHODS

Patients with complex anal fistula diagnosis who were treated by loose silk seton or tightenable polypropylene seton placement between March 2017 and March 2019 in our clinic were examined. This retrospective study was

Received: 23.07.2020 Accepted: 19.08.2020 Available online: 19.02.2021

Corresponding Author: Mehmet Zeki Buldanli, Department of General Surgery, Gulhane Training and Research Hospital, University of Health Sciences, Ankara, Turkey E-mail: [buldanli87@hotmail.com](mailto:buldanli87@hotmail.com)

carried out by retrospective assessment of hospital patient records after the approval of local ethics committee. Demographic characteristics, duration of hospital stay, duration of operation, duration between two operations in patients requiring second operation, time to healing, recurrence, pain assessment by using Visual Analogue Scale (VAS) during follow-up exams and gas and/or stool incontinence of patients were examined. Patients with simple fistula and fistulas associated with IBD were excluded from the study.

### Diagnosis and Pre-operative Preparation

In this study, complex anal fistula diagnosis was established by physical examination and intravenous (i.v.) contrast enhanced Dynamic Diffusion Pelvic Magnetic Resonance Imaging (MRI).

As prophylactic antimicrobial therapy, 1 gram Cefazolin-sodium was given by i.v. route pre-operatively. Pre-operative 135 ml Sodium dihydrogen phosphate laxative enema was used rectally. After discharge of the stool patients were admitted to the operation.

### Operation Methods

All patients were operated at prone position. Fistula tract was detected by using probe after detailed digital rectal examination. Fistula tract was fistulectomized until the level of sphincters in a way that fistula external opening was included. Silk or polypropylene seton was applied to the fistula tract including sphincters. Blind extended pouche was searched by rectal digital examination and probe. Fistula tract and if present blind-end pouche was curetted. In silk group, Three 0 silk suture was loosely used. In the polypropylene group, single 0 polypropylene suture was used. It was tied by a special tying technique so it became tightenable.

### Post-operative Follow-up

In both groups the patients without early complications were discharged from the hospital with medical advice and medical treatments in the next day after the operation. After 3 daily hot-water sit bath to move seton slightly was advised. Follow-up in 7-10 days interval was planned. Seton was moved at every follow-up exam in silk seton patients. Abscess or recurrence was controlled by rectal digital examination. These controls have continued until it was observed that seton have cut more than 2/3 of the sphincters and fibrosis has developed. In this stage, patients were re-operated and seton was removed by fistulotomy. In tight polypropylene group in the first two weeks seton was loose. In the subsequent follow-up seton was tightened after each follow-up exam slightly. This process has continued until seton has cut all sphincters. After spontaneous drop of seton follow-up exams have continued until total wound healing. Condition of seton, condition of wound site, pain and incontinence were monitored and followed up in outpatient follow-up of patients. Moreover, all this information was recorded into the follow-up chart of patients.

### Statistical Analysis

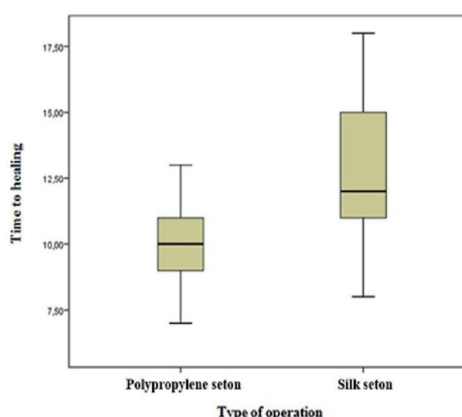
Statistical analysis was carried out by using SPSS version 17.0 program. Histogram graphics and Kolmogorov-Smirnov test was used to analyze the conformity of variables with normal distribution. While presenting descriptive analysis mean, standard deviation and median values were used. Categorical data were compared by using Pearson  $\chi^2$  and Fisher's Exact Tests. In assessment of variables with normal distribution (parametric variables) between groups T test was used in independent groups and variables with non-normal distribution (non-parametric variables) were assessed between groups by using Mann Whitney U Test. P-value <0.05 was considered as statistically significant.

## RESULTS

In this study, 81 male (86.2%) and 13 female (13.8%) patients with a total of 94 were included. In 58 (61.7%) of these patients polypropylene seton and in 36 (38.3%) silk seton was placed. The mean age of the patients was  $42.5 \pm 12.1$  years. Mean follow-up was  $17.2 \pm 6.5$  months. Mean duration of operation was  $38.3 \pm 14.5$  minutes. Mean duration of hospital stay was  $1.4 \pm 0.6$  days. Mean recovery time was  $10.9 \pm 2.4$  weeks. The duration between two operations was  $9.2 \pm 2.3$  week. Pain VAS score average during follow-up exams was  $5.9 \pm 0.9$  (Table 1).

**Table 1. Age of patients, duration of follow-up, duration of operation, duration of hospital stay, healing time, duration between two operations, VAS pain score average during follow-up exams**

	Mean	Standard Deviation	Median
Age	42.5	$\pm 12.1$	43.00
Duration of follow-up	17.2	$\pm 6.5$	16.00
Duration of operation	38.3	$\pm 14.5$	35.00
Duration of hospital stay	1.4	$\pm 0.6$	1.00
Time to healing	10.9	$\pm 2.4$	10.00
Duration between two operations	9.2	$\pm 2.3$	9.00
VAS during follow-up exams	5.9	$\pm 0.9$	6.00



**Figure 1. Recovery time according to type of operation**

Mean age, duration of follow-up, duration of operation, duration of hospital stay, time to healing, pain VAS during follow-up exams were compared according to the type of operation. Accordingly, duration of follow-up was longer in silk seton group (23.9±3.2 months) than polypropylene seton group (13.1±3.9 months) (p<0.001). Duration of operation in polypropylene seton group (41.8±14.4 minutes) was longer than silk seton group (32.6±13.1 minutes) (p:0.005). Time to healing in polypropylene seton group (9.9±1.3 weeks) was shorter than silk seton group (12.7±2.7 weeks) (p<0.001) (Figure 1).

Pain VAS score average was higher in polypropylene seton group (6.3±0.9) compared to silk seton group (5.1±0.7) (p<0.001), (p<0.001) (Table 2), (Figure 2).

Recurrence was seen in 6 patients (6.38%). There was no significant difference between two groups in terms of recurrence (Table 3).

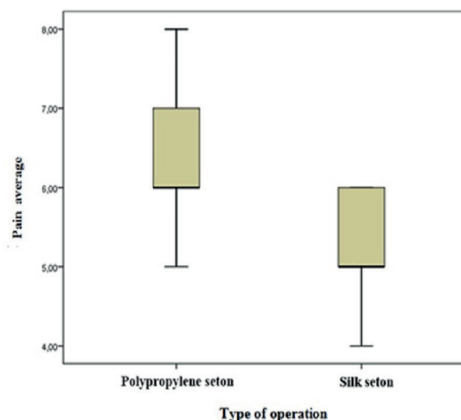


Figure 2. Follow-up exams pain average according to type of operation

Table 2. Age of patients, duration of follow-up, duration of operation, duration of hospital stay, time to healing, pain VAS during follow-up exams according to the type of operation

	Type of operation						p <sup>1</sup>
	Polypropylene seton			Silk seton			
	Mean	Standard Deviation	Median	Mean	Standard Deviation	Median	
Age	41.2	±13.4	39.50	44.5	±9.2	44.00	0.153 <sup>2</sup>
Duration of follow-up	13.1	±3.9	12.00	23.9	±3.2	22.00	<0.001
Duration of operation	41.8	±14.4	40.00	32.6	±13.1	30.00	0.005
Duration of hospital stay	1.4	±0.6	1.00	1.5	±0.7	1.00	0.187
Time to healing	9.9	±1.3	10.00	12.7	±2.7	12.00	<0.001
VAS during follow-up exams	6.3	±0.9	6.00	5.1	±0.7	5.00	<0.001

<sup>1</sup>Mann Whitney U Test; <sup>2</sup>Independent T Test

Table 3. Sex and recurrence distribution according to the type of operation

	Type of operation				p
	Polypropylene seton		Silk seton		
	n	%	n	%	
<b>Sex</b>					
Male	52	(89.7)	29	(80.6)	0.214
Female	6	(10.3)	7	(19.4)	
<b>Recurrence</b>					
Yes	3	(5.2)	3	(8.3)	0.542
No	55	(94.8)	33	(91.7)	

χ<sup>2</sup> Test

## DISCUSSION

Complex anal fistula disease is a condition supposed to be originated from cryptoglandular area inflammation that interferes with the life quality of patients both by its

complications and by processes involving pre-treatment and post-treatment period (1,11). Although there are various options for its treatment seton placement is highly preferred (12). In this study, we have assessed the results of complex anal fistula cases treated with tightenable polypropylene seton or loose silk seton retrospectively.

In contrast to the treatment of simple fistula, seton placement is the mostly used method in the treatment of complex fistula for a long time (13). There are a lot of treatment option for complex anal fistula; however, the determinants for the preferred treatment are mostly clinical picture of the patients, physical examination and imaging results and experience of the surgeon but regardless of the treatment choice the treatment is a long and difficult process and involves several risks such as recurrence and incontinence (14,15).

Loose seton is usually used in cases requiring long-term treatment but tight seton is used in conditions where rapid healing is expected. However, tight seton placement has disadvantages such as pain, incontinence and interference with patient comfort during follow-up exams (16,17). In

this study, we left tightenable polypropylene seton as loose seton for two weeks. At the end of two weeks they were tightened during follow-up exams and continued as tight seton.

In this study, recurrence rate was 8.33% after loose silk seton placement and 5.17% after tight polypropylene seton placement. In total recurrence rate average was 6.38%. All of the recurrences have occurred between post-operative periods and healing period. It was observed that recurrences have usually occurred because top of the seton was covered by mucosa or because of early closure of the fistulectomized area. No patient has showed up with recurrence after healing. In both groups there were one patient with additional fistula tract that has been overlooked which was detected post-operative third week. In a systematic review carried out by Patton et al. recurrence rate of seton placement was reported as between 0% and 8%. In our study, recurrence rate was in concordance with the literature (16). As Emile et al. who have detected recurrence rate as 10.3% after seton placements in high transsphincteric anal fistulas have also stated that additional risk factors such as previous anal fistula surgery, presence of horse shoe fistula and supralevatoric extension may lead to development of recurrence (18).

It's known that follow-up period is longer after the surgery for complex fistula. Moreover, following seton placement primary healing and secondary wound closure duration may prolong and this prolongation may require close monitorization of the patients in certain intervals (19). In the study of Durgun et al. mean follow-up duration was 55 months with time span reaching up to 9 years (20). In this study mean follow-up time was 17.2 months and mean primary healing time was 10.9 weeks.

In this study, it was observed that primary healing time was significantly shorter with tightenable polypropylene seton placement compared to loose silk seton. In patients who have undergone loose silk seton placement re-operation is needed for the removal of seton. Mean duration between two operations was 9.2 weeks.

During follow-up exams after seton placement patients often experience pain and this interferes with life quality negatively and pose difficulties in treatment (8). VAS is the most widely used method in pain assessment and scoring in clinical practice and thus may help to assess the severity of pain (21). In this study, VAS scoring was used to assess pain severity of patients during follow-up exams and VAS average was found as 5.85.

In this study, VAS results of the patients who have undergone tight polypropylene seton placement was significantly higher than loose seton group.

History taking and rectal digital examination is highly important in order to assess sphincter tonus and presence of incontinence before and after the treatment of complex anal fistula like the other pelvic and anal region diseases (22,23). However, regarding these assessments

the most objective results can be obtained by anorectal manometry studies and endoanal ultrasonography (EUS). By observing sphincter pressure by manometry during rest and contractions and observing sphincter contractions by EUS development of incontinence can be clearly discriminated (22). In this study, no gas or stool incontinence was observed after both seton placement method symptomatically or at physical examination. However, in this study we couldn't use anorectal manometry or EUS in pre-operative and post-operative control examinations in order to monitor the sphincter damage sparing. Thus, it seems that there is need for further studies in order to determine which method is more effective in terms of sphincter sparing. This is one of the limitations of our study.

## CONCLUSION

In conclusion, tightenable polypropylene seton placement has advantages such as shorter time to healing and no need for second operation compared to loose silk seton in treatment of complex anal fistula but during follow-up exams there is more pain. Incontinence and recurrence rate were similar in both groups. However, there is need for further large systematic reviews and randomized prospective studies involving large number of patients in order to make better decisions for the choice and application of different methods.

*Conflict of interest : The authors declare that they have no competing interest.*

*Financial Disclosure: There are no financial supports.*

*Ethical approval: Ethics committee approval was received for this study from Kartal Koşuyolu Higher Specialization Hospital Local Ethics Committee. The registration identification number is 2019.4/15-192.*

## REFERENCES

1. Sugrue J, Nordenstam J, Abcarian H, et al. Pathogenesis and persistence of cryptoglandular anal fistula: A systematic review. *Tech Coloproctol* 2017;21:425-32.
2. Parks A, Gordon PH, Hardcastle J. A classification of fistula-in-ano. *Br J Surg* 1976;63:1-12.
3. Kristo I, Stift A, Staud C, et al. The type of loose seton for complex anal fistula is essential to improve perianal comfort and quality of life. *Colorectal Dis* 2016;18:194-8.
4. Michalopoulos A, Papadopoulos V, Tziris N, et al. Perianal fistulas. *Tech Coloproctol* 2010;14:15-7.
5. Zhao B, Wang Z, Han J, et al. Long-term outcomes of ligation of the inter-sphincteric fistula tract plus bioprosthetic anal fistula plug (LIFT-Plug) in the treatment of trans-sphincteric perianal fistula. *Med Sci Monit* 2019;25:1350-4.
6. De la Portilla F, Muñoz-Cruzado MVD, Maestre MV, et al. Platelet-rich plasma (PRP) versus fibrin glue in cryptogenic fistula-in-ano: a phase III single-center, randomized, double-blind trial. *Int J Colorectal Dis* 2019;34:1113-9.



7. Gurer A, Ozlem N, Gokakin AK, et al. A novel material in seton treatment of fistula-in-ano. *Am J Surg* 2007;193:794-6.
8. Pommaret E, Benfredj P, Soudan D, et al. Sphincter-sparing techniques for fistulas-in-ano. *J Visc Surg* 2015;152:31-6.
9. McCourtney J, Finlay I. Setons in the surgical management of fistula in ano. *Br J Surg* 1995;82:448-52.
10. Rosen D, Kaiser A. Definitive seton management for transsphincteric fistula-in-ano: Harm or charm? *Colorectal Dis* 2016;18:488-95.
11. Owen H, Buchanan G, Schizas A, et al. Quality of life with anal fistula. *Ann R Coll Surg Engl* 2016;98:334-8.
12. Limura E, Giordano P. Modern management of anal fistula. *World J Gastroenterol* 2015;21:12-20.
13. Ege B, Leventoğlu S, Menteş B, et al. Hybrid seton for the treatment of high anal fistulas: results of 128 consecutive patients. *Tech Coloproctol* 2014;18:187-93.
14. Akiba RT, Rodrigues FG, da Silva G. Management of complex perineal fistula disease. *Clin Colon Rectal Sur* 2016;29:92-100.
15. Garg P. A new understanding of the principles in the management of complex anal fistula. *Med Hypotheses* 2019;132:109329.
16. Patton V, Chen CM, Lubowski D. Long-term results of the cutting seton for high anal fistula. *ANZ J Surg* 2015;85:720-7.
17. Bektasoglu HK, Kunduz E. Elastic seton placement in treatment of complex anal fistula: Analysis of 44 patients. *Turk J Colorectal Dis* 2018;28:18-21.
18. Emile SH, Elfeki H, Thabet W, et al. Predictive factors for recurrence of high transsphincteric anal fistula after placement of seton. *J Surg Res* 2017;213:261-8.
19. Chuang-Wei C, Chang-Chieh W, Cheng-Wen H, et al. Cutting seton for complex anal fistulas. *Surgeon* 2008;6:185-8.
20. Durgun V, Perek A, Kapan M, et al. Partial fistulotomy and modified cutting seton procedure in the treatment of high extrasphincteric perianal fistulae. *Dig Surg* 2002;19:56-8.
21. Heller GZ, Manuguerra M, Chow R. How to analyze the Visual Analogue Scale: Myths, truths and clinical relevance. *Scand J Pain* 2016;13:67-75.
22. Cariati A. Fistulotomy or seton in anal fistula: a decisional algorithm. *Updates Surg* 2013;65:201-5.
23. Sari R, Kus M, Arer IM, et al. A single-center experience of clinical outcomes of surgical management for rectocele Disease. *Turk J Colorectal Dis* 2019;29:183-7.