

The exposition of generators and electrodes belonging to the pacemaker in pacemaker dependent patients: A new management method

 Rana Kapukaya¹,  Percin Karakol²

¹Department of Plastic, Reconstructive and Aesthetic Surgery, Health Science University Adana Health Practice and Research Center, Adana, Turkey

²Department of Plastic, Reconstructive and Aesthetic Surgery, Health Science University Bagcilar Education and Training Hospital, Istanbul, Turkey

Copyright@Author(s) - Available online at www.annalsmedres.org

Content of this journal is licensed under a Creative Commons Attribution-NonCommercial 4.0 International License



Abstract

Aim: In patients with pacemakers, their exposure is often mortal, as there are already patients whose general condition is impaired. In our study, by focusing on our different recommendations and exposition formation mechanisms in case of a need for re-operation when exposition and necrosis in the skin flap is observed in 8 patients who were fitted with cardiac pacemakers due to being dependent on batteries, we shared what could be done in order to prevent it from happening from the beginning.

Materials and Methods: Exposed batteries and connections of 8 patients who had admitted due to pacemaker exposition between January 2015- March 2017 were carefully dissected and removed. The generator and leads were replaced with new ones and carried by opening a new subpectoral pocket on the opposite side by creating a subcutaneous tunnel on the sternum. The area on the left side where the skin flap with development of necrosis was located was debrided. It was reconstructed with fasciocutaneous flap.

Results: All patients were successfully treated. No complications were observed during the follow-up period.

Conclusion: In cases where large necrosis develops at the pacemaker exposition and on the skin island, it is an effective treatment method to replace the battery with all its connections due to the biofilm layer formed on it with extracardiac lead and to place it in a new subpectoral pocket opened on the other side by tunnelizing. Since exposition is seen mostly in patients with thin subcutaneous fat tissue, pressure can be mechanically prevented by also involving muscle from the beginning or by placing in deeper tissue. Technically, the greatest advantage of the method that we recommend is that it can be done under local anesthesia.

Keywords: Exposition; pacemaker; reconstruction

INTRODUCTION

Pacemakers are systems that automatically activate and regulate in patients with heart rhythm problems. Today, despite advanced electrophysiological studies and ablation treatments, permanent pacemaker insertion is still highly preferred in patients with rhythm disorders. Classically, these systems are made up of generator and electrode (lead) systems. When the leads are being placed as transvenous, epicardial, transthoracic and transcutaneous, conductive wires are available that allow them to reach the chambers of the heart. Although pace is covered with biocompatible materials, it can become complicated, sometimes caused by pacemaker and sometimes caused by patient or surgery technique, because it is a foreign object for the body. Whereas in previous years, it was preferred to place the pace in the right pectoral region, today in order not to strain the leads and to

prevent rare but mortal complications such as myocardial rupture, also because of the fact that most are right hand dominated, left subpectoral region is preferred (1). While the infections of both cardiac permanent pacemaker (PPM) and implantable cardiac defibrillator (ICD) themselves and their connections and their exposition from the skin are observed at rates of between approximately 0.1% and 20%, the treatment regimens differ among clinics. ICDs are larger, thicker and more complex devices than PPMs. ICDs have additional defibrillation functions. In terms of differences in indications, ICDs have been designed mostly for patients who have life threatening attacks/episodes of ventricular tachycardia and fibrillation such as hypertrophic cardiomyopathy, who previously underwent cardiovascular arrest and was resuscitated, who have risk criteria such as ejection fractions (EF) below 20% and who could need defibrillation any moment. In other words, it has wider indications. On the other hand, the

Received: 07.08.2020 **Accepted:** 02.11.2020 **Available online:** 22.12.2020

Corresponding Author: Rana Kapukaya, Department of Plastic, Reconstructive and Aesthetic Surgery, Health Science University Adana Health Practice and Research Center, Adana, Turkey **E-mail:** dr_rana@hotmail.com

indications of PPM is limited to patients who have AV block, progressing with bradycardia, with normal EF rates. This exposition problem, which can often be solved by simple manipulations by cardiology clinics, rarely comes before the surgical team, mostly as secondary cases (1,2). Due to the fact that the pacemaker erodes over time, that it and its attachments are infected and damage the skin and subcutaneous tissue on it, there are plastic surgery studies on preventing skin necrosis and tissue defects and resolving battery exposition (Figure 1).

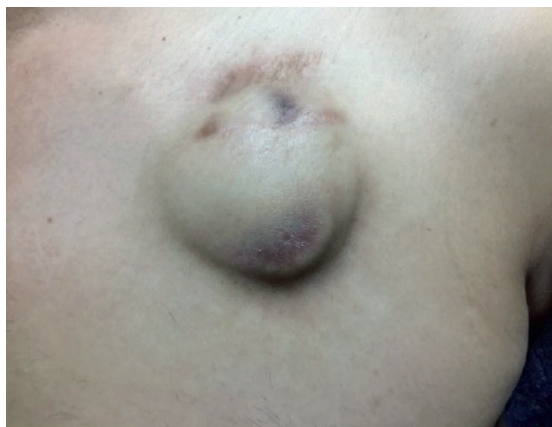

Figure 1. Early skin findings due to the possible pressure of the generator section

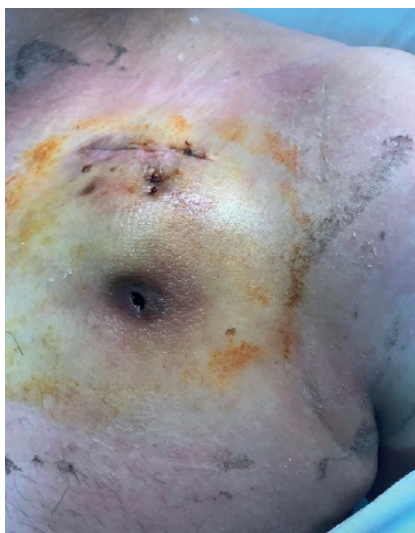

Figure 2. Minimal necrosis due to the possible pressure of the generator section

The appearance patterns can range from slight thinning of ordinary skin, epidermolysis and erosion to clinical pictures such as exposition of electrical pulse generators and lead connections, skin necrosis and capsule contraction (Figure 2). Naturally, types of treatment can range from only superficial debridement, to irrigation of the pocket, replacing the pocket and preparing another pocket for the battery, primary reconstruction of skin defect, Z plasty, local flaps and muscle flaps. If effective control cannot be achieved after infection of generator and connections placed normally in infraclavicular pockets, it could sometimes become necessary in battery

dependent patients to install epicardial pacemaker in the pleural distance by entry through thoracotomy or sternotomy by cardiovascular surgery clinics.

In terms of cost, ICDs are more costly devices than PPMs. At this stage, rather than replacing generators and leads after infection or exposition, it is preferred to place them in different pockets created at many centers or installing transvenous pacemaker from the jugular level. While the left side infraclavicular area is preferred when pacemakers are being installed, if it is a single focus battery, the tip of the pacemaker is placed in the right ventricle, if it is a dual pace that moves the ventricle and atrium in synchrony, one connection extends to the right atrium and one to the right ventricle.

With this study, we would like to present an alternative method for the treatment of exposed batteries, which we consider appropriate.

MATERIALS and METHODS

Eight patients (5 men, 3 women; average age: 63) being treated for pacemaker exposition between January 2015-March 2017 were included in the study. Patients' ages, additional comorbidity causes, time until exposition, the part of the battery exposed, skin finding, results of culture taken during exposition, requirements for antibiotherapy, whether fever and leukocytosis exists within that period, anesthesia scoring, anesthesia type, average time for anesthesia and Body Mass Index (BMI) were chosen as evaluation criteria (Table 1). All eight patients included in our study were patients who had ICD inserted after the full AV block. The mean exposure or skin findings of 8 cases were 7 weeks.

Prior to the intervention, the patients' anticoagulant levels were adjusted. 3 patients had intermittent fevers during the preop period, and patients with leukocytosis at the border had no other focus of fire. In only 1 patient, endocarditis was suspected, transesophageal echocardiography was performed. Expositions complicated to the extent of endocarditis and sepsis were not seen in any of the cases. All patients were admitted with heat increase on the surface of the skin that corresponds to the generator, discoloration, swelling or necrosis.

Among the operations, 4 were carried out under local and 4 under sedation in addition to local anesthesia, and there was external pacemaker preparation for all patients. Preop 1 day before, both 2 pectoral areas were shaved.

Under sterile conditions, necrotic skin flap or epidermolytic areas were debrided following the infiltration of local anesthesia diluted with 1/1 sf to the operation area after local area cleaning. With proper incision, generators and electrodes were dissected. Pace company officials and cardiologists temporarily synchronized and deactivated the pace. The generator's connection site with the wires coming out of the heart was carefully dissected and removed (Figure 3). Generator connections were removed from the area where subclavian vein entered.

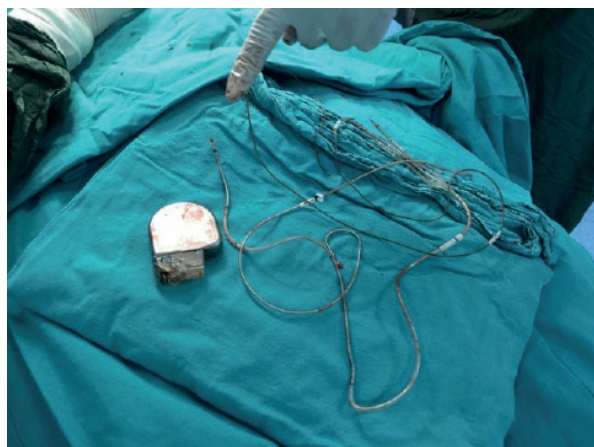

Figure 3. All the exposition generators and wires replaced and surgically placed on the table

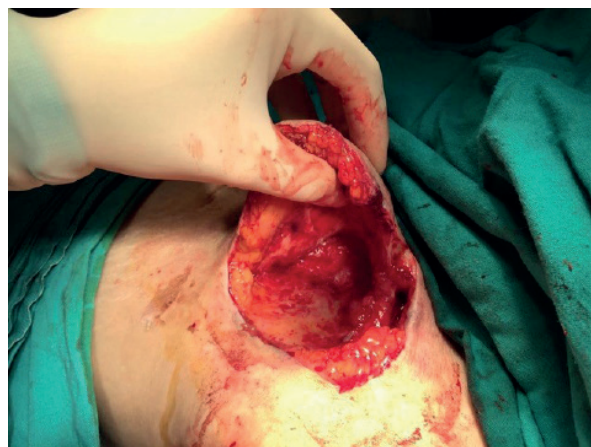

Figure 4. Monitoring of capsule image during pocket change

Table 1. Classification of all cases according to certain criteria

Number of patient	Sex	Age	Comorbidity	Exposition Time	Exposed Device	Skin Findings	Culture	Fever	ASA	Anesthesia Time	BMI
1	M	62	DM	8w	Generator	Hyperemia	<i>Pseudomonas aeruginosa</i>	+	3	1h	20
2	M	57	HT	9w	Generator	Hyperemia	-	-	3	1h	22
3	F	56	DM, MS	7w	Generator	Necrosis	-	-	4	45min	25
4	M	64	DM, PAD	8w	Lead	Epidermolysis	<i>Pseudomonas aeruginosa</i>	-	3	35min	26
5	F	72	DM	10w	Generator	Dehiscance of the wound	<i>Pseudomonas aeruginosa</i>	+	4	50min	24
6	F	56	HT, DM	9w	Generator	Necrosis	-	+	3	55min	25
7	M	70	HL	7w	Generator	Hyperemia	-	-	4	55min	26
8	M	68	HT, DM, CVA	8w	Lead	Dehiscance of the wound	-	-	4	1h	27

M: Male, F: Female, DM: Diabetes Mellitus, HT: Hypertension, MS: Multiple Sclerosis, PAD: Peripheral Arterial Disease, HL: Hyperlipidemia, CVA: Cerebrovascular Accident, w: Week, h: Hour, min: Minutes

Capsulectomy was performed in capsules around the lead, samples for microbiological sampling were taken from patients in whom collection was observed around the generator for the study of culture antibiogram (Figure 4). No patients had capsule contracture. No patients were observed to have purulent or smelly discharge, the entire collection of fluids were serous. The old pocket areas were irrigated with antibiotic fluids. Control of hemorrhage was performed using bipolar cautery.

The surgical field was restrained. Following local anesthesia infiltration, a new subpectoral pocket was opened in the contralateral pectoral region. A narrow subcutaneous tunnel through which wires could pass to reach this pocket was created that bypassed the sternal area. The new pacemaker was reconnected to the lead by passing through the pocket in the right area and the sternal subcutaneous tunnel. The pacemaker was resynchronized under the supervision of computer-accompanied

technicians and cardiologists. After hemorrhage control, the new pacemaker was sutured with 2/0 Vicryl.

The new area was covered primarily. Some of the cables that were not removed because the AV level connections were in the muscle, were left in 2 patients. Active drain was placed in the old areas after capsulectomy. No patients developed postop hematoma or reinfection. In patients with capsulectomy, there was no problem adhesion in the tissue. One fasciocutaneous skin flap was designed from the fields which are thicker than the subcutaneous tissue that mostly matched the inferior of the ancient defect and old defect areas were covered. The flaps were adapted using 4/0 Vicryl rapide.

RESULTS

While in the microbiological samples taken, *Pseudomonas Aeruginosa* reproduction occurred in only 2, samples of 6 patients were interpreted in favor of normal skin flora. Postop, it was continued with local antiseptic dressing suggestions in both areas. Patients were followed for 12 months during the postoperative period. There were no problems after the operation, such as swelling in the early and late periods, and the renewal of the exposition. Patients who were treated with anticoagulant during the preoperative period were returned to normal treatment regimens during the postop period. In the preop and early postop period, 2 patients from among the patients who were started with 1st Generation Cephalosporin analogue were given parenteral Imipenem treatment for 7 days. No patient required long-term antibiotherapy. There was no special condition in scar developments.

DISCUSSION

In the literature, Ciloglu N.S. and his colleagues have reported that they have achieved the pocket change in exposed pacemakers after capsulectomy in the same area to the subpectoral area, and they have repaired the tissue defect with simultaneous local flap (3). Aksoy A. and his colleagues reported that they repaired the exposed pacemakers with fasciocutaneous flap (4). In cases where the patient is not dependent pacemakers, battery excision, re-installing pace with a second surgery in follow-up after defect repair has also been reported as an option (5). In cases where the battery is not exposed, only in cases with hematoma or subcutaneous collection of seroma, there are studies that report that puncture drainage is sufficient together with antibiotic therapy (6). On the other hand, in exposition cases not accompanied by infection, there are studies stating that there are successful results of reconstruction with local flap and within 48 hours (7).

Whereas there is no consensus on the timing and technique of reconstruction, surgeons use different methods depending upon their daily practices, hospital infrastructure, opportunities and the content of insurance coverage (7,8).

Inserting the cardiac pacemaker into the submuscular distance at the first stage when the pocket is being designed in cases with low BMI and ejection fraction or who have thin subcutaneous fat tissue due to old age.

In our study, we concluded that the ratio of subcutaneous fatty tissue is related to one-to-one exposition and the battery putting pressure on the skin. The use of the inguinal area when the pocket is being prepared in pediatric cases is also related to this (9). Sometimes in cases where soft tissue is not enough, support for the battery can be obtained from the muscle. If it is inserted under the muscle, via the prepectoral fascia, a healthier, thicker could be left over the generator. However, the downside of this technique is that the pacemaker's stimulation of the muscle simultaneously can be painful and can lead to fibrosis in the muscle.

When placing devices with large generators such as ICD, body zones with more adequate fasciocutaneous tissue can be used instead of classical infraclavicular pockets.

Since ICD generators are thicker and larger, it is absolutely necessary to place them by preparing a larger pocket. In the literature, it is often reported that the expositions contain only the generator (10,11). The first option in such cases is normally, removing the generator alone and closing the old pocket after cleaning it, and placing the new generator in another pocket designed inside the surrounding tissue but in a deeper location (10). But most of the time, patients may need tertiary operation. In order to reduce morbidity and mortality, placement of the pacemaker should be planned at a suitable level and in a single session, so that it can remain in a sterile pocket for a lifetime for maintenance of battery effectiveness (12,13). It should be noted that the need for secondary surgery might trigger mortal fatal hemorrhage due to existing scarring and fibrosis while removing wires linked to endocarditis. The infection of cardiac pacemakers under the skin, and their contact with the open air can lead to an opening of the connection with endocardium. Systemic infection may result in endocarditis, risk of migration and even sepsis and death.

If the exposition repeats and the need for battery is permanent, since sternotomy is a major surgery in itself, in secondary tertiary cases, the placement of atrioventricular.

LIMITATION

Disadvantage may be that leads can be easily noticed or felt in patients with thin skin. And the surgical technique may require experience. We did not observe any complication due to lead or battery exposure in our technique.

CONCLUSION

In all cases we include in the study, the formation of capsules was present; we attribute formation of a capsule such a short period of time to the biofilm layer on the battery in the early period. Therefore, replacing all generators and connections is the most suitable for all secondary cases. In our study, we considered all implants with exposition as contaminated, regardless of the patient's exposition time or infection status. We have changed the surgical area and implantation material (Figure 5). In one stage, we provided both new battery implantation and reconstruction. We

warned all patients not to lie on the new placement side of the battery for 8 weeks during the postoperative period.

The fact that this procedure can be performed with local anesthesia since all patients have an anesthesia score of ASA 3 and above, and that our minimal donor field mortality is, among the advantages of our technique.

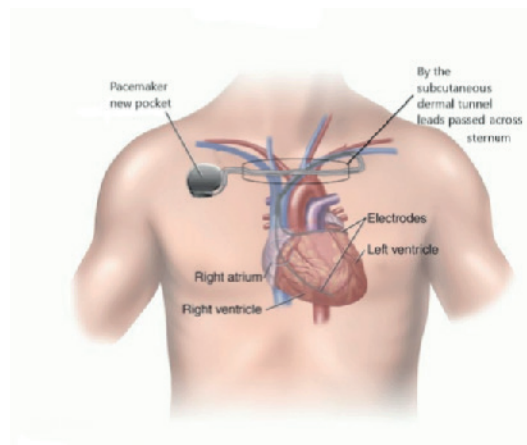


Figure 5. The schematic version of the pocket and side change operation.

Acknowledgments: We would like to thank Dr. Ilyas Kaya and Dr. Bernas Altintas for their contributions in the data collection and processing stages in our study.

Conflict of interest : The authors declare that they have no competing interest.

Financial Disclosure: There are no financial supports.

Ethical approval: Adana City Training and Research Hospital clinical research ethics committee meeting number: 56 date: 06.05.2020 Decision no: 851.

REFERENCES

1. Kiuchi MG, Chen S, Paz LMR, et al. Effectiveness evaluation of ICDs implanted in the right side vs. left side. *Int Cardiovascular Forum J* 2017.

2. Vanezis AP, Prasad R, Andrews R . Pacemaker leads and cardiac perforation. *JRSM Open*. 2017;8.

3. Ciloglu NS, Gumus N, Eraslan T, et al. Salvage of the exposed cardiac pacemakers with pocket change and local flaps. *Turkish Journal of Thoracic and Cardiovascular Surgery* 2014;22;95-8.

4. Aksoy A, Dagdelen D, Sirvan SS. Salvage of the Exposed Cardiac Pacemakers With Fasciocutaneous Local Flaps. *The Medical Bulletin of Sisli Etfal Hospital Semb* 2018;167-9.

5. Timmis CG, Westveer DC. Permanent pacemakers and their complications in perspective. *International Journal of Cardiology* 1986;13:105-8

6. Shah Arti N. Cardiac implantable electrical devices: management of complications; indications for lead extraction. *Decision Support in Med*.

7. Bonawitz SC. Management of exposure of cardiac pacemaker systems. *Ann Plast Surg* 2012;69:292-5.

8. Erin K, Knepp BS, Karan Chopra BA, et al. An effective technique for salvage of cardiac related devices. *Eplasty* 2012;12:8.

9. Barrett BM Jr, Hallman G Jr, Mullins C. Groin flap coverage for an infant's exposed cardiac pacemaker in complete heart block. *Ann Plast Surg* 1980;4:227-9.

10. Chait LA, Ritchie B. A method of treating the exposed cardiac pacemaker. *Br J Plast Surg* 1979;32:281-4.

11. Simpson AM, Rockwell WT, Freedman RA, et al. Salvage of Threatened Cardiovascular Implantable Electronic Devices: Case Series and Review of Literature. *Ann Plast Surg* 2018;81:340-3.

12. Toia F, D Arpa S, Cordova A, et al. Exposed subcutaneous implantable devices: an operative protocol for management and salvage. *Plas Reconstr Surg Glob Open* 2015;3:343.

13. Kolker AR, Redstone JS, Tutela JP. Salvage of exposed implantable cardiac electrical devices and lead systems with pocket change and local flap coverage. *Ann Plast Surg* 2007;59:26-9.