

Endovascular treatment of ruptured anterior circulation aneurysms within 24 hours: Clinical and angiographic results

Mehmet Kolu¹, Gulyara Cigdem², Osman Dere¹, Veysel Kaya³, Ismail Okan Yildirim⁴, Kaya Sarac⁴

¹Department of Radiology, Faculty of Medicine, Harran University, Sanliurfa, Turkey

²Department of Neurosurgery, Faculty of Medicine, Harran University, Sanliurfa, Turkey

³Department of Radiology, Gumushane Kelkit State Hospital, Gumushane, Turkey

⁴Department of Radiology, Faculty of Medicine, Inonu University, Malatya, Turkey

Copyright@Author(s) - Available online at www.annalsmedres.org

Content of this journal is licensed under a Creative Commons Attribution-NonCommercial 4.0 International License



Abstract

Aim: In this study, angiographic and clinical results after endovascular treatment were evaluated in patients with a ruptured brain aneurysm.

Materials and Methods: A total of 32 patients, who admitted to the hospital between May 2018 and January 2020 due to aneurysmal subarachnoid hemorrhage (SAH), were included in the study. Cranial digital subtraction angiography (DSA) imaging was performed within the first 24 hours to patients with SAH detected on computed tomography and endovascular embolization was performed in 32 patients, who were considered as suitable for endovascular treatment. The pretreatment clinical scorings of the patients were evaluated according to the Hunt-Hess scale. Aneurysm occlusion was performed according to the Raymond-Ray classification. The patients were evaluated with the clinical outcome modified ranking scale (mRS) during their follow-up periods.

Results: The endovascular treatment was successfully performed in all patients. In the first angiograms for control purposes after embolization, it was seen that the aneurysms were completely closed (RR1) in 81.25%, partial neck remained (RR2) in 12.5%, and the aneurysms were closed incompletely (RR3) in 6.25% of the patients. Intraprocedural complications developed in five patients (15.6%). There was an aneurysmal rupture in 1 patient (3.1%) and thromboembolic complications in 4 patients (12.5%). The procedure-related morbidity and mortality rates were 9.3% and 3.1%, respectively. No patients had postprocedural hemorrhagic complications. In the 3rd month, mRS was 0 in 21 (65.6%) patients, 1 (3.1%) in 1 patient, and 2 (6.25%) in 2 patients. A total of 11 (34.3%) patients died. A second procedure was performed in 2 (6.25%) of the patients who were followed because there was an RR3 residue.

Conclusion: The endovascular embolization process can be applied in the treatment of intracranial aneurysms causing subarachnoid hemorrhage, and it is a safe and effective treatment method.

Keywords: Brain aneurysm; Endovascular treatment; Subarachnoid hemorrhage

INTRODUCTION

Subarachnoid hemorrhage (SAH) is an important health problem that causes high rates of morbidity and mortality (1,2). While the incidence of SAH varies by region, the mean annual incidence can be considered as 10 per hundred thousand (1). Ruptured intracranial aneurysms are responsible for 85% of the SAH cases, and 10% of the cases suffer from non-aneurysmal bleedings (3,4). The mortality rate in aneurysmal SAH is between 45-60% (1,3). Re-bleeding of ruptured aneurysms is an important complication and there is a risk of mortality over 80% (1,4). The risk of rebleeding aneurysms is maximum in the first 24 hours, and 50-90% of them occur especially within the

first 6 hours (5). Although there are different approaches to the timing of treatment of ruptured aneurysms, predominantly early intervention is thought to reduce mortality rates and give better clinical results (6,7). There are two treatment approaches in the treatment, namely the surgery, and endovascular embolization, and it has been reported that the long-term results of endovascular treatment, such as death and dependent life, are better (8).

In the present study, the angiographic and clinical results of patients with aneurysms causing subarachnoid hemorrhage, who underwent early endovascular treatment within the first 24 hours, were discussed.

Received: 13.05.2020 Accepted: 08.12.2020 Available online: 23.12.2020

Corresponding Author: Mehmet Kolu, Department of Radiology, Faculty of Medicine, Harran University, Sanliurfa, Turkey

E-mail: drdylg@gmail.com

MATERIALS and METHODS

Patient population

A total of 32 patients, who applied to the hospital between May 2018 and January 2020 due to aneurysmal SAH and treated with endovascular cerebral aneurysm were included in the study. SAH was detected with non-contrast brain computed tomography (CT), and these patients underwent digital subtraction angiography (DSA) within the first 24 hours. With the DSA, it was seen that there was a single aneurysm in 30 (93.75%) patients and 2 aneurysms in 2 (6.25%) patients. Also, since the aneurysm dimensions of two patients were <3 mm, they were referred to surgical treatment because of the high risk of rupture due to the endovascular procedure. Of the patients included in study 18 (56.25%) were female and 14 (43.75%) were male. The mean age was 51.2 (22-72 years old). The pretreatment clinical scoring was done according to the Hunt-Hess rating, which is one of the most reliable methods (9). According to the Hunt-Hess rating, 5 patients (15.6%) were accepted as grade 1, 9 patients (28.1%) as grade 2, 7 patients (21.8%) as grade 3, 5 patients (15.6%) as grade 4, and 6 patients (18.75%) as grade 5 (Table 1).

Table 1. The clinical grading of the patients before treatment, using the Hunt-Hess grading scale

Hunt-Hess Grade	Description	Number of patients (%)
1	Asymptomatic or mild headache	5 (14)
2	Moderate to severe headache, nuchal rigidity	12 (34)
3	Mild focal deficit, lethargy, confusion	7 (20)
4	Stupor, hemiparesis	5 (14)
5	Deep coma	6 (17)

Endovascular method

All patients underwent the procedure under general anesthesia. After introducer inlet was opened on the femoral artery, 70IU/kg heparin was administered intravenously (IV). Additional hourly heparin was administered in a way that the activated partial thromboplastin time (aPTT) was kept between 250-280 seconds. Stent delivery catheter was placed in the parent artery in patients with a wide neck structure, which was decided to perform stent neck modeling in the diagnostic DSA, an antiaggregant drug was administered through the nasogastric route with 270 mg brillanta or 40 mg effient before opening the stent. When the stents were placed and the aneurysm sac was started to be coiled, 1 mg of tirofiban was given IV to end in half an hour.

The unilateral femoral artery inlet was opened in all patients. The 7F guiding sheath (Neuronmax; Penumbra) was placed in the target main carotid artery or subclavian artery by the transfemoral route. Then the 5F or 6F intracranial support catheter (Medtronic; Navien) was inserted into

the target ICA petrous segment or vertebral artery V4 segment. Microcatheters such as echelon 10 (Medtronic), Headway 17 (Microvention/Terumo), and SL-10 (Stryker Neurovascular) were used to enter the aneurysm sac or send the stent. In patients with simple coil embolization, under road mapping, the microcatheter was navigated into the aneurysm sac using a radifocus (Microvention/Terumo) and Syncro (Stryker Neurovascular) micro guide wire. The aneurysm sac was closed with the Axiom (Medtronic) and Target (Stryker Neurovascular) coils (Figure 1). Neuroform Atlas (Stryker) stents were used for stent neck modeling. In patients undergoing single stent neck modeling and coil embolization, the stent microcatheter was first placed in the area where the stent was intended to be opened, and the coil microcatheter was jailed into the aneurysm sac. After the stent was sent and opened through the microcatheter, the aneurysm sac was closed with coils. In patients undergoing Y-shaped stent and coil embolization, the stent microcatheter was placed in the vascular branch with a difficult aneurysm neck exit angle under road mapping. Then another microcatheter was jailed into the aneurysm sac. The first stent was sent from the stent microcatheter and opened. Then, through the glidewire manipulations, it was passed into the other branch through the meshes of the first stent and a microcatheter was inserted. A second stent was sent from this microcatheter and opened. After the Y-shaped stent configuration was provided, coils were sent from the microcatheter inside the aneurysm sac and the aneurysm was closed. While 0.010- and 0.018-inch coils were used in large aneurysms, 0.010-inch coils were used in small aneurysms. Three-dimensional (3D) images were taken for all aneurysms and aneurysm dimensions and vessel branches associated with the aneurysm neck were measured and determined from these images. The dimensions of the coils inserted into the aneurysm and the stents attached to the branches associated with the aneurysm neck were determined according to the data obtained from three-dimensional images. The antiaggregant treatment was continued for 6 months in patients for whom stent neck modeling was performed. The femoral access points were closed with vascular closure devices.

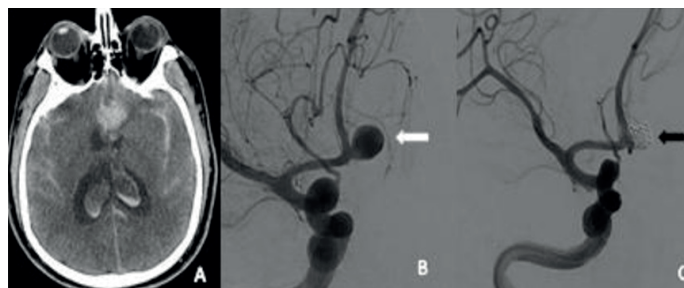


Figure 1. CT and procedural angiographic images of ACOM aneurysm causing subarachnoid hemorrhage. A. Subarachnoid hemorrhage that opens to the lateral ventricles in the interhemispheric fissure, bilateral sylvian fissures and sulcus. B. Narrow neck saccular aneurysm in ACOM localization (white arrow). C. Image after simple coil embolization into the aneurysm (black arrow)

Radiological and clinical follow-up

Brain Magnetic Resonance Angiography (MRA) was applied to all patients 3-6 months later. This was followed by the DSA after 9-15 months. Then, the patients were taken to annual MRA follow-ups. MRA and DSA follow-ups were performed by three experienced interventional neuroradiologists (M.K., I.O.Y., K.S). A second endovascular treatment decision was made in patients with significant morphological recurrence. Angiography results of coil embolization were evaluated according to the scale defined by Roy et al. (10). According to this scale, class 1 was evaluated the total aneurysm occlusion with no contrast to the aneurysm neck or sac, class 2 as the aneurysms remaining only as of the residual neck without contrast filling to the aneurysm sac, and class 3 as the aneurysm with contrast filling to the aneurysm sac.

The preprocedural clinical statuses of the patients were evaluated according to the Hunt-Hess grading. After the patients were discharged, their clinical statuses were evaluated according to the modified ranking scale (mRS). mRS 0-2 points were defined as good clinical results and 3-5 points were defined as bad clinical results. Complications that occurred within the first 30 days after endovascular procedure were considered as periprocedural. Complications after 30 days were considered as late complications.

RESULTS

Aneurysm characteristics

The data on the localization of aneurysms were shown in Table 3. The mean aneurysm size was measured as 8.7 mm (range, 3-23 mm). 65.6% of the aneurysms were small and measured as <10 mm. The dimensions of the remaining 34.3% were measured between 10-23mm. There were no giant aneurysms (> 25 mm). 56.25% of the aneurysms had a narrow neck (<4 mm) and the rest had a wide neck structure (> 4 mm).

Table 2. The initial post embolization occlusion grade of the aneurysms

Occlusion Grade	Description	Number of patients (%)
1	Complete occlusion	29 (82.8)
2	Residual neck	4 (11.5)
3	Contrast filling aneurysm sac	2 (5.7)

Embolization results and applicability of the treatment

Endovascular treatment could be applied to all aneurysms. The technical success in the embolization process was 100%. Primary coiling was performed in 53.1% of aneurysms, 31.2% of the remaining aneurysms were stent neck modeling and coil, 15.6% were Y stent neck modeling and coil embolization. Since the aneurysm dimensions were <3 mm in two patients, surgical treatment was recommended for high rupture risk. 81.25% (RR1) of the aneurysms, for which embolization was performed, were completely closed. While residual neck remained

in 12.5% (RR2) of remaining aneurysms, the partial filling was observed in aneurysm sac in 6.25% (RR3) (Table 2). For two aneurysms with partial filling (RR3), a second embolization was performed three months later, and these were completely closed (Figure 2). The stent neck modeling procedure was technically successfully performed in all patients.

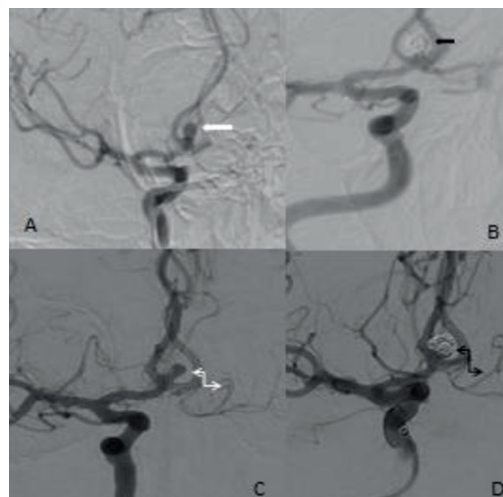


Figure 2. Procedural and follow-up angiography images of a 32-year-old male patient with ruptured ACOM aneurysm. A. Wide-necked saccular aneurysm in ACOM localization in procedural angiography (white arrow). B. Image after simple coil embolization into the aneurysm (black arrow). C. Significant residual filling in aneurysm on follow-up angiography after 6 months (curved white arrow). D. Total occlusion in aneurysm on angiographic image after second coil embolization (curved black arrow)

Table 3. The location of the cerebral aneurysms

Aneurysm localizations	Number of aneurysms (%)
Anterior circulation	32 (91.5)
ACA	
AcomA	15 (42.8)
ACA A1 segment	1 (2.8)
ACA pericallosal segment	2 (5.7)
Total	18 (51.4)
ICA	
Proximal ICA, paraophthalmic, cavernous	4 (11.4)
PcomA	5 (14.2)
Total	9 (25.7)
MCA	
Proximal (M1)	1 (2.8)
Bifurcation	4 (11.4)
Total	5 (14.2)
Posterior circulation	3 (8.5)
Basilar tip	1 (2.8)
Superior cerebellar artery	1 (2.8)
Vertebro-basillary junction	1 (2.8)

ACA: Anterior Cerebral Artery; AcomA: Anterior Communicating Artery; ICA: Internal Carotid Artery; MCA: Middlecerebral Artery; PcomA: Posterior Communicating Artery

Complications, complication management, and clinical results

Periprocedural complications developed in a total of 6 patients (18.75%). Aneurysm rupture occurred due to microcatheter manipulation in 1 patient (3.1%), major branch thrombosis in 2 patients (6.25%), and intrastent partial thrombus in 2 patients (6.25%). The aneurysm was closed by continuing to wrap the coil without retracting the coil catheter in the patient with developed aneurysm rupture. Decompressive surgery was performed after the procedure. The patient suffered from cardiac arrest 3 days after the operation and died. In patients with major branch occlusion, thrombectomy was performed with an aspiration catheter and full clearance was ensured (Figure 3). In patients with coil migration, the coils were attached to the vessel wall with a flow-guiding stent, and the aneurysm was closed completely, and full clearance was provided in the vessel lumen. In patients with developed partial thrombus within the stent, 1 mg/half an hour IV tirofiban infusion was performed and injection of 5 mg alteplase/5 minutes was made from the intraarterial thrombus proximal and thus the intra-stent partial thrombi were removed. Embolic acute infarcts were seen in vascular irrigation areas with complications in the Diffusion Magnetic Resonance imaging taken for control purposes 24 hours after the procedure in 5 patients who developed major branch occlusion, intrastent partial thrombus, and coil migration. However, four of these patients had mRS 0 in their clinical follow-up and no neurological sequelae were observed. Minimal dysarthria developed in only one patient with developed major branch occlusion and mRS 1 was calculated in the clinical follow-up.

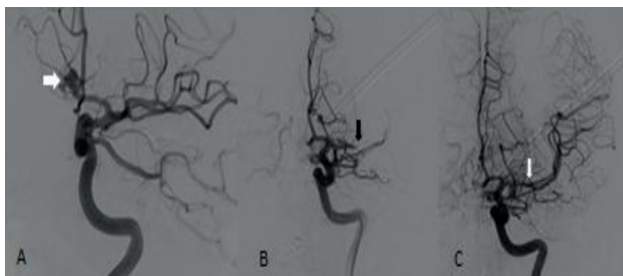


Figure 3. Procedural angiography images of a 45 year-old male patient with ruptured ACOM aneurysm. A. Narrow neck saccular aneurysm in ACOM localization (white arrow). B. After simple coil embolization, the aneurysm was totally closed (black arrow) in procedural angiography, but the distal of the MCA M1 segment was occluded (white arrow). C. After aspiration, MCA and distal branches are completely open

Mortality was seen in 11 (34.3%) patients in total. This was due to periprocedural complication in one of these patients and the remaining 10 patients died within the first two weeks due to late cerebral ischemia (6 patients), sepsis (2 patients), and cardio-pulmonary event (2 patients). The remaining 21 patients (65.6%) were clinically followed up for an average of 8 months (range, 3-22 months), and no patient died. While mRS was 0 in 18 (56.25%) of these patients, mRS was calculated as 1 in 1 patient (3.1%) and as 2 in 2 patients (6.25%). The late-term mortality and morbidity were calculated as 0.

DISCUSSION

Although there are different approaches to the timing of treatment of ruptured aneurysms, there is a consensus that early intervention significantly reduces mortality rates and gives better clinical results (6,7). There are two treatment approaches, namely surgical and endovascular embolization, and long-term results of endovascular treatment, such as death and dependent life, have been reported to be better (8). Although "The International Subarachnoid Aneurysm Trial (ISAT)", the first major prospective randomized controlled trial to evaluate the efficacy of endovascular therapy and compare it with surgery, especially in bleeding brain aneurysms (8), shows that clinical outcomes of endovascular embolization are better, some limitations in ISAT have been criticized. However, the ISAT II study, which started in 2012 in 50 centers and will be completed in 2024, is implemented free of these limitations, and it has been reported in the early results that the superiority of endovascular treatment continues as in ISAT I (11).

Two important problems in the long-term follow-up of endovascular treatment are higher recanalization and bleeding rates when compared to surgery. Renowden et al. reported complete aneurysm occlusion rates of 67%, 35%, and 11%, respectively, for small, large, and giant aneurysms in their series including 780 patients for whom they performed endovascular treatment (12). Murayama et al. reported complete occlusion rates of 72.9%, 40.8%, 41.4%, and 37.5%, respectively, for small, large-necked small, large, and giant aneurysms that they closed endovascularly (13). In the present study, 81.25% of aneurysms were completely closed. While residual neck remained in 12.5% of the remaining aneurysms, the partial filling was observed in the aneurysm sac in 6.25%. Complete occlusion was achieved in 86.8% and 68.5%, respectively, in small and large aneurysms. In the literature, the rate of recanalization after endovascular treatment varies between 14% and 34%. Numerous clinical, technical, and anatomical factors determine recanalization rates after endovascular treatment (14,15). The most important of these factors is the aneurysm diameter >10mm and the aneurysm neck width >4mm (16). Besides, the tight coiling of the aneurysm during the endovascular procedure is an important factor for recanalization during the follow-up. Technological developments in products such as new coil, intracranial stent, and intracranial balloon have led to a significant decrease in the recanalization rates (17,18). The high total complete ratios and low residual aneurysm rates in the present study were compatible with the literature, and it was evaluated that this was due to the aneurysm neck modeling methods used in many patients and the tight insertion of coils into the aneurysm.

Rebleeding may occur within the first week after embolization. Factors such as the amount of coiling inside the aneurysm, operator's experience, the timing of embolization determine the rate of rebleeding. In the literature, rebleeding rates have been reported between 0% and 4.9% (12,19,20). In the present study, the rate of

rebleeding after endovascular treatment is 0%, and the reasons are thought to be to intervene in the first 24 hours of bleeding aneurysms and to tightly coil the aneurysm.

On the other hand, thromboembolic complications are an important problem in endovascular treatments. It is known that coagulation is higher in patients who have bleeding, especially in ruptured aneurysms, and thromboembolic complication rates after endovascular treatment have been reported to be between 2.5% and 28%. Again, in these studies, the permanent disability and death rates due to thromboembolic complications were reported to be 1.4% to 5.9% (16,21). It is recommended to treat intraprocedural thromboembolisms with intra-arterial r-tPA and intraarterial/intravenous glycoprotein IIb/IIIa inhibitors (22,23). In the present study, the intraprocedural thromboembolic complication was 12.5% and recanalization was achieved in the full vessels with intra-arterial r-tPA and intravenous tirofiban infusion. No morbidity or mortality was observed due to these complications.

Intraprocedural aneurysm rupture is a serious and high mortality-morbidity complication of endovascular treatment and is reported to be between 1.4% and 16% (7,12,16,18). Ruptures are reported in <10 mm aneurysms located mostly in the anterior communicating artery (AcomA) and middle cerebral artery bifurcation (12,21,25). In the present study, the rate of rupture (1 patient-3.1%) and the location-size characterization of the aneurysm were similar to those in the literature, and the rupture with developing aneurysm was 6 mm in diameter localized in AcomA. The most important factors that determine the rate of intraprocedural rupture are thought to be the aneurysm size and the operator's experience (21,25).

The mortality rates are above 45% in patients with SAH, and severe morbidity rates have been reported in surviving patients (1,4,26,27). Although intraprocedural and postprocedural treatment is in optimal conditions in the treatment of aneurysm, late cerebral ischemia is one of the main causes of mortality. Although cerebral vasospasm is observed in 70% of patients with SAH, approximately 30% of these patients have late cerebral ischemia, which is effective in their clinical outcomes (26,27). In ruptured aneurysms, the neurological status at presentation and the amount of extravasated blood seen on CT scan are closely related to the outcome clinical outcomes of patients and the possibility of having vasospasm (30-32). Fisher scale and clinically preprocedural Hunt-Hess grade in CT have the deepest effect on 1-year bad results (33,34). There is a six fold increased risk in those with Hunt-Hess grade 4 and 5, and fourfold increased risk in those with Fisher scale 3 and 4, in terms of mortality (35). In this study, mortality was not observed in any of our patients with Hunt-Hess grade below 4 and Fisher scale below 3, and 6 patients (18.75%) with Hunt scale of 4 or 5 and Fisher scale 3 or 4 died due to late cerebrovascular vasospasm.

There are several limitations to this study. This is a retrospective and single-centered study conducted in a

relatively small group of patients. Also, the apparent low of the number of posterior system aneurysms is another important limitation of the study.

CONCLUSION

In conclusion, in this study, high technical success rate, low complication and mortality rates, and high rates of total aneurysm closure were determined in the early period of endovascular treatment in ruptured aneurysm cases. It is considered that endovascular treatment is an applicable, safe and effective treatment method in ruptured aneurysms.

Conflict of interest : The authors declare that they have no competing interest.

Financial Disclosure: There are no financial supports.

Ethical approval: Approval was obtained from the institutional review ethics committee of Harran University with the date and number 01.06.2020-E.19369.

REFERENCES

1. Bederson JB, Connolly ES Jr, Batjer HH, et al. Guidelines for the management of aneurysmal subarachnoid hemorrhage: a statement for healthcare professionals from a special writing group of the Stroke Council, American Heart Association. *Stroke* 2009;40:994-1025.
2. D'Souza S. Aneurysmal Subarachnoid Hemorrhage. *J Neurosurg Anesthesiol* 2015;27:222-40.
3. Grasso G, Alafaci C, Macdonald RL. Management of aneurysmal subarachnoid hemorrhage: State of the art and future perspectives. *Surg Neurol Int* 2017;8:11.
4. Van Gijn J, Kerr RS, Rinkel GJ. Subarachnoid haemorrhage. *Lancet* 2007;369:306-18.
5. Solenski NJ, Haley EC Jr, Kassell NF, et al. Medical complications of aneurysmal subarachnoid haemorrhage: a report of the multicentre, cooperative aneurysm study. *Crit Care Med* 1995;23:1007-17.
6. Molyneux AJ, Kerr RS, Stratton I, et al. International Subarachnoid Aneurysm Trial (ISAT) of neurosurgical clipping versus endovascular coiling in 2143 patients with ruptured intracranial aneurysms: a randomized trial. *Lancet* 2002;360:1267-74.
7. Yao Z, Hu X, Ma L, et al. Timing of surgery for aneurysmal subarachnoid hemorrhage: A systematic review and meta-analysis. *Int J Surg* 2017;48:266-74.
8. Phillips TJ, Dowling RJ, Yan B, et al. Does treatment of ruptured intracranial aneurysms within 24 hours improve clinical outcome? *Stroke* 2011;42:1936-45.
9. Suarez JI. Diagnosis and Management of Subarachnoid Hemorrhage. *Continuum (Minneapolis)* 2015;21:1263-87.
10. Roy D, Milot G, Raymond J. Endovascular treatment of unruptured aneurysms. *Stroke* 2001;32:1998-2004.
11. Darsaut TE, Jack AS, Kerr RS, et al. International Subarachnoid Aneurysm Trial - ISAT part II: study protocol for a randomized controlled trial. *Trials* 2013;14:156.

12. Renowden SA, Benes V, Bradley M, et al. Detachable coil embolisation of ruptured intracranial aneurysms: a single center study, a decade experience. *ClinNeurolNeurosurg* 2009;111:179-88.
13. Murayama Y, Nien YL, Duckwiler G, et al. Guglielmi detachable coil embolization of cerebral aneurysms: 11 years' experience. *J Neurosurg* 2003;98:959-66.
14. van Rooij WJ, Sluzewski M, Beute GN, et al. Procedural complications of coiling of ruptured intracranial aneurysms: incidence and risk factors in a consecutive series of 681 patients. *AJNR Am J Neuroradiol* 2006;27:1498-501.
15. Plowman RS, Clarke A, Clarke M, et al. Sixteen-year single-surgeon experience with coil embolization for ruptured intracranial aneurysms: recurrence rates and incidence of late rebleeding. *J Neurosurg* 2011;114:863-74.
16. Henkes H, Fischer S, Weber W, et al. Endovascular coil occlusion of 1811 intracranial aneurysms: early angiographic and clinical results. *Neurosurgery* 2004;54:268-80.
17. Geyik S, Yavuz K, Ergun O, et al. Endovascular treatment of intracranial aneurysms with bioactive Cerecyte coils: effects on treatment stability. *Neuroradiology* 2008;50:787-93.
18. Ferns SP, Sprengers ME, van Rooij WJ, et al. Coiling of intracranial aneurysms: a systematic review on initial occlusion and reopening and retreatment rates. *Stroke* 2009;40:523-29.
19. Willinsky RA, Peltz J, da Costa L, et al. Clinical and angiographic follow-up of ruptured intracranial aneurysms treated with endovascular embolization. *AJNR Am J Neuroradiol* 2009;30:1035-40.
20. CARAT Investigators. Rates of delayed rebleeding from intracranial aneurysms are low after surgical and endovascular treatment. *Stroke* 2007;37:1437-42.
21. Park HK, Horowitz M, Jungreis C, et al. Periprocedural morbidity and mortality associated with endovascular treatment of intracranial aneurysms. *AJNR Am J Neuroradiol* 2005;26:506-14.
22. Hähnel S, Schellinger PD, Gutschalk A, et al. Local intra-arterial fibrinolysis of thromboemboli occurring during neuroendovascular procedures with recombinant tissue plasminogen activator. *Stroke* 2003;34:1723-8.
23. Ries T, Siemonsen S, Grzyska U, et al. Abciximab is a safe rescue therapy in thromboembolic events complicating cerebral aneurysm coil embolization: single center experience in 42 cases and review of the literature. *Stroke* 2009;40:1750-7.
24. Pandey AS, Koebbe C, Rosenwasser RH, et al. Endovascular coil embolization of ruptured and unruptured posterior circulation aneurysms: review of a 10-year experience. *Neurosurgery* 2007;60:626-36.
25. Ricolfi F, Le Guerinel C, Blustajn J, et al. Rupture during treatment of recently ruptured aneurysms with Guglielmielectrodetachable coils. *AJNR Am J Neuroradiol* 1998;19:1653-8.
26. Hijdra A, Braakman R, van Gijn J, et al. Aneurysmal subarachnoid hemorrhage: complications and outcome in a hospital population. *Stroke* 1987;18:1061-7.
27. Hop JW, Rinkel GJ, Algra A, et al. Changes in functional outcome and quality of life in patients and caregivers after aneurysmal subarachnoid hemorrhage. *J Neurosurg* 2001;95:957-63.
28. Francoeur CL, Mayer SA. Management of delayed cerebral ischemia after subarachnoid hemorrhage. *Crit Care* 2016;20:277.
29. Millikan CH. Cerebral vasospasm and ruptured intracranial aneurysm. *Arch Neurol* 1975;32:433-49.
30. O'Sullivan MG, Dorward N, Whittle IR, et al. Management and long-term outcome following subarachnoid haemorrhage and intracranial aneurysm surgery in elderly patients: an audit of 199 consecutive cases. *Br J Neurosurg* 1994;8:23-30.
31. Bekelis K, Missios S, Mackenzie TA, et al. A predictive model of outcomes during cerebral aneurysm coiling. *J NeurointervSurg* 2014;6:342-8.
32. Stienen MN, Germans M, Burkhardt JK, et al. Predictors of in-hospital death after aneurysmal subarachnoid hemorrhage: analysis of a nationwide database (Swiss SOS [Swiss study on aneurysmal subarachnoid hemorrhage]). *Stroke* 2018;49:333-40.
33. Rivero Rodriguez D, Scherle Matamoros C, Fernandez Cue L, et al. Factors associated with poor outcome for aneurysmal subarachnoid haemorrhage in a series of 334 patients. *Neurologia* 2015;S0213-4853(14)00269-2.
34. Bonilha L, Marques EL, Carelli EF, et al. Risk factors and outcome in 100 patients with aneurysmal subarachnoid hemorrhage. *ArqNeuropsiquiatr* 2001;59:67-80.
35. Osawa M, Hongo K, Tanaka Y, et al. Results of direct surgery for aneurysmal subarachnoid haemorrhage: outcome of 2055 patients who underwent direct aneurysm surgery and profile of ruptured intracranial aneurysms. *ActaNeurochir (Wien)* 2001;143:655-63.