

# Is abdominal wall hemorrhage an avoidable complication of robotic radical prostatectomy?

 Erdem Koc,  Bahri Gok

Department of Urology, Faculty of Medicine, Ankara Yildirim Beyazit University, Ankara, Turkey

Copyright © 2020 by authors and Annals of Medical Research Publishing Inc.

## Abstract

**Aim:** We presented the diagnosis and treatment of patients with abdominal wall hemorrhage after robot-assisted laparoscopic radical prostatectomy (RALRP) in a high volume center.

**Materials and Methods:** We retrospectively screened the data of 1950 patient RALRP series performed between June 2010 and December 2019 in our clinic. Patients who developed postoperative abdominal wall hemorrhage were included in the current study. The diagnosis of abdominal wall hemorrhage was established by ultrasonographic and physical examination findings.

**Results:** In our 1950 patient RALRP series, 15 (0.7%) patients developed abdominal wall hemorrhage. The mean decrease in hemoglobin values was 3.9 (2.8-4.7) g/dl at postoperative 6<sup>th</sup> hour. On the postoperative 2<sup>nd</sup> day, areas of ecchymosis were observed on the abdominal wall skin. On the postoperative 4<sup>th</sup> day, hemoglobin level was stabilized. Blood transfusion was required for 8 of 15 patients. None of the patients required surgical exploration. At the postoperative 1<sup>st</sup> month control visits, we observed that the ecchymosis was completely disappeared.

**Conclusion:** RALRP is a surgical technique that has been increasingly preferred in the treatment of localized prostate cancer. Abdominal wall hemorrhage is a rarely seen complication of RALRP that may be avoided by paying attention to some anatomical landmarks and optimizing the blood level of muscle relaxant medications at an effective dose. As a rarely seen complication of RALRP, abdominal wall hemorrhage can be successfully managed without the need for explorative surgery.

**Keywords:** Hemorrhage; prostate cancer; robotic surgical procedures

## INTRODUCTION

Prostate cancer is the second most common cancer in men worldwide after lung cancer and ranked 5<sup>th</sup> among the malignancies of men in terms of cancer-related mortality (1). Surgical treatment of localized prostate cancer may be performed by robot-assisted, laparoscopic or open surgery. Robot-assisted laparoscopic radical prostatectomy (RALRP) has better results in terms of functional results such as erection and urinary continence, as well as similar oncological results with open surgery, by the latest technological advances and increasing surgical experience with the high number of robotic surgery cases (2,3). Despite difficulties such as lack of tactile feeling and limited camera viewing angle, high quality optical magnification and the lack of hand tremor are the significant advantages of robotic surgery. Robotic surgery has unique complications, even though it has lower morbidity and mortality rates than open surgery. Complications in laparoscopic and robotic surgery may be seen related with Verress needle, trocar entry, Trendelenburg position and/or creation of the pneumoperitoneum (4).

Abdominal wall hemorrhage is one of the rarely seen complications of the robotic surgery. There are two studies in literature related with the abdominal wall hemorrhage. However, these studies included a small number of cases (5,6). In our current study, we aimed to present the underlying factors, diagnosis and management of abdominal wall hemorrhages seen in a large patient series of RALRP which were reported at a high volume center.

## MATERIALS and METHODS

A total of 1950 RALRP operations were performed in our clinic between June 2010 and December 2019. The cases recorded in our database were screened retrospectively and patients who developed hematoma in the abdominal wall in the postoperative period were included in our current study. The diagnosis of abdominal wall hemorrhage was established by physical examination and ultrasonographic (USG) evaluation findings. Demographic data, intraoperative and postoperative data and oncological results of the patients with abdominal wall hemorrhage were recorded. RALRP was performed transperitoneally at 30° Trendelenburg position under general anesthesia. In

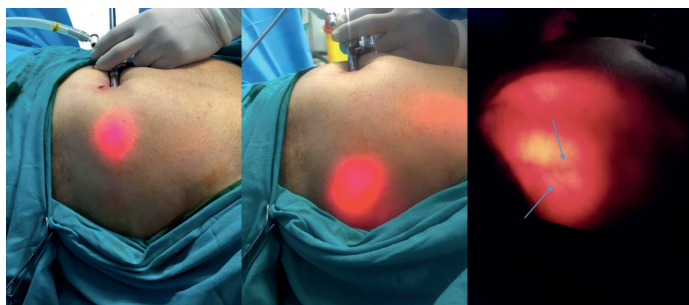
**Received:** 11.07.2020 **Accepted:** 30.10.2020 **Available online:** 10.11.2020

**Corresponding Author:** Erdem Koc, Department of Urology, Faculty of Medicine, Ankara Yildirim Beyazit University, Ankara, Turkey

**E-mail:** drerdemkoc@gmail.com

our clinic, we used Da Vinci S Robotic System (Intuitive Surgical, Sunnyvale, CA, USA) between the 2010 and 2014, however, we started to use Da Vinci Xi Robotic System (Intuitive Surgical, Sunnyvale, CA, USA) after 2014. A total of 5 ports were used for the surgery. For robotic arms, 8 mm metal ports and a 12 mm assistant port were used. As the port sizes considered, Da Vinci S and Da Vinci Xi Robotic Systems were only different in terms of camera port diameters (8 mm and 12 mm, respectively). Additionally, Da Vinci S Robotic System uses an ellipsoid line and Da Vinci Xi uses straight, however, there was no difference between the two systems in terms of distance to the umbilicus regarding to the placement of the robotic arms.

Direct access with Veress needle technique was performed to patients who had not any previous abdominal surgery, open access with Hasson technique was performed otherwise. After the creation of pneumoperitoneum, the first port (camera port) was placed approximately 2 cm above the umbilicus. An 8 mm robotic port was placed at 10 cm lateral to the camera port at left-side and 8 mm two robotic ports were placed at right lateral side with an interval of 8 cm. A 12 mm assistant port was placed in the middle of the robotic port at the left-side and the camera port. The abdominal vasculature on trocar entry areas was visualized internally through direct visualisation and externally under transillumination (Figure 1).



**Figure 1.** Visualisation of abdominal wall vasculature under transillumination

At the end of the operation, intra-abdominal pressure was decreased to 5 mmHg as a routine approach to evaluate whether there was any bleeding. Afterwards, a drainage catheter was placed through the urethro vesical anastomosis region, generally from the trocar hole on the right-side. The incision above the umbilicus was widened and the prostate specimen was taken out.

Five patients were using an antiaggregant medication due to the medical history of coronary artery disease. The antiaggregant medication was stopped 5 days before the operation. On the postoperative 1st day, 0.4 mg low molecular weight heparin was started to all of the patients except for those with suspected bleeding, as a routine postoperative medication.

If there was no contraindication, we gave nonsteroidal anti-inflammatory drugs (NSAIDs) in routine postoperative medication of the patients. In cases that we suspected from bleeding, we stopped the NSAIDs and gave opioids or paracetamol instead.

Statistical analyses were performed by using the SPSS software version 17.0 (SPSS Inc., Chicago, IL). A total of 15 patients were involved in statistical analyses. Descriptive statistics were presented by using Median (IQR) values. This study was conducted according to Declaration of Helsinki. Ankara Yıldırım Beyazıt University Editorial Review Board (22/04/2020 #17) approved the study.

## RESULTS

**Table 1. Demographic characteristics, clinical features and operative data of the patients**

<b>Total number of patients with abdominal wall hemorrhage (n)</b>	15
<b>Age (years) [(Median (IQR))]</b>	66 (62.6-69.6)
<b>BMI (kg/m<sup>2</sup>) [(Median (IQR))]</b>	28.9 (27-30)
<b>PSA (ng/dl) [(Median (IQR))]</b>	9.1 (7.5-28)
<b>Prostate volume (ml) [(Median (IQR))]</b>	58 (49-82)
<b>Biopsy Gleason score</b>	
Grade Grup 1 (n)	8
Grade Grup 2 (n)	3
Grade Grup 3 (n)	1
Grade Grup 4 (n)	2
Grade Grup 5 (n)	1
<b>Mean operation time (min) [(Median (IQR))]</b>	190 (170-240)
<b>EBL (ml) [(Median (IQR))]</b>	70 (50-80)
<b>Mean hospitalization time (day) [(Median (IQR))]</b>	6 (5-11)
<b>Drain removal time (day) [(Median (IQR))]</b>	3 (2-4)
<b>Transurethral catheter removal time (day) [(Median (IQR))]</b>	8 (7-9)
<b>Preoperative Hgb value (g/dL) [(Median (IQR))]</b>	12.3 (11.9-14)
<b>Postoperative 6<sup>th</sup> hour Hgb decrease (g/dL) [(Median (IQR))]</b>	3.9 (2.8-4.7)
<b>Postoperative 1<sup>st</sup> day Hgb decrease (g/dL) [(Median (IQR))]</b>	2.1 (1.2-2.7)
<b>Postoperative 2<sup>nd</sup> day Hgb decrease (g/dL) [(Median (IQR))]</b>	1.1 (0.7-1.3)
<b>Postoperative 3<sup>rd</sup> day Hgb decrease (g/dL) [(Median (IQR))]</b>	0.4 (0.2-0.6)
<b>Pathologic Biopsy Score</b>	
Grade Grup 1 (n)	7
Grade Grup 2 (n)	3
Grade Grup 3 (n)	2
Grade Grup 4 (n)	2
Grade Grup 5 (n)	1
<b>Pathologic T Stage</b>	
T2a (n)	4
T2b (n)	4
T2c (n)	3
T3a (n)	2
T3b (n)	2

**RALRP:** Robot-assisted laparoscopic radical prostatectomy, **PSA:** Prostate specific antigen, **Hgb:** Hemoglobin, **EBL:** Estimated blood loss, **BMI:** Body mass index

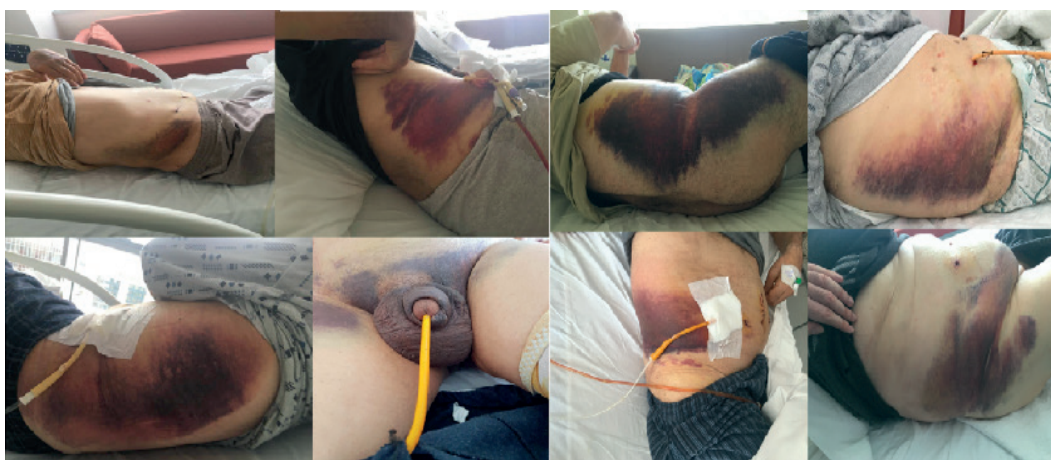In current study, we observed 15 (0.7%) abdominal wall hemorrhages in our 1950 RALRP series. From these patients, 6 patients had been operated with Da Vinci S Robotic System and 9 with Da Vinci Xi. Patients' demographic characteristics, clinical features and operative data are given in Table 1. Nerve-sparing surgery was performed at 10 patients of which unilaterally in 2 and bilaterally in 8.

Blood transfusion was required for 8 of 15 patients. Three patients received 2 units, five patients received 1 unit of blood transfusion. On the postoperative 4<sup>th</sup> day, the hemoglobin levels were stabilized.

Pelvic lymph node dissection was performed in 6 patients. Pathologic lymph node metastasis was detected in 1 patient.

USG was performed at postoperative 2<sup>nd</sup> day due to ecchymosis of abdominal wall skin on the right-side in 13 patients and on the left-side in 2 patients. USG revealed abdominal wall hematoma between the abdominal muscles extending to the abdominal skin. In the following days, the hematoma extended through the scrotum and legs (Figure 2).

None of the patients had active drainage from the abdominal drainage catheter. The mean drain removal time was 3 (2-6) day. The areas of ecchymosis were observed as completely disappeared in all patients at routine postoperative 1st month control visit. Surgical exploration was not needed for any patient.



**Figure 2.** Echimoses observed at skin of abdominal wall, scrotum and legs

## DISCUSSION

RALRP is an increasingly preferred surgical procedure with lower morbidity rate compared to open surgery. However, it has a unique complication scale (7). Peripheral nerve damage and compartment syndrome depending on the patient position (8), posterior ischemic optic neuropathy and laryngeal edema depending on Trandelenburg position, pneumomediastinum, pneumothorax, gas embolism, and hypercarbia related to pneumoperitoneum (9,10) are the most commonly seen complications which are specific to the laparoscopic surgery.

Vascular injuries in RALRP mostly develop during trocar placement and lymphadenectomy. Bleeding and bowel damage may develop during the entry of the trocar and Verress needle. The bleeding was reported as most commonly arise from the dorsal vein complex, lateral pedicles and port insertions (11). In our patient series, neither the Verress needle nor the trocar placements were complicated by vascular or intestinal damage. Previous studies reported their bleeding rates between 0.5% and 2% after RALRP (12-15). The surgeon can successfully overcome the bleeding if it is detected intraoperatively. However, increased intraabdominal pressure may prevent to observe the bleeding through

the ongoing surgery and these cases may be presented with postoperative hemorrhage. Therefore, at the end of the operation, intraabdominal pressure should be decreased and the surgical reexploration should be performed for haemostasis. In our 1950 patient series, 38 patient received 1 unit, 5 patients received 2 unit and 2 patients received 3 units of blood transfusion. Explorative laparotomy was performed in 2 patients due to persistent bleeding at postoperative follow-up period and we detected that bleeding arised from inferior epigastric artery in one patient, however, we could not find the focus of bleeding in the other one. However, none of the explorative surgeries was performed for the abdominal wall hemorrhage cases. Not all but nearly half of the abdominal wall hemorrhage cases needed blood transfusion.

In a study conducted by Bhoirul et al., 629 trocar complications which developed in laparoscopic surgery cases performed by general surgery and gynecology clinics were presented. They reported 408 major vascular injuries, 182 intestinal damage and 30 abdominal wall hematoma. However none of the cases were performed by robotic surgery. However, there was no information on how many total cases were performed from which

these complications were seen. The study also did not discuss the possible causes of abdominal wall hematoma development and their treatment approach (16). Hashizume et al. reported abdominal wall hemorrhage as 0.46% (n=70) in their 15442 laparoscopic case series, most of which were laparoscopic cholecystectomy. From overall 70 abdominal wall hemorrhage cases, 4 patients underwent laparotomy and 30 patients were followed without any intervention (17). Bhattacharya et al. reported abdominal wall hematoma as 6.25% (n=4) in their 61 patient laparoscopic cholecystectomy series. The patients applied with pain and bruising on the abdominal skin. None of the patients required explorative surgery. Patients were discharged after blood transfusion and analgesic therapy (18). Marcovici et al. reported decreased hemoglobin level and oliguria at postoperative 1<sup>st</sup> day in a left adnexial mass which they performed laparoscopy. The small periumbilical hematoma which appeared at postoperative 1<sup>st</sup> day became prominent at postoperative 3<sup>rd</sup> day. The patient was discharged after blood transfusion without any need for surgical exploration (19).

Our study is important to be the largest patient series of abdominal wall hemorrhage, which developed after robotic surgeries performed in a high volume center. There are two studies in literature which presented the abdominal wall hemorrhage cases in RALRP. Fischer et al. reported 8 abdominal wall hemorrhage which were developed in their 210 patient robotic radical prostatectomy series. They reported that from the 8 patients with abdominal wall hemorrhage, spontaneous resolution was seen in 5 patients, percutaneous drainage was applied to 2 patients and open revision was performed to 1 patients. In our current series, all cases were resolved spontaneously and we did not need any invasive intervention. Tasci et al. reported the ratio of abdominal wall hemorrhage after RALRP as 1.5% (n=5) in their 317 patient series and they reported that all of the 5 patients needed blood transfusion. It was not reported that in which body side the hemorrhage was seen (5). In our patient series, the time when we firstly observed ecchymosis at abdominal wall was similar with this previous one. However, contraversally, both the blood transfusion rate (53%) and the incidence of abdominal wall hemorrhage (0.7%) was significantly low in our current study.

In our case series, we detected no vascularisation both in skin-side observation and intraabdominal-side observation of abdominal wall during the transillumination which was performed before trocar placement. Trocar injuries are usually unrecognized during the surgical performance due to the tamponade effect of the pneumoperitoneum and the reduction in venous return due to the steep Trendelenburg position. However, we observed no bleeding at the end of the surgery under reduced intraabdominal pressure and supine position. The bleeding was probably arised from the adjacent tissue of the trocar entry points.

Possible causes of the bleeding may include injury of the vessels due to the stretching during trocar entry and trauma related with rapid movements of the robotic arm.

The vessel injury may as well as result from intermittent loss of the effect of muscle relaxant medication, which must be maintained at an effective dose during the surgery. As the clinical outcomes, the rapid movements of robotic arms should be avoided and the muscle relaxant medication should be maintained at the effective dose throughout the surgical performance.

We detected the abdominal wall hemorrhage mostly on the right-side. This was a remarkable finding and may be explained by some anatomical clues which may be considerable to pay attention in surgical practice. The right-side lateral port was at approximately 16 cm lateral to the umbilicus and was the most laterally placed port in RALRP. Unlikely the other port sites, here there is no fascia aponeurosis which may smoothen the tissue trauma arising from rapid movements of the robotic arms. Therefore, in this port site, especially the small diameter veins are under increased risk to be damaged. When the abdominal wall anatomy is considered, the possibility of vascular variation not differs between the left and right side. Supporting the data, we did not observe any more abdominal wall hemorrhage in our latest 300 cases that we started to place the right-side lateral port to 2 cm medially than in the conventional approach.

## CONCLUSION

Robotic surgery is a rapidly increasing surgical technique in the treatment of localized prostate cancer. Although RALRP has lower morbidity rate compared to open surgery, it has a unique complication scale. Abdominal wall haemorrhage may be related to the technique used in robotic surgery especially on the right-side, or may develop due to the changes of mechanical forces during the movement of the robotic arms and alterations in the effectiveness of muscle relaxant medications. However, this complication can be successfully managed by expectant clinical follow-up or blood transfusion without any need for explorative surgery.

*Conflict of interest: The authors declare that they have no competing interest.*

*Financial Disclosure: There are no financial supports.*

*Ethical approval: The study was approved by Ankara Yıldırım Beyazıt University ethical committee (Approval number: 22.04.2020-17).*

## REFERENCES

1. Bray F, Ferlay J, Soerjomataram I, et al. Global cancer statistics 2018: GLOBOCAN estimates of incidence and mortality worldwide for 36 cancers in 185 countries. *CA Cancer J Clin* 2018;68:394-424.
2. Yaxley JW, Coughlin GD, Chambers SK, et al. Robot-assisted laparoscopic prostatectomy versus open radical retropubic prostatectomy: early outcomes from a randomised controlled phase 3 study. *The Lancet* 2016;388:1057-66.
3. Karabulut I, Yilmazel FK, Yilmaz AH, et al. Robot-assisted laparoscopic radical prostatectomy: A single center initial experience. *Ann Intern Med* 2019;26: 2743-7.

4. Koc E, Canda AE . Robotic urologic surgery complications. MIS J 2018; 2: 7.
5. Tasci AI, Simsek A, Tugcu V, et al. Abdominal wall haemorrhage after robotic-assisted radical prostatectomy: Is it a complication of robotic surgery?. ActasUrol Esp 2013; 37:634-9.
6. Fischer B, Engel N, Fehr JL, et al. Complications of robotic assisted radical prostatectomy. World J Urol 2008;26:595-602.
7. Tewari A, Sooriakumaran P, Bloch DA, et al. Positive surgical margin and perioperative complication rates of primary surgical treatments for prostate cancer: a systematic review and meta-analysis comparing retropubic, laparoscopic, and robotic prostatectomy. Eur Urol 2012;62:1-15.
8. Pridgeon S, Bishop CV, Adshead J. Lower limb compartment syndrome as a complication of robot-assisted radical prostatectomy: the UK experience. BJU Int 2013;112:485-8.
9. Kan KM, Brown SE, Gainsburg DM. Ocular complications in robotic-assisted prostatectomy: a review of pathophysiology and prevention. Minerva Anesthesiol, 2015;81:557-66.
10. Bjørø B, Mykkeltveit I, Rustøen T. Intraoperative peripheral nerve injury related to lithotomy positioning with steep Trendelenburg in patients undergoing robotic-assisted laparoscopic surgery—a systematic review. J Adv Nurs 2020;76:490-503.
11. Stolzenburg JU, Rabenalt R, Do M, et al. Complications of endoscopic extraperitoneal radical prostatectomy (EERPE): prevention and management. World J Urol 2006;24:668-75.
12. Zorn KC, Gofrit ON, Orvieto MA, et al. Da Vinci robot error and failure rates: single institution experience on a single three-arm robot unit of more than 700 consecutive robot-assisted laparoscopic radical prostatectomies. J Endourol 2007;21:1341-4.
13. Badani KK, Kaul S, Menon M. Evolution of robotic radical prostatectomy: assessment after 2766 procedures. Cancer 2007;110:1951-8.
14. Patel VR, Thaly R, Shah K. Robotic radical prostatectomy: outcomes of 500 cases. BJU Int 2007;99:1109-12.
15. Novara G, Ficarra V, D'Elia C, et al. (2010). Prospective evaluation with standardised criteria for postoperative complications after robotic-assisted laparoscopic radical prostatectomy. Eur Urol 2010;57:363-70.
16. Bhoyrul S, Vierra MA, Nezhat CR, et al. Trocar injuries in laparoscopic surgery. J Am Coll Surg 2001;192:677-83.
17. Hashizume M, Sugimachi K. Needle and trocar injury during laparoscopic surgery in Japan. Surg Endosc 1997; 11:1198–201.
18. Bhattacharya S, Tate JJT, Davidson BR, et al. Abdominal wall haematoma complicating laparoscopic cholecystectomy. HPB Surgery 1994;7:291-6.
19. Marcovici I. Significant abdominal wall hematoma from an umbilical port insertion. JSLS 2001;5:293.