



An Unusual Presentation of Cardiac Hydatid Cyst: Ventricular Tachycardia

Necip Ermiş*, Hakan Altay**, Hilal Ermiş***, Fahri Tercan****

* İnönü University Medical Faculty, Department of Cardiology, Malatya

** Başkent University, Medical Faculty, Department of Cardiology, Adana

*** İnönü University Medical, Faculty, Department of Chest Diseases, Malatya

**** Başkent University Medical Faculty, Department of Radiology, Adana

A 35-year-old man was admitted to our hospital's emergency department with chest pain, lightheadedness and long lasting palpitation. Twelve lead electrocardiography revealed wide QRS tachycardia suggesting sustained ventricular tachycardia at the rate of 220 beats per minute. Transthoracic echocardiography revealed a cystic mass with a size of 5x6 cm located intramyocardially in the left ventricular lateral wall. T2 weighted images of cardiac magnetic resonance imaging showed the mass of 6x7x5 cm in size, compatible with hydatid cyst in the left ventricular lateral wall. Specific blood tests for hydatid cyst were positive. Combination of antihelminthic chemotherapy to be followed by surgical excision of the cyst was planned but, the patient refused to undergo a cardiac surgery. Hence, the patient was discharged with albendazole and amiodarone treatment.

Key Words: Cardiac Hydatid Cyst, Ventricular Tachycardia, Magnetic Resonance Imaging

Nadir bir Kardiyak Kist Hidatid Prezantasyonu: Ventriküler Taşikardi

35 yaşındaki erkek hasta, göğüs ağrısı, baş dönmesi ve uzun süren çarpıntı ile acil servise başvurdu. 12 kanallı elektrokardiyografide ventriküler taşikardiyi düşündüren 220/dk. hızında geniş QRS'li taşikardi saptandı. Transtorasik ekokardiyografide sol ventrikül lateral duvan intra myokardiyal yerleşimli 5x6 cm'lik kistik kitle izlendi. Kardiyak magnetik rezonans, T2 ağırlıklı görüntülerde sol ventrikül lateral duvarda 6x7x5 cm büyüklüğündeki kitlenin kist hidatid ile uyumlu olduğunu gösterdi. Kist hidatid için yapılan kan testleri pozitif saptanan hastaya antihelmintik tedaviye takiben kistin cerrahi olarak çıkarılması planlandı ancak hasta kardiyak cerrahiyi kabul etmedi, bu nedenle hasta albendazol ve amiodaron tedavisi ile taburcu edildi.

Anahtar Kelimeler: Kardiyak Kist Hidatid, Ventriküler Taşikardi, Magnetik Rezonans Görüntüleme

Introduction

Cystic Hydatid disease which is still endemic in sheep raising countries is a parasitic infection with the metacystode stage of the tapeworm *Echinococcus*. *Echinococcus granulosus* is the commonest species infecting humans. Hydatid cysts have been documented in almost all of the organs. The incidence of cardiac involvement is very low and, it occurs in about 0.5 to 3% of all hydatid infestations.

Here we report a case of hydatid cyst localized in the lateral wall of left ventricle presenting with angina and ventricular tachycardia. It was detected by transthoracic echocardiography and confirmed by cardiac magnetic resonance imaging (MRI) and specific blood tests for hydatid cyst.

Case report

A 35-year old man was admitted to our hospital's emergency department with chest pain, lightheadedness and long lasting palpitation. His physical examination was unremarkable except for tachycardia. Twelve lead electrocardiogram (ECG) revealed wide QRS tachycardia suggesting sustained ventricular tachycardia at the rate of 220 beats per minute (Figure 1). His blood pressure was 100/70 mmHg, so he was treated medically and hospitalized. Transthoracic echocardiography revealed a 5x6 cm uncalcified cystic mass showing initial septation located intramyocardially in the left ventricular lateral wall (Figure 2). Other parameters of echocardiography, including size of the heart chambers, diastolic and systolic functions were normal. Afterwards, cardiac magnetic resonance imaging (MRI) was performed with a 1.5-T system (Symphony, Siemens Medical Solutions) with ECG triggering. A hypo intense on T1-weighted images and hyper intense on T2-weighted images with a size of

Başvuru Tarihi: 16.02.2010, Kabul Tarihi: 24.06.2010

6x7x5 cm and membrane detachment, compatible with hydatid cyst in the left ventricular lateral wall was detected by MRI, in concordance with the findings on echocardiography (Figure 3).

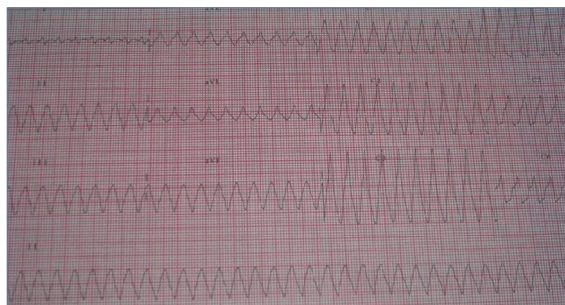


Figure 1. Patient's ECG, showing wide QRS tachycardia

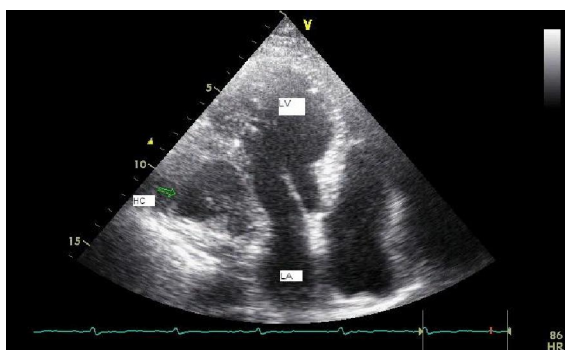


Figure 2. An apical four chamber view of the hydatid cyst (HC), located intramyocardially at the left ventricular lateral wall. LA; left atrium, LV; left ventricle, HC; Hydatid cyst

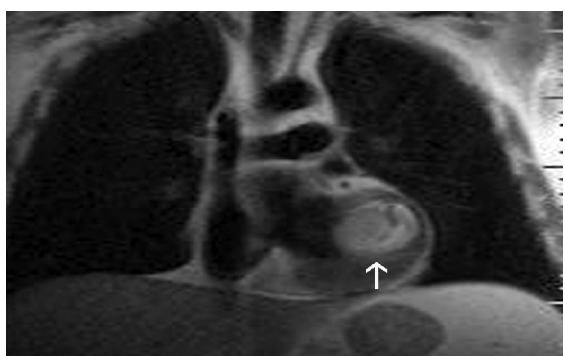


Figure 3. Static image from cardiac MRI examination performed with cine true fast imaging with steady-state precession shows hydatid cyst (arrow) with hypo-intense ring-shaped thick wall at the left ventricle lateral wall in coronal T2 weighted dark-blood MR image.

Additional imaging techniques such as cardiac computed tomography or transesophageal

echocardiography didn't performed due to adequate information obtained from transthoracic echocardiography and cardiac MRI.

Specific blood tests for hydatid cyst were performed. Weinberg complement fixation, indirect hemagglutination and Enzyme-Linked Immunosorbent Assay (ELISA) tests were positive for echinococcosis.

Scanning of brain, abdomen and thorax by computed tomography failed to show any other organ involvement. Coronary angiogram which was performed because of the patient's complaint of angina was normal.

Combination antihelminthic chemotherapy to be followed by surgical excision of the cyst was planned, but the patient refused to undergo cardiac surgery. Hence, the patient was discharged with albendazole and amiodarone treatment. The patient is on the third month of the treatment and, still has no complaint.

Discussion

Cardiac manifestations of hydatid cysts are rare and occur in about 0.5-3% of all cases.¹ The distribution of echinococcosis in the heart depends on the blood supply to that part of the heart. The left ventricle, the part of the heart that has the most abundant blood supply, is involved most frequently (55%–60% of the time).^{2,3} Involvement of the interventricular septum is reported in 5% to 9% of cardiac cases. The right atrium is involved in 3% to 4% of cases, and the right ventricle in 15%. Distribution in the left atrium, pulmonary artery, and pericardium occurs in 8%, 7%, and 8% of cardiac cases, respectively.² Only approximately 10% of patients, especially those with large hydatid cysts have clinical manifestations and symptoms are usually nonspecific. Depending on its size and localization, a cyst may compress adjacent structures and may therefore be responsible for signs of ischemia or mimic valvular lesions or conduction disorders and arrhythmias as we have seen in our patient. When we reviewed the literature, there were only three cases of cardiac cyst hydatid presenting with ventricular tachycardia, all of which were located in the interventricular septum.^{4,5}

Our case of cardiac cyst hydatid was the first to localize in the left ventricular lateral wall and cause ventricular tachycardia. Sudden rupture of intracardiac cysts is a frightful complication and can cause acute pericarditis or tamponade,⁶ acute pulmonary hypertension by embolization of several scolices,^{3,7} systemic arterial embolization, and severe anaphylactic shock. All complications can be life-threatening.⁸

An Unusual Presentation of Cardiac Hydatid Cyst: Ventricular Tachycardia

Echocardiography, CT, and MRI can show the cystic nature of the mass and its relation to the cardiac chambers. Typical appearance of hydatid cyst on transthoracic echocardiography is a fluid-filled mass with a well defined outer wall and initial septation.⁹ CT best shows wall calcification.^{7,10} The appearance of a hydatid cyst on MRI is usually a characteristic oval lesion that is hypo intense on T1-weighted images and hyper intense on T2-weighted images. A typical finding on T2-weighted images is a hypo intense peripheral ring, which represents the pericyst (a dense fibrous capsule from the reactive host tissue).^{3,7,10,11}

A variety of tumors in the heart and a congenital pericardial cyst must be considered in the differential diagnosis; however, well defined outer wall and initial septation on TTE and membrane detachment on cardiac MRI and positive serologic test results led us to diagnosis of cardiac cyst hydatid in our patient. Although serologic tests are widely used for the diagnosis, negative results do not rule out echinococcosis, since cases of single extra hepatic organ involvement may be found without positive test results.

In hydatid infestation of the heart, the accurate treatment is surgical resection of the cyst; however, there are few cases reporting cyst disappearance with albendazole treatment. Since our patient refused to undergo a cardiac surgery, we were obliged to discharge the patient with the combination treatment of albendazole and amiodarone.

Conclusion

In the present case, the patient had ventricular tachycardia which was an unusual presentation of the cardiac cyst hydatid. Since the patient had no other structural abnormality of the heart or coronary artery disease, the mass was assumed to be causing his arrhythmia.

References

1. Miralles A, Bracamonte L, Pavie A, et al. Cardiac echinococcosis. Surgical treatment and results. *J Thorac Cardiovasc Surg* 1994;107:184-190.
2. Perez-Gomez F, Duran H, Tamamer S, Perrote JL, Blanes A. Cardiac echinococcosis: clinical pictures and complications. *Br Heart J* 1973;35:1326-31.
3. Yague D, Lozano MP, Lample C, Nunez ME, Sanchez F. Bilateral hydatid cyst of pulmonary arteries: MR and CT findings. *Eur Radiol* 1998;8:1170-72.
4. Sağkan O, Köşşüş A, Demirağ MK, et al. Paroxysmal ventricular tachycardia due to interventricular hydatid cyst. *Echocardiography* 2002;19:683-5.
5. Sirinelli A, Le Guludec D, Laine JF, et al. Ventricular tachycardia revealing a hydatid cyst. *Am Heart J* 1987;114:656-9.
6. Thameur H, Abdelmoula S, Chenik S, et al. Cardio-pericardial hydatid cysts. *World J Surg* 2001;25:58-67.
7. Alper H, Yünter R, Sener NR. Intramural hydatid cyst of pulmonary arteries: CT and MR findings. *Eur J Radiol* 1995;5:666-8.
8. Ben-Hamda K, Maatouk F, Ben-Farhat M, et al. Eighteen-year experience with echinococcosis of the heart: clinical and echocardiographic features in 14 patients. *Int J Cardiol* 2003; 91:145-51.
9. Oliver JM, Sotillo JF, Dominguez FJ, et al. Two-dimensional echocardiographic features of echinococcus of the heart and great blood vessels: clinical and surgical implications. *Circulation* 1988;78:327-37.
10. Dursun M, Terzibasoglu E, Yilmaz R, et al. Cardiac hydatid disease: CT and MRI findings. *Am J Roentgenol* 2008;190:226-32.
11. Kotoulas GK, Magoufis GL, Gouliamos AD, et al. Evaluation of hydatid disease of the heart with magnetic resonance imaging. *Cardiovasc Intervent Radiol* 1996;19:187-9.

Corresponding author: Necip ERMIS, MD,
Inonu University Medical Faculty,
Department of Cardiology, MALATYA
Tel: 90 422 341 06 60/ 4508
Fax: 90 422 341 07 28
E-Mail: necipermis@yahoo.com