



Comparative Effects of Ovariectomy and Flutamid on Body-Uterus Weight and Uterine Histology in the Ovariectomized Rat Model[†]

Berna Güney Saruhan*, Davut Özbağ***, Nurullah Özdemir**, Yakup Gümüşalan***

* Departments of Histology and Embryology, Veterinary Medicine Faculty, University of Dicle, Diyarbakır, Turkey

** Departments of Anatomy, Medical Faculty, University of Sıtcu İmam, Kahramanmaraş, Turkey

*** Departments of Pharmacology and Toxicology, Veterinary Medicine Faculty, University of Dicle, Diyarbakır, Turkey.

Objective: To determine the effect of flutamide on uterine histology and to ascertain whether flutamide regulates body weight gain in the ovariectomized rat model.

Materials and Methods: We used 36 sexually mature female Wistar-Albino rats in this study. The study was performed in the Department of Medical Science Application and Research Centre of Dicle University, Diyarbakır. We divided the model rats into 3 groups: group 1- control group, group 2- sham-operated group and group 3- bilaterally ovariectomized group. In addition, we gave flutamide to group 3.

Results: We found that the body weight was higher in the ovariectomized rats than the control rats, unlike the decreased uterine net weight. Furthermore, body weight decreased slightly after flutamide therapy, however uterine net weight increased. After flutamide applications, the length of uterine epithelium, the number of uterine glands, infiltration of the stromal cells increased and the lumen of uterine glands were dilated.

Conclusion: As a result, an improvement was observed after flutamide applications while bilateral ovariectomy was determined to cause atrophy in the uterine epithelium of rat. Our study may be source for further research examining the relationship between the androgen receptor antagonist flutamide and reproductive function in female rats.

Key Words: Flutamide, Anti-androgen, Ovariectomy, Uterine histology, Body weight

Ovarektomize Ratlarda Flutamid Uygulamasının Vücut Ağırlığı ve Uterus Histolojisi Üzerine Etkilerinin Karşılaştırılması

Amaç: Ovarektomize ratlarda Flutamid kullanımının vücut ağırlığı ve uterus dokusu üzerine etkilerinin araştırılması. **Materyal ve Metod:** 36 adet Wistar Albino türü dişi sıçanlar Dicle üniversitesi DÜSAM merkezinden seçildi. Sıçanlar 3 guruba ayrıldı. Grup 1 - kontrol grubu, grup 2 - sham-operasyon, grup 3-bilateral ovarektomi ve flutamid verilen grup.

Bulgular: Çalışmada ovarektomize ratların vücut ağırlığı kontrol ratlardan daha fazla bulunurken, uterus ağırlığının azaldığı gözlemlenmiştir. Bununla birlikte flutamid kullanımı sonrasında vücut ağırlığı çok önemli olmamakla beraber azalırken uterus ağırlığı artmıştır. Flutamid uygulamasından sonra uterus epitelinin yüksekliği, uterine bezlerin sayısı artarken bezlerin lumenlerinde genişleme gözlemlenmiştir.

Sonuç: Bilateral ovarektomi ratların uterus epitelinde atrofi şekillendirirken flutamid uygulamasının düzeltici etkilerinin olduğu gözlemlenmiştir. Bu çalışmada bir androjen reseptörü olan flutamid ile dişi ratların üreme fonksiyonları arasındaki ilişkinin daha ilerki çalışmalara kaynak oluşturabileceği görülmüştür.

Anahtar Kelimeler: Flutamid, Anti-androjen, Ovarektomi, Uterus histolojisi, Vücut ağırlığı.

[†]This study was presented at the VI International Symposium of Clinical Anatomy Varna, October 2004

In recent years, it has become clear that the concept of androgens are male hormones and estrogens are female hormones is an oversimplification.¹ All of the gonadal steroid hormone receptors, oestrogen receptor alpha, oestrogen receptor beta, progesterone receptor and androgen receptor, are expressed in the uterus.^{2,3}

Androgens are often used in conjunction with estrogens in hormone replacement therapy in order to relieve some of the undesired effects of unopposed estrogens.⁴ Many androgens, including testosterone, are known to elicit uterotrophic effects in rodents.^{5, 6} Several studies suggest that whether these effects are mediated through estrogen or androgen receptors is dependent on the androgen studied, the dose administered and the vehicle used to dissolve the androgen.^{6, 7} Furthermore, several androgens alter the expression of estrogen-regulated uterine genes.⁸ Treatment of rodents with testosterone increases uterine weight^{9, 10} and results in epithelial hyperplasia and apoptosis of endometrial cells.¹¹

Since many steroids are known to have overlapping androgen (A) and progesterone (P) receptor mediated activities, such as the antiandrogen/progestin (Aa/Pr) cyproterone acetate^{12, 13}, we chose to explore the nonsteroidal Aa, flutamide, as a potential source of novel progesterone receptor ligands. Most of the biologic testing was done in vivo in rats, rabbits, and monkeys, using procedures that accorded with contemporary legislative and corporate requirements.¹⁴

Flutamide is a non-steroid blocking the androgen receptor and its administration decreases body weight gain.¹⁵ Female cats underwent ovariectomy (spayed female) and ligation of both uterine tubes without ovary removal. Neutered cats gained significantly more body fat and body weight.¹⁶

In humans and rodents, exposure to hormonally active chemicals during sex differentiation can produce a wide range of abnormal sexual phenotypes including masculinized and defeminized females and feminized and demasculinized males.¹⁷

Flutamide is a non – steroidal antiandrogen which inhibits androgen uptake and/or nuclear binding of androgen in target tissues. The antiandrogen drug flutamide suppresses responses to androgens from both the gonads and the adrenals. Flutamide is orally absorbed almost completely.¹⁸

Flutamide, an anti-androgen known to act through the androgen receptor, abolished the inhibitory action of testosterone on the induction of peroxidase in immature rat uteri without affecting inhibition produced by progesterone¹⁹. Ovariectomy is the surgical removal of one or both ovaries. If one ovary is removed, a woman may continue to menstruate and have children. If both ovaries are removed,

menstruation stops and the woman loses the ability to bear children. Ovariectomized animals are often used to study metabolic and physiological conditions associated with hormonal changes. They are also used for studies in which normal reproduction and reproductive hormone cycles are undesired.²⁰ Therefore, this experiment was launched to compare the effects of flutamide, body and uterine net weight and uterine histology in the ovariectomized rat model.

MATERIALS AND METHODS

Thirty-six, 3 months old Wistar – Albino female rats, weighing approximately 200- 210 g (Department of Medical Science Application and Research Centre of Dicle University, DUSAM) were used in this study. The rats were acclimated to the local vivarium conditions (22°C and 12 h /12h light–dark cycle) for two months. They were singly housed in 34 cm x 47 cm x 17 cm cages during the experimental period. All rats were allowed free access to water and a pelleted commercial diet containing 0.97 % calcium, 0.85% phosphorus, and 1.05 IU /g of Vit D₃. The rats were divided into three groups of 12.

Group 1 (Control group): A control group was established with administration of carrier A [1:3 mixture of 100%ethanol and0.9%salineW/V (Boots CO., Australia)] each day for 3 days. The animals of this group did not receive ovariectomy nor flutamide treatment. Carrier A injection was given in order to create the stress environment as in the two other animal groups.

Surgical ovariectomy was performed to Group 2 and 3 rats.

OVARIECTOMY: In brief, Group 2 and 3 all rats were food-deprived prior to surgery. For the ovariectomies, the rats were anesthetized by intraperitoneal injection of ketamine HCL (50 mg/kg body weight. Parke-Davis) and xylazine 2 % (100 mg/kg body weight. Rompun-Bayer).²⁰ Bilateral ovariectomies were done in 24 animals using a dorsal approach in a sterile surgical theatre. After bilateral ovariectomy the rats were allowed to recover for 6-8 weeks before being treated. Control rats (Group 1) were subjected to a sham operation in which the ovaries were exteriorized but left intact.

Group 2 was designated as sham-operated group. Sham-operated rats were subcutaneously injected with equivalent amount 0.1 ml of a 1:3 mixture of

Comparative Effects of Ovariectomy and Flutamid on Body-Uterus Weight and Uterine Histology in the Ovariectomized Rat Model

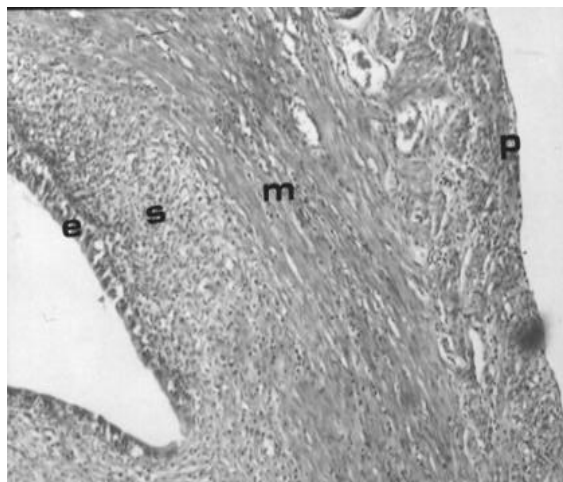
benzyl alcohol and peanut oil, each day for 3 days. Carrier B injection was given in order to create the stress environment as in the two other animal groups.

Animals in Group 3 were given an oral gavage of 10mg /100g Flutamid (Eulexin 250 mg tablet) each day for 3 days.

After approximately two months of ovariectomy, the animals were anaesthetized and killed by cardiac exsanguination. Pelvic region was seen to be far too much fatty at autopsy. The uterus was removed from each rat and immediately weighed. Then the uteri were immersed in 10 % formaldehyde for 24 h at 4°C for fixation. The uterine tissue was processed into paraffin blocks through successive concentration of ethanol and xylene. Five micron sections were cut using a Leica RM 2125 RT and the sections were stained with hematoxylin and eosin, Mallory-Azan and Methylene blue - Alcian blue. The stained sections were later evaluated under light microscopy.

In all experiments, body weights were measured daily using top – loading balance and the person measuring the body weight was blinded to each treatment group. Food intake was determined by estimating the amount of food consumed by the mice throughout the treatment period.

Figure 1. The appearance of uterine epithelium (e), stroma (s) and myometrium (m) was normal in control group. (Haematoxylin-Eosin, X100).



RESULTS

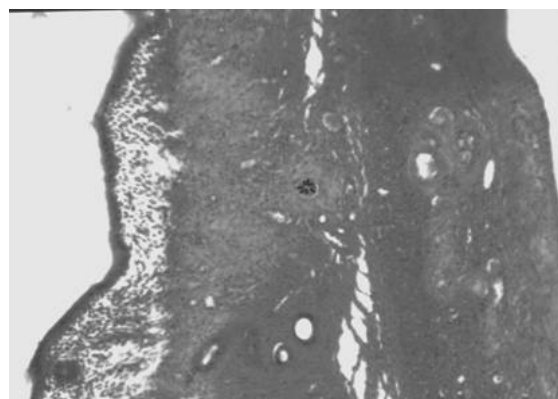
Uterine Histology

In our study, we observed no pathology in the uterine epithelium and stroma of control group. The

appearance of uterine epithelium and stroma was normal. Its covering epithelial cells were a mixture of ciliated and secretory simple columnar cells and the connective tissue of the lamina propria was rich in fibroblasts and contained abundant amorphous ground substance. Connective tissue fibers were mostly reticular (Figure 1).

The length of the epithelium and the number of the uterine glands decreased, moreover the appearance of stromal tissue was more loose in bilaterally ovariectomy group (Group 2 and 3) (Figure 2).

Figure 2. The number of the uterine glands and the uterine epithelium of the sham-operated animals decreased. The appearances of the stromal tissues were more loose in bilateral ovariectomy group. (Haematoxylin –Eosin, X100).



After flutamid applications, the length of the uterine epithelium, the number of the uterine glands, the infiltration of the stromal cells increased and the lumen of the uterine glands were dilatated (Figure 3a). In the flutamid treated groups, the endometrium was emerging as evident evaginations of the luminal epithelium (Figure 3b). Connective tissue fibers were long and folded (Figure 3c). Underneath the endometrium was the myometrium, in which a number of large blood vessels a higher power of the interlacing bundles of smooth muscle cells were illustrated (Figure 3d).

As a result, an improvement was observed after flutamid applications while bilaterally ovariectomy was determined to cause atrophy in the uterine epithelium of rat.

In this study we observed that the antiandrogen drug flutamid is hormonally active and may exhibit antiestrogenic activity in rats.

Figure 3a. After flutamide applications (Group 3), the length of the uterinal epithelium, the number of the uterinal glands and the infiltration of the stromal cells increased and the lumen of uterinal glands were dilatated. (Haematoxylen –Eosin, X200).

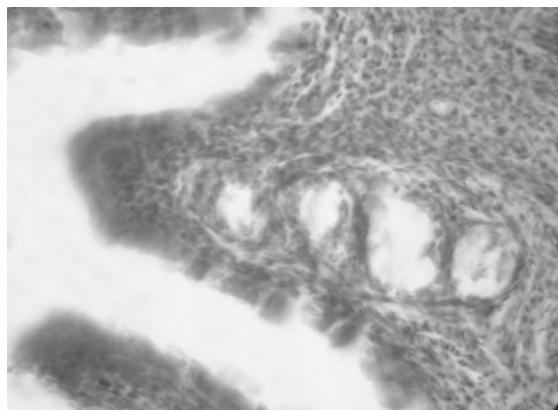
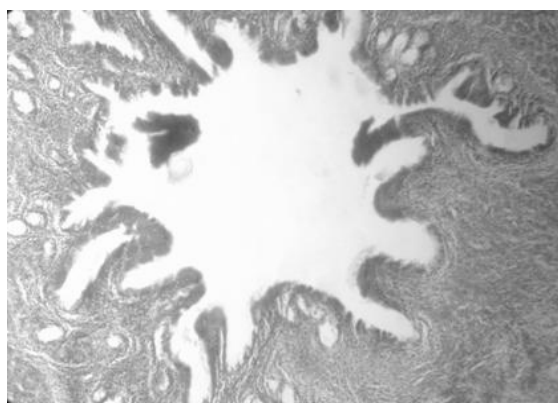


Figure 3b. Group 3 animals showing almost typical evaginations of the luminal epithelium. (Haematoxylin –Eosin, X100).



Statistics

Data are expressed as mean \pm SEM. Statistics were calculated using Minitab. The analysis of variance (ANOVA) test followed by Fisher's was used to compare the differences between groups. ²¹

Body and Uterine Weight

Comparison of the starting means of the control group and other 24 animals at the start of trial was found to be insignificant (Table 1). Comparison of the live weight means of control group with the other animals after the second month (postovariectomy) was found to be significant (Table 2) ($p < 0.05$). According to the Fisher Tukey test, the difference between the last weight means of animal groups having only ovariectomy and then whether receiving the drug or without receiving the drug was found to be insignificant (Table 1). The differences between the weight means of animal groups 1 and 2, and also

groups 1 and 3 were found to be significant following the administration of the drug (Table 1). When paired t-test was run, the administered drug did not cause any difference in the same weight of animals before and after the administration of the drug. The differences between the means of uterine weights were found to be significant for all combinations following Tukey Checking test (Table 1).

Figure 3c. Group 3 animals showing long and folded connective tissue fibers. (Methylene Blue –Alcian Blue, X200).

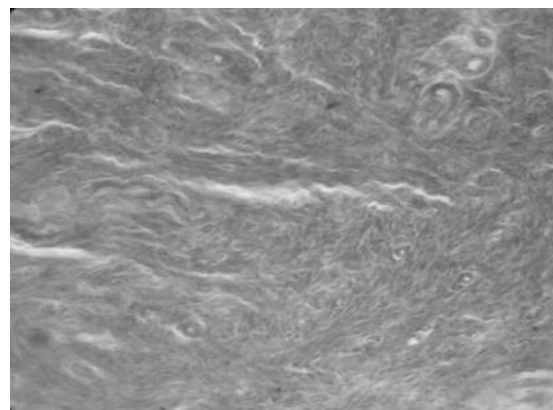
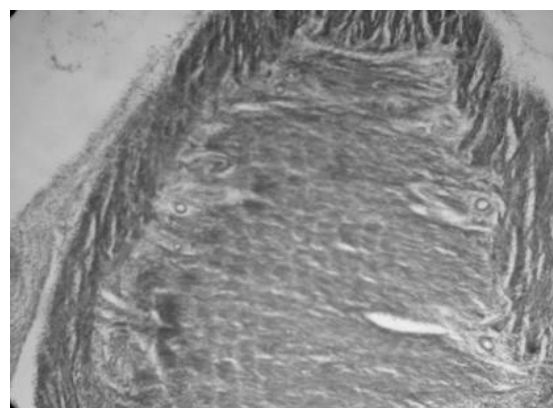


Figure 3d. Uterinal myometrium of Group 3 animals showing thickening. (Haematoxylin – Eosin, X 200).



In this trial, paired t-test was performed in order to elucidate whether the administration of the drug was effective in those animals or not. It was determined that administration of the drug was not effective on body weight. ($p > 0.05$) (-4.83 ± 2.31).

We may conclude that the body weight increased significantly on the contrary to the decrease in uterine weight following ovariectomy. Furthermore, even though no marked change was recorded in body weight due to short term use of the drug flutamide, an increase was observed in the weight of uterus.

Comparative Effects of Ovariectomy and Flutamid on Body-Uterus Weight and Uterine Histology in the Ovariectomized Rat Model

Table 1. Comparison of the weights of body and uterus

	At the start of experiment	After two monts	Following three days of drug administration	Uterus weights
Group 1 (n=12)	204,83±1,1 ^a	222,08±0,70 ^a	222,08±0,7 ^a	1,5835±0,315 ^a
Group 2 (n=12)	203,50±0,96 ^a	284,58±2,71 ^{bd}	284,58±2,71 ^{bd}	1,0810±0,855 ^b
Group 3 (n=12)	205±1,03 ^a	284,58±2,60 ^{cd}	279,75±1,59 ^{cd}	1,9610±0,092 ^c

Table 2: Comparison of the body weight means of the control group with other groups after the second month

	At the start of experiment	After 2 months
Group 1 (n=12)	204,83±1,2 ^a	222,08±0,7 ^a
Group 2 (n=24)	204,33±0,71 ^b	284,58±1,8 ^b

DISCUSSION

Sex hormones have been known for some time to play an important role in maintaining human female genital tract. Thus estrogens and androgens have specific effects on the female genital tract. Exogenous estrogens have teratogenic and carcinogenic effects on the developing female genital tract of both laboratory animals and humans. Certain triphenylethylene compounds, such as clomiphene, tamoxifen, and nafoxidine are hormonally active and may exhibit antiestrogenic activity.²² Tamoxifen is used to treat breast cancer²³. Results demonstrate that the antiandrogen flutamide is also effective in breast cancer therapy.²⁴

The effect of flutamide on estrogen induced rat uterine growth was studied decades ago.^{25, 26} There is much discussion today about whether or not androgens should be included along with estrogen and progesterone in hormone replacement therapy of postmenopausal women. There appears to be beneficial effects of androgens on maintenance of bone, improvement of mood and reversal of sexual dysfunction. The present data suggest that androgens can also stimulate proliferation of the uterine epithelium.²⁷ Flutamide is a β morphological characteristic as well as to recovery of fertility in females with anovulatory infertility.²⁸ Yet, in the other experimental studies pregnant rats were administered flutamide and perinatal exposure to flutamide caused decreased weights of androgen dependent organs. In another study, no effect of flutamide administration was observed regarding sex hormone levels. However, flutamide given to rats caused abnormalities of androgen dependent organs in male offspring.²⁹

In animal models, exogenous hormones have been shown to perturb uterine gland formation.³⁰ It has

been demonstrated that administration of either estradiol-17 β or tamoxifen and flutamide to neonatal rats inhibits uterine gland formation.³¹

Clark and Mc Cormack reported that a single injection of clomiphene and tamoxifen to ovariectomized rats elicited an evident increase in the length of luminal epithelium.³²

In our study, we observed that in bilaterally ovariectomized groups the length of epithelium and the numbers of uterine glands were decreased and following oral application of flutamide the number of uterine glands increased and dilatated. Since estrogens and androgens have specific effects on the female genital tract,³³ it has been recently shown that flutamide administered to female rats resulted in an increase on the weight of uterus.³⁴ In the current study, we observed that the antiandrogen drug flutamide was hormonally active when administered to female rats exhibited antiestrogenic activity and increased the weight of uterus. Recent research has reported that the body weight was higher in the ovariectomized rats than the intact rats.³⁵ In another experimental study, ovariectomy increased the body weight.³⁶ Data from all groups presented that uterine weights decreased in the ovariectomized rats. Another experimental study has reported that flutamide also antagonized the ovariectomized rats induced increase in body weight. However, unlike 17 β estradiol, flutamide at efficacious doses did not prevent the ovariectomized rats induced loss in uterine wet weight.³⁷

The results from this experiment indicate that body weight gains in ovariectomized rats were significantly greater than in control rats two months postsurgery. Unlikely, qualitative evaluation of ovariectomized sham-operated group demonstrated that their uteri were significantly smaller than those in control group. However, uterine weight in ovariectomized rats treated with 10 mg/100g flutamide was significantly higher than that of sham-operated groups. However, ovariectomized rats treated with flutamide at 10mg/100g maintained no significant difference in ovariectomized sham-operated. This effect was dose dependent and short period application.

In our previous studies, we had seen that antiestrogens exhibited estrogen like effects.^{38, 39} Therefore, in this study, we wanted to demonstrate that flutamide brought about the effects similar to estrogens and antiestrogens.

REFERENCES

- Smith EP, Boyd J, Frank GR, Takahashi H. Estrogen resistance caused by a mutation in the estrogen receptor gene in a man. *N Engl J Med* 1994; 331:1088-89.
- Pelletier G, Labric C, Labric F. Localization of oestrogen receptor alpha, oestrogen receptor beta and androgen receptors in the rat reproductive organs. *J Endocrinol* 2000; 165: 359-70.
- Weihua Z, Saji S, Makinen S, Cheng G. Estrogen receptor beta, a modulator of ER alpha in the uterus. *Proc Natl Acad* 2000; 97: 5936-41.
- Barrett Connor R, Young R, Notelovitz M, Sullivan J. A two-year double-blind comparison of estrogen-androgen and conjugated estrogens in surgically menopausal women. *J Reprod Med* 1999; 44:1012-20.
- Beri R, Kumar N, Savage T, Benalcazar L, Sundaram K. Estrogenic and progestational activity of 7 α -methyl-19-nortestosterone, a synthetic androgen. *J Steroid Biochem Mol Biol* 1998; 67: 275-83.
- Sahlin L, Norstedt G, Eriksson H. Androgen regulation of the insulin-like growth factor, and the estrogen receptor in rat uterus and liver. *J Steroid Biochem Mol Biol* 1994; 51: 57-66.
- Giannopoulos G. Binding of testosterone to cytoplasmic components of the immature rat uterus. *Biochem Biophys Res Commun* 1971; 44: 943-51.
- Sahlin L, Wang H, Masironi B, Holmgren A, Eriksson H. Regulation of thioredoxin mRNA in the rat uterus by gonadal steroids. *J Steroid Biochem Mol Biol* 1999; 68: 203-09.
- Jones RC, Edgren RA. The effects of various steroids on the vaginal histology in the rat. *Fertil Steril* 1973; 24: 284-91.
- Okazaki K, Imazawa T, Nakamura H, Furukawa F, Nishikawa A. A repeated 28 day oral dose toxicity study of 17 α -methyltestosterone in rats, based on the 'Enhanced OECD Test Guideline 407' for screening the endocrine-disrupting chemicals. *Arch Toxicol* 2002; 75: 635-42.
- Espuna G, Chuzel F, Esch GP, Pallen C, Bars R. Detection of endocrine effects, an enhanced OECD Test Guideline 407, Study with methyltestosterone. *Toxicol Sci* 2002; 66:276.
- Neumann F, Graf KJ, Hasan SH. Central actions of antiandrogens. In: L. Martini and M Motta (eds). *Androgens and antiandrogens*, Raven press, Newyork. 1977; 163-77.
- Neri R.O. Studies on the biology and mechanism of action of nonsteroidal antiandrogens. In: L. Martini and M Motta (eds). *Androgens and antiandrogens*, Raven press, Newyork. 1977; 179-88.
- Dukes M, Furr JA, Hughes LR. Nonsteroidal progestins and antiprogestins related to flutamide. *Steroids* 2000; 65: 725-31.
- Pazo S.F., Sanchez F.F., Balsa J.A. Mechanisms of reduced body growth in the pubertal feminized male rat. *Pediatr Res* 2000; 48: 96-103.
- Nguyen P.G., Duman H.J., Siliart B.S. Effects of dietary fat and energy on body weight and composition after gonadectomy in cats. *Am J Vet Res* 2004; 65: 1708-13.
- Gray LE., Ostby JS. Developmental effects of an environmental antiandrogen: the fungicide vinclozolin alters sex differentiation of the male rat. *Toxicol Appl Pharmacol* 1994; 129:46-52.
- Haskell CM. *Cancer treatment*, 3 rd ed. Philadelphia: WB Saunders Co. 1990; 96.
- Jellinek PH., Newcombe A.M. Androgen receptor-mediated inhibition of oestrogen-induced uterine peroxidase. *J Steroid Biochem* 1983; 19:1713-17.
- Karnam RP, Pao LW, Calogero D. Effects of surgical ovariectomy on rat salivary gland function. *Archs oral Biol* 1993; 38: 779-84.
- Neter J, Wasserman W, Ahitmore GA. *Applied Statistics*. Boston: Allyn and Bacon 1982; 544-72.
- Taguchi O, Cunha GR, Robboy SJ. Experimental study of the effect of diethylstilbestrol on the development of the human female reproductive tract. *Biol Res Pregnancy* 1983; 4: 56.
- Fisher B, Redmond B, Brown A. Adjuvant chemotherapy with and without tamoxifen in the treatment of primary breast cancer: 5-year results from the National Surgical Adjuvant Breast and Bowel Project Trial. *J Clin Oncol* 1986; 4: 459.
- Dukes M, Furr JA, Hughes LR. Nonsteroidal progestins and antiprogestins related to flutamide. *Steroids* 2000; 65 :725-31.
- Schmidt WN, Katzenellen BS. Androgen-uterine interactions: an assessment of androgen interaction with the testosterone and estrogen receptor systems and stimulation of uterine growth and progesterone receptor synthesis. *Moll Cell Endocrinol* 1979; 15: 91-108.
- Chandrasekhar Y, Armstrong DT. Regulation of uterine progesterone receptors by the nonsteroidal antiandrogen hydroxyflutamide. *Biol Reprod* 1991; 45: 78-81.
- Basson R. Female sexual response the role of drugs in the management of sexual dysfunction. *Obstet Gynecol* 2001; 98:350-53.
- Reznikov AG, Sinityn PV, Tarasenko LV. Neuroendocrine mechanisms of development of experimental hyperandrogen induced anovulation. *Neurosci Behav Physiol* 2003; 33: 773-6.
- Kaori M, Setsuko Y, Masashi S. Effects of perinatal exposure to flutamide on sex hormone responsiveness in F1 male rats. *The Journal of Toxicological Sciences* 2003; 3:149-63.
- Branham SW, Sheehan DM, Zehr DR. Inhibition of rat uterine gland genesis by tamoxifen. *Endocrinol* 1985; 117: 2238.
- Branham SW, Sheehan DM, Zehr DR. The postnatal ontogeny of rat uterine glands and age related effects of 17 β estradiol. *Endocrinol* 1985; 117: 2229.
- Kent J. Development of the infantile mouse uterus: the effect of stilbestrol. *J Reprod Fertil* 1975; 43:367.
- Clark JH, Mc Cormack SA, Kling R. Effect of clomiphene and other triphenylethylene derivatives on the reproductive tract in the rat and baboon. In: Iacobelli S. *Hormones and Cancer* 1980; 295.
- Park SM, Park CH, Wha JD. A high carbohydrate diet induces insulin resistance through decreased glucose utilization in ovariectomized rats. *Korean J Intern Med* 2004; 19: 87-92.
- Blaustein JD, Gentry RT, Roy EJ. Effects of ovariectomy and estradiol on body weight and food intake in gold thioglucose treated mice. *Physiol Behav* 1976; 17: 1027-30.
- Retra RN, Wenddy NJ, Joseph H. Developmental exposure to DES alters uterine response to estrogens in prepubescent mice: low versus high dose effects. *Reprod Toxicol* 2004; 18: 399-06.
- Sutherland MK, Brady H, Gayo LM. Effects of SP 500263, a novel selective estrogen receptor modulator on bone, uterus and serum cholesterol in the ovariectomized rat. *Calcif Tissue Int* 2003; 72: 710-16.
- Saruhan BG., Nergiz Y. Histological Effect of Estrogens and Anti-estrogens on uterine epithelium in estrogen deficiency induced rats. *Journal of Dicle Medicine* 2002; 29: 1-2.
- Saruhan BG., Nergiz Y. Histological Effect of Estrogens and Anti-estrogens on vaginal epithelium in estrogen deficiency induced rats. *The Chamber of Medicine of Istanbul, Journal of Clinical Development* 2003; 16: 1-5.

Corresponding Author

Dr. BernaGüney SARUHAN
 Departments of Histology and Embryology,
 Veterinary Medicine Faculty, University of Dicle, Diyarbakir
 Tel : +90 412 248 8020-8627
 Tel : +90 537-798 8616
 E-Mail : bsaruhan@dicle.edu.tr