



## Bougie Dilatation of Esophageal Stricture Induced by Fehling's Solution in A Pregnant Patient (Case Report)<sup>+</sup>

Ahmet Tüzün\*, Sait Bağcı\*, Yüksel Ateş\*, Ahmet Uygun\*, Ahmet Erdil\*, Necmettin Karaeren\*,  
Kemal Dağalp\*

Gülhane Medical Academy and Faculty, Department of Gastroenterology, Ankara, Turkey

Herein we report a case that is a 32-year-old pregnant woman with esophageal and pyloric stricture caused by the accidental ingestion of Fehling's solution. Numerous bougie dilatations were applied for the severe esophageal stricture in our patient both pre and post-delivery period. Monthly controls are going on for the case and 13 mm Savary-Gilliard bougie can be passed through easily at present. Meanwhile, she underwent pyloroplasty operation at the post-delivery period since two attempts of pyloric balloon dilatation procedure have failed. Finally, dilatation with Savary-Gilliard bougies is a quite effective method, which can be also used in pregnant patients.

**Key Words:** Pregnancy, Stricture, Esophagus

### Gebe Bir Hastada Fehling Solüsyonuna Bağlı Gelişen Özofageal Darlığın Buji Dilatasyonu ile Tedavisi (Olgu Sunumu)

Bu makalede, yanlışlıkla Fehling solüsyonu içilmesine bağlı özofageal ve pilorik darlık gelişen 32 haftalık gebe olan bir hasta sunulmuştur. Hastamıza ciddi özofageal darlığı nedeniyle gerek doğum öncesi, gerekse doğum sonrası dönemde buji dilatasyonları uygulandı. Halen 13 mm.lik Savary-Gilliard buji ile rahatça geçiş sağlanan vakamızda, aylık kontrolleri devam etmektedir. Bu arada hastamıza 2 kez uygulanan pilorik balon dilatasyonunun başarılı olmaması nedeniyle doğum sonrası dönemde piloroplasti operasyonu uygulandı. Sonuç olarak, Savary-Gilliard bujilerle dilatasyon gebelerde de kullanılabilen oldukça etkili bir yöntemdir.

**Anahtar Kelimeler:** Gebelik, Darlık, Özofagus

<sup>+</sup>20. Ulusal Gastroenteroloji Haftasında poster olarak sunulmuştur.

Caustic ingestion can produce a progressive and devastating injury to the esophagus and stomach. If the patient survives the acute effects, the reparative response can result in esophageal and/or gastric stenosis and an increased incidence of esophageal cancer. Management of these conditions is quite complicated. The therapy may become more difficult if the problems occur in pregnancy period.

Esophageal dilatation is an important therapeutic modality for the patient with a narrowed esophageal lumen caused by either a benign or malignant process. A wide variety of dilators are currently available, and numerous reports about the safety and effectiveness of dilatation have been published.<sup>1-5</sup> Surgical treatment is advised if dilatation fails or the patient has an unacceptably high number of recurrences. The reports related to esophageal dilatation in pregnancy in the literature are usually concerning achalasia.<sup>6-8</sup> In most of these articles it has been stated that pneumatic dilatation is effective in cases presenting with symptoms and there is no reason to consider termination of pregnancy.<sup>7,8</sup>

In this article, we report dilatation applications with Savary-Gilliard bougies in a pregnant woman with severe esophageal stricture.

## CASE REPORT

A 32-year-old and 30 weeks pregnant woman who is referred to our hospital with diagnosis of esophageal and pyloric stricture due to ingestion of caustic material. She drank a full mouth of Fehling's solution (an aqueous solution of copper sulfate, sodium hydroxide, and potassium sodium tartrate used to test for the presence of sugars and aldehydes in a substance, such as urine) by mistake during the oral glucose tolerance test in the second of April 2002. Steroid and proton pump inhibitor was given before patient was admitted to our center. There were complaints of vomiting and difficulty in swallowing. Circumferential stricture at the 25th cm from the incisuras and extensive ulcers in the proximal part of the esophagus were observed in endoscopic examination at the following day. Stricture diameter was less than 7 mm. Abundant amount of dark colored gastric content was observed, suggesting gastric outlet obstruction. In her initial laboratory investigations revealed; hemoglobin 8.9 g/dl (normal, 12-17.5), glucose 128 mg/dl (normal, 65-107), aspartate aminotransferase 48 U/L (normal, 8-40), alanine aminotransferase 101 U/L (normal, 5-40), total protein 5.5 g/dl (normal, 5.5-7.5), albumin 2.5 g/dl (normal, 3.5-5.5), ferritin 2.6 ng/ml (normal, 22-322), calcium 7.7 mg/dl (normal, 8.5-10.5), magnesium 1.4 mg/dl (normal, 1.9-2.5), and HbsAg were positive. Other test results were normal.

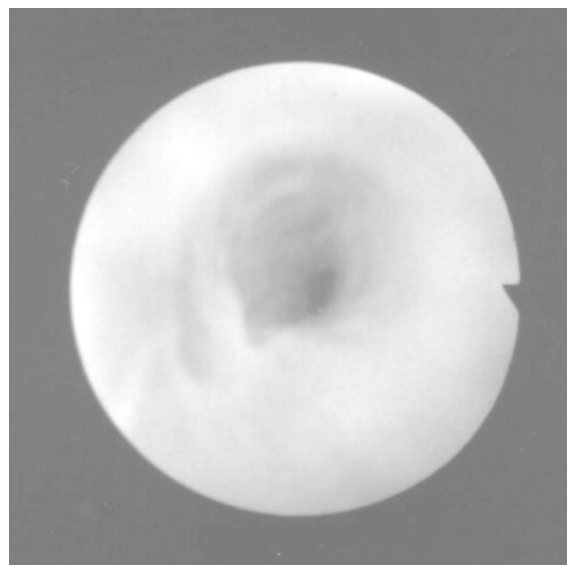
Total parenteral nutrition and H<sub>2</sub> receptor antagonist were started initially. Sucralfate was added after decrease of vomiting by following days.

Five times of esophageal dilatations totally (with Savary-Gilliard dilators from 7 to 11 mm in diameter) were applied until the date (6th October 2002) she gave birth. We couldn't evaluate optimally the stomach in the sessions that we could pass into the stomach because of excessive secretion and undigested foods. Manifested submucosal veins, fibrotic folds lying through the pylorus, evident hyperemia and edema in the prepyloric area and pyloric stenosis were observed in the endoscopic examination. Pyloric balloon dilatation was performed in the same session. The patient was referred to the Obstetric Clinics for delivery after the second pyloric dilatation procedure.

Dilatations were also continued in the postpartum period. Esophageal dilatation (with Savary-Gilliard dilators from 9 to 13 mm in diameter) was performed four times and pyloric dilatation was performed once.

The existence of pyloric stenosis was observed again in the endoscopic control during her follow-up. That is why she underwent Heineke-Mikulicz pyloroplasty operation in 9th of September 2002. The esophagus of the patient in the postoperative period is shown in figure 1. Esophagogram taken before the dilatation procedure in April 2003, is shown in figure 2.

**Figure 1.** The appearance of esophagus in the postoperative period is seen in endoscopic examination.

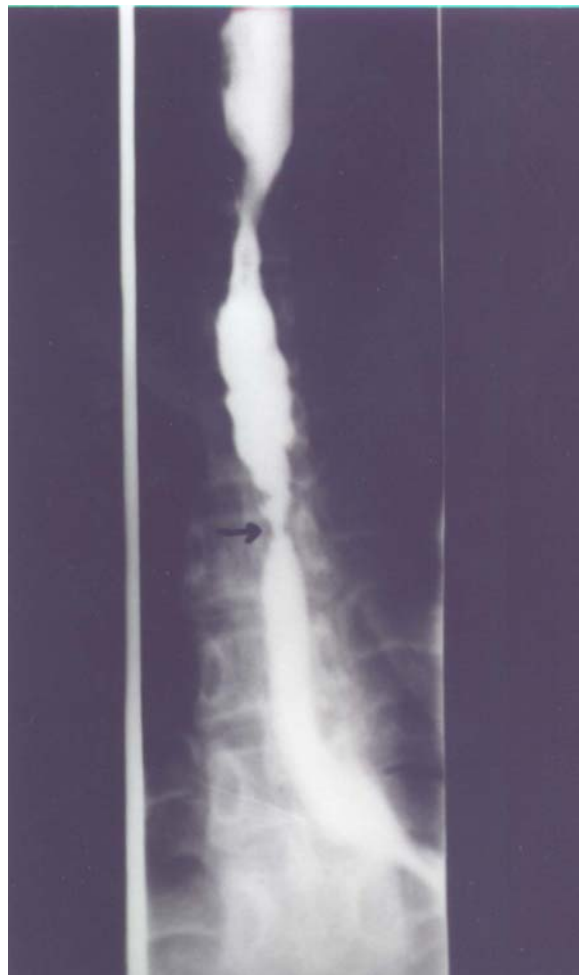

Currently monthly esophageal dilatations are being performed the patient and bougie of 13 mm in diameter can be passed easily throughout the narrowing. No complication related to the dilatation procedure was observed. Nutrition of the patient has improved.

## DISCUSSION

In corrosive esophagitis, varying degrees of chemical burns involving different layers of the esophagus may occur depending on the type, concentration, and volume of the ingested substance. Superficial mucosal (first degree) injury, transmural mucosal injury with possible muscularis involvement (second-degree) injury, or full-thickness (third-degree) injury may result. The condition may extend into periesophageal or perigastric tissues, resulting in perforation, peritonitis, or mediastinitis. Alkalis may cause a deep liquefaction necrosis with fat and protein digestion, while acids typically lead to a more superficial coagulation necrosis with eschar formation.

**Figure 2.** Barium study of the esophagus demonstrating stricture at the 25<sup>th</sup> and 30<sup>th</sup> cm of the esophagus.



Our patient had drunk on alkaline fluid the Fehling's solution. Defining the stricture and excessive esophageal ulcers in spite of admittance after 27 days of exposition to caustic material shows how serious effects alkaline solutions can lead to. Although alkaline solutions cause injury mostly in esophagus because of its neutralization with gastric acid, development of pyloric stenosis in the patient reveals the gastric influences as well.

There are several reports related to balloon or bougie dilatation for benign esophageal strictures in the literature. Some of them are about the treatment of achalasia.<sup>5-11</sup> It has been showed that regarding the safety and clinical utility in pregnant patients. EGD did not induce labor or result in congenital malformation and is not absolutely contraindicated during pregnancy.<sup>12,13</sup> Likewise, it has been reported

that balloon dilatation has been applied successfully in a case of achalasia defined in pregnancy.<sup>8</sup> Mayberry and Atkinson concluded that pregnant patients with achalasia can be treated with endoscopic dilatation in the best way and there is no need to terminate pregnancy.<sup>7</sup>

Despite these data, maternity of 30 weeks, ingestion of an alkaline material, continuous vomiting and intolerance to oral nutrition, made it difficult to decide the choice of treatment in our case. First of all, a gastroduodenogram was considered. As radio contrast material could remain in stomach, we decided to perform esophageal dilatation with Savary-Gilliard bougies in spite of its risks. In this way we would better evaluate the status of stomach and pylorus. This procedure resulted in a passage providing the application of videoendoscope 9.8 mm in diameter and we could perform balloon dilatation of stenotic pylorus leading to enteral nutrition.

Esophageal dilatation by endoscopists is a commonly performed procedure. The introduction of tapered polyvinyl dilators by Savary has made the procedure even more popular and the morbidity and mortality rates with all dilators were reported as 0.1% and 0.05%, respectively.<sup>14</sup> The author believes that fluoroscopy should be used with guide wire dilatation. We didn't use fluoroscopy particularly during the pregnancy period an also in the postpartum period although we used guide wire during the esophageal dilatation.

Our goal on dilatation was to achieve an esophageal lumen of 15 mm in diameter or to make the patient asymptomatic.

In conclusion, dilatation with bougie that can also be used in pregnant patients is a quite effective and relatively safe treatment modality.

## REFERENCES

1. Lanza FL, Graham DY. Bougienage is effective therapy for most benign esophageal strictures. *JAMA* 1978;240:844-47.
2. Taub S, Rodan BA, Bean WJ, Koerner RS, Mullin DM, Feng TS. Balloon dilatation of esophageal strictures. *Am J Gastroenterol* 1986;81:14-8.
3. Westorp IC, Bartelsman JF, den Hartog Jager FC, Huibregtse K, Tytgat GN. Results of conservative treatment of benign esophageal strictures: a follow-up study in 100 patients. *Gastroenterology* 1982;82:487-93.
4. Luna LL. Endoscopic therapy of benign esophageal stricture. *Endoscopy* 1983;15 suppl 1:203-6.
5. Patterson DJ, Graham DY, Smith JL, Schwartz JT, Alpert E, Lanza FL, et al. Natural history of benign esophageal stricture treated by dilatation. *Gastroenterology* 1983;85:346-50.
6. Aggarwal R, Shahi HM, Misra A. Esophageal achalasia presenting during pregnancy. *Indian J Gastroenterol* 1997;16:72-3.
7. Mayberry JF, Atkinson M. Achalasia and pregnancy. *Br J Obstet Gynaecol* 1987;94:855-59.
8. Fiest TC, Foong A, Chokhavatia S. Successful balloon dilatation of achalasia during pregnancy. *Gastrointest Endosc* 1993;39:810-12.

9. Yamamoto H, Hughes RW Jr, Schroeder KW, Viggiano TR, DiMagno EP. Treatment of benign esophageal stricture by Eder-Puestow or balloon dilators: a comparison between randomized and prospective nonrandomized trials. *Mayo Clin Proc* 1992;67:228-36.
10. Cox JG, Winter RK, Maslin SC, Jones R, Buckton GK, Hoare RC, et al. Balloon or bougie for dilatation of benign oesophageal stricture? An interim report of a randomised controlled trial. *Gut* 1988;29:1741-47.
11. Tytgat GN. Dilation therapy of benign esophageal stenoses. *World J Surg* 1989;13:142-48.
12. Cappell MS, Sidhom O. A multicenter, multiyear study of the safety and clinical utility of esophagogastroduodenoscopy in 20 consecutive pregnant females with follow-up of fetal outcome. *Am J Gastroenterol* 1993;88:1900-5.
13. Cappell MS, Colon VJ, Sidhom OA. A study of eight medical centers of the safety and clinical efficacy of esophagogastroduodenoscopy in 83 pregnant females with follow-up of fetal outcome with comparison to control groups. *Am J Gastroenterol* 1996;91:348-54.
14. Webb WA. Esophageal dilation: personal experience with current instruments and techniques. *Am J Gastroenterol* 1988;83:471-75.

**Address for correspondence:**

Ahmet Tüzün, M.D., Assistant Prof.  
Gülhane Medical Academy and Faculty  
Department of Gastroenterology  
06018 Etilik, Ankara, Turkey  
Phone : 90 312 304 4044  
Mobile : 90 532 554 7446  
Fax : 90 312 321 6066  
E-mail : ahmettuzun@yahoo.com