



Effects of Alcohol and Passive Cigarette Smoking on the Swiss Albino Mice Testes⁺

Semra Erpek*, Muharrem Balkaya**, Hümeysra Ünsal**, Cengiz Ünsal**

* Adnan Menderes Üniversitesi Tıp Fakültesi Histoloji-Embriyoloji AD, Aydın

** Adnan Menderes Üniversitesi Veterinerlik Fakültesi Fizyoloji AD, Aydın

Aim: The aim of this study, was to investigate the effects of alcohol, passive smoking and alcohol+passive smoking on the testicular morphology of the adult Swiss albino mice.

Method: 32 male Swiss albino mice were used in this study. The animals were divided randomly in to four groups ($n_1=...n_4=8$): one group served as the control group, and the others were subjected to either alcohol, passive smoking or alcohol + passive smoking for 6 weeks.

Results: No differences were found in absolute or relative testis weights among the different groups. The mean seminiferous tubule diameter was gradually decreased in passive smoking, alcohol and alcohol + passive smoking groups when compared with control group. We found a statistically significant difference between control and alcohol + passive smoking groups ($p=0,006$), alcohol and passive smoking groups ($p=0,005$), and passive smoking and alcohol + passive smoking groups ($p=0,004$). Seminiferous tubules containing degenerated germinal epithelium and decrease in number of Leydig cells were observed in a few tubules of testes from passive smoking and alcohol groups. Degenerative changes were more severe in the group exposed to both alcohol and cigarette smoke.

Conclusion: In the present study, it was observed that alcohol, passive smoking and alcohol + passive smoking caused injury in testis tissue of Swiss albino mice and that these changes were more severe in alcohol + passive smoking group.

Key Words: Swiss Albino Mice , Testis, Alcohol, Passive Smoking.

Swiss Albino Farelerde Alkol ve Sigaranın Testis Dokusu Üzerine Etkileri

Amaç: Sunulan araştırma, erişkin erkek Swiss albino farelerde uzun süreli alkol, pasif sigara, alkol+pasif sigara kombinasyonunun testis dokusuna etkilerini ortaya koymak amacıyla yapılmıştır.

Gereç ve Yöntem: Çalışmada 32 adet erişkin erkek Swiss albino fare kullanıldı. Fareler dört eşit gruba ayrıldı ($n_1=...n_4=8$). Kontrol grubuna herhangi bir işlem uygulanmazken deney gruplarındaki hayvanlar altı hafta boyunca alkol, pasif sigara ve alkol+pasif sigaraya maruz bırakıldı.

Bulgular: Gruplar arasında total veya nisbi testis ağırlıklarında fark gözlenmedi. Ortalama seminifer tübül çaplarının kontrol grubu ile karşılaştırıldığında pasif sigara, alkol ve alkol+pasif sigara gruplarında giderek azaldığı görüldü. Bu azalma kontrol ile alkol grupları arasında ($p=0,02$); kontrol ile alkol+pasif sigara grupları arasında ($p=0,006$); alkol ile pasif sigara grupları arasında ($p=0,005$); pasif sigara ile alkol+pasif sigara grupları arasında ($p=0,004$) istatistiksel olarak anlamlı bulundu. Kesitler mikroskopik olarak incelendiğinde pasif sigara ve alkol grubundaki bazı kesitlerde seminifer tübül epitelinde yer yer dejenerasyon ve Leydig hücrelerinde artma gözlemlendi. Alkol+pasif sigara grubunda seminifer tübül duvarındaki dejeneratif değişikliklerin daha fazla olduğu gözlemlendi.

Sonuç: Sunulan çalışmada alkol, pasif sigara ve alkol+pasif sigara uygulamasının farelerin testis dokusunda hasara neden olduğu ve alkol+pasif sigara uygulaması yapılan grupta bu değişikliklerin daha belirgin olduğu tespit edildi.

Anahtar Kelimeler: Swiss Albino Fare, Alkol, Sigara, Testis

⁺Bu çalışma, Adnan Menderes Üniversitesi Araştırma Fonu tarafından desteklenmiş olup, VI. Ulusal Histoloji ve Embriyoloji Kongresinde (12-15 Eylül 2002) poster olarak sunulmuştur.

Spermatogenesis, a complex sequential process,¹ can be disrupted by many external factors. Two of these possible factors are cigarette smoking and alcohol.

Cigarette smoke contains more than 3000 different chemical substances.² Inhalation of cigarette smoke, whether through active or passive smoking, leads to absorption of these substances through the pulmonary vasculature and blood-borne circulation throughout the body.³ The presence of the major metabolites of cigarette smoke, such as nicotine, cotinine and cadmium, have been detected in the semen of smokers. This finding suggests that cigarette smoke constituents and/or DNA-reactive intermediates pass through the blood-testis barrier and react directly with germ cells.⁴

Conflicting data exist in published reports on the adverse effect of cigarette smoking on male fertility. Although some studies have reported that cigarette smoking is associated with lower semen quality,⁵ others found no relationship between smoking and sperm characteristics.⁶

The adverse effects of chronic ethanol exposure on testicular injury have previously been studied in animals and humans.⁷⁻¹⁴ Ethanol metabolism produces an oxidative stress within the testes, documented by an enhancement of testicular malonaldehyde and a reduction in testicular glutathione levels.¹⁵ Farghali et al.¹⁶ have reported that short-term ethanol feeding produces a disruption of the blood-testes barrier.

Alcohol and cigarette consumption is a pervasive personal habit that is highly addictive, with strong appeal among teenagers and young adults worldwide, especially in developing countries.² Approximately 30% of women and 36% of men of reproductive age in the US are smokers.³ It is important to consider cigarette smoking as part of a lifestyle that may include increased consumption of alcohol. There is evidence that alcohol and cigarette smoking have independent or interdependent effects; although the effects of both agents alone on the reproductive system have been studied, their effects in combination have not previously been clarified in detail. The aim of the present study was to assess whether ethanol and cigarette smoke may have synergistic effects on testicular morphology.

METHODS

Animals

32 male Swiss albino mice were obtained from Experimental Animal Research Center, Adnan Menderes University (Aydın, Turkey). At the beginning of the experiment the animals were

approximately 10 weeks old and their mean body weight was 23-31 g. Animals were housed in an institutional facility with environmental conditions of 23±3 °C, and 14/10 hr light/dark cycle in polypropylene cages with four animals per cage. Standard chow diet for mice (*Best Yem, Gebze*), and tap water were given *ad libitum*.

Experimental design

Animals were divided randomly in four groups each consisting of 8 mice: one group remained untreated, while others were subjected either to alcohol, passive smoking or both. All animals were untreated during the adaptation period of two weeks followed by six weeks of treatment. To avoid anorexia and weight loss that results from abrupt introduction of high alcohol doses, the ethanol concentration in drinking water was increased gradually: alcohol/water (v/v) was 10% during the first week, 20% during the second week and 30% during the following four weeks. All animals in the smoke exposed groups were kept in the cabinet within polyethylene cages, while others were placed outside of the smoke chamber in the same experimental room. The mice were exposed to cigarette smoke for a 2-hour period per day. The passive smoking of mice was established in a specially designed, 0.9 m³ smoke chamber, which had two 20 cm-diameter holes on opposing sides for ventilation. To one of holes a burning oven was connected while the other hole was connected to a hose equipped with a speed-controlled ventilator to release the air from the chamber directly to the outside of the room. A total of 4, 8 or 12-lit cigarettes per cage were used daily for the first, second and following four weeks, respectively. Control animals were exposed only to ambient air. Short Samsun cigarettes were used. Both the ethanol and cigarettes were products of Tekel® and obtained from a commercial source. All animals were kept on a standard diet and were allowed to drink freely. The water intake per cage and the body weights of all animals were recorded weekly after a food withdrawal period of ca 14 hours.

Light microscopy

At the end of the 6th week, the animals were weighed, then a ventral midline incision was made under ether anesthesia. Testes were removed and weighed. The tissues were fixed in Bouin's solution, dehydrated and embedded in paraffin, sectioned at 5 µm and stained with hematoxylin and eosin. The sections were examined and photographed with an Olimpos BX50 photomicroscope.

Morphometric Analysis

Measurement of the diameter of seminiferous tubules was performed with a light microscope equipped with an ocular micrometer at a magnification of 20X. In each section, ten randomly chosen circular cross sections of seminiferous tubules were measured, and average diameter was calculated.

Statistical analysis

Body weights, testis weights, the ratio of testis weights to body weights, and the diameter of seminiferous tubules were compared among the groups using Kruskal-Wallis one-way analysis of variance. Differences were considered significant at the 0.008 level of confidence.¹⁷

RESULTS

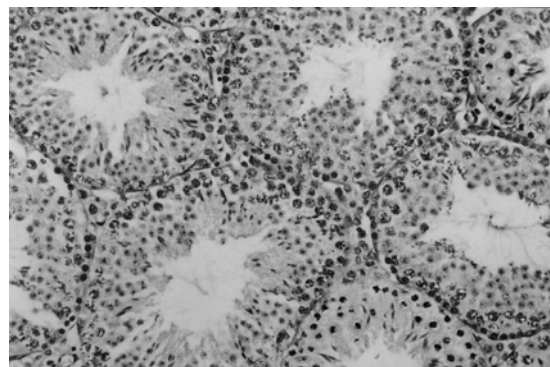
At the beginning of the experiment, the mean body weights of animals in different groups were similar. After 6 weeks, there were still no significant differences among the groups (Table 1). To assess the impact of ethanol and/or cigarette on testis weight, both the absolute and relative testis weights (testis weight adjusted for body weight) were calculated and compared between the different groups. No differences were found.

The diameter of the seminiferous tubule was measured to determine possible effects caused by alcohol and cigarette smoke in testis. The mean seminiferous tubule diameters of experimental groups (passive smoking, alcohol and alcohol plus passive smoking groups) were gradually decreased when compared with the control group (Table 1). We found statistically significant differences among the experimental groups; control and alcohol + passive smoking group ($p=0,006$), alcohol and passive smoking ($p=0,005$), passive smoking and alcohol + passive smoking ($p=0,004$).

The testicular histology of control group was normal. The wall of each seminiferous tubule was composed of Sertoli cells and differentiating spermatogenic cells. The lamina propria enveloping the seminiferous

tubule consisted of several layers of fibroblasts. Interstitial cells occupied much of the space between the seminiferous tubules. (Figure 1).

Figure 1: Cross section of seminiferous tubules and interstitium in the control group, Haematoxylin and eosin., X200.



However, degenerative changes of various degrees were observed in the seminiferous epithelium in animals exposed to cigarette and/or alcohol. Seminiferous tubules with degenerated germinal epithelium were observed in a few tubules of testes in the passive smoking and alcohol groups. Degenerative changes were more severe in the group that was exposed to both alcohol and cigarette smoke. The most prominent degenerative findings in the alcohol + passive smoking groups were disorganization of germinal epithelium, desquamation of immature cells into the seminiferous tubule lumen and vacuolization in seminiferous epithelium (Figure 2, 3, 4). The thickening of tunica albuginea was observed in only two animals of the alcohol group (Figure 5). However, peritubular fibrosis was not observed in any of the groups. In summary, remarkable histologic differences were found between the control and the experimental groups.

Although we did not evaluate the number of Leydig cells per unit area in the present study, a slightly increased number of Leydig cells were observed in some animals of the passive smoking and alcohol groups (Figure 2).

Table 1: The means and their standard deviations of the body weight, testes weight, testes weight/ body weight ratio and the seminiferous tubule diameter in the control and treatment groups at the end of the experiment.

Groups	Body Weight (BW) [g]	Testes Weight (TW) [g]	TW/BW [%]	Seminiferous tubule diameter [µm]
Control	28.16 ± 3.02	0.25 ± 0.07	0.0079 ± 0.0015	207.0 ± 6.1 #
Alcohol	27.73 ± 3.08	0.28 ± 0.04	0.0100 ± 0.0017	194.8 ± 6.5 \$
Passive smoking	28.41 ± 1.84	0.29 ± 0.06	0.0100 ± 0.0018	204.8 ± 4.1 \$ ¥
Alcohol + Passive smoking	30.90 ± 3.24	0.26 ± 0.05	0.0099 ± 0.0001	192.6 ± 4.1 # ¥

$p=0.006$, \$ $p= 0.005$, ¥ $p= 0.004$

Figure 2: Cross section of seminiferous tubules and interstitium in the passive smoking group. Note seminiferous tubule degeneration (*arrow*) and Leydig cell hyperplasia. Haematoxylin and eosin., X400.

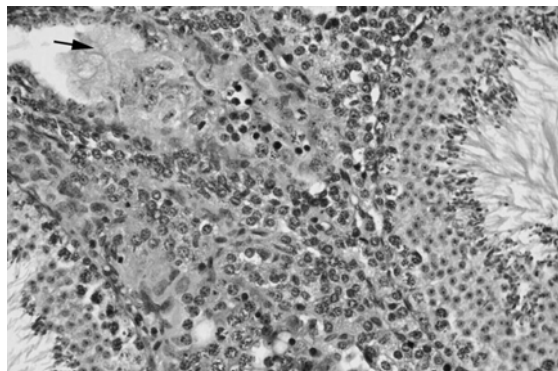
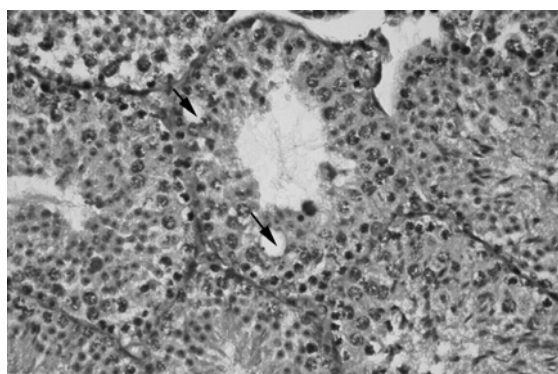


Figure 3: Cross section of seminiferous tubules with vacuolization (*arrows*) in alcohol + passive smoking group. Haematoxylin and eosin., X400.



DISCUSSION

There is controversy in the literature regarding the alterations in body weight and testicular weight of rodents due to ethanol consumption. Anderson et al.¹⁸ observed body weight gain in mice which were given alcohol similar to the controls. However others reported that the body weights of the ethanol consuming rats were significantly lower than those of controls.^{10, 11, 19- 21} On the contrary, no significant difference could be found between alcoholic rats and their control animals regarding weight gain.^{7, 13, 21} In the present study, no significant difference in mean body weight was observed among the groups with or without exposure to alcohol, sidestream smoking or both.

In this study, animals were exposed to gradually increased ethanol concentration. This was done in an attempt to minimize the decrease in food intake that

typically accompanies ethanol feeding and thus to reduce undernutrition in the animals. For this reason the changes in testis morphology that we observed were specific to ethanol and cigarette smoke and not attributable to undernutrition.

Figure 4: Cross section of seminiferous tubules with desquamation of immature cells into the seminiferous tubule lumen (*arrows*). Haematoxylin and eosin., X400.

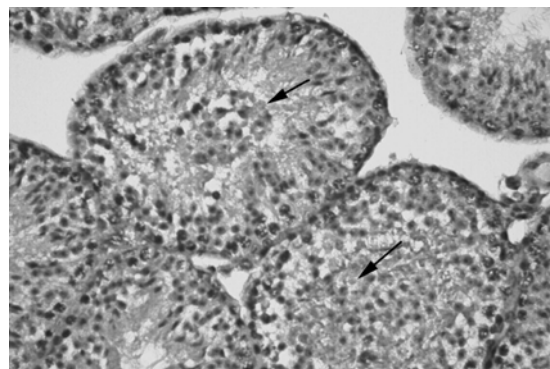
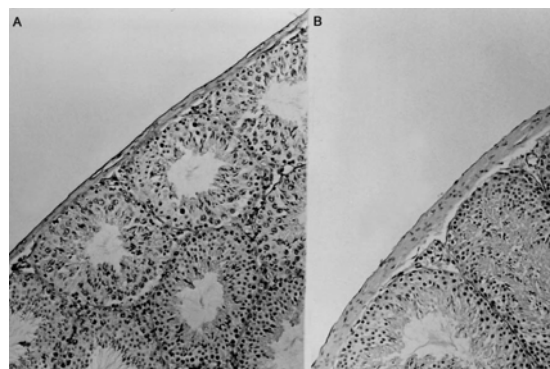


Figure 5: Cross section of tunica albuginea in control (A), and alcohol (B) groups. Haematoxylin and eosin., X100.



Some researchers have reported reduced testis weights in mice and rats treated with ethanol.^{7, 10, 14, 19- 24} However, some other researchers did not find significant differences in the testis weights of rats ingesting ethanol and their controls.^{11, 13} Similarly, in the present study, no differences were found in testis weights among the groups.

In some studies, relative testis weight (ratio of testes weight to body weight) was also compared with the absolute testis weight. Martinez et al.¹³ have observed that relative testis weights were significantly less in the ethanol-consuming animals compared to the control animals. Van Thiel et al.⁷ have reported both a lower absolute and relative testis weights in the

alcohol-consuming rat groups with respect to the control groups. On the other hand, Weinberg et al.¹⁰ have observed that absolute testis weight was also somewhat reduced in ethanol-consuming animals; however, when adjusted for body weight, relative testis weights were found to be increased in ethanol-fed animals compared with controls. Calleja et al.¹² have reported that high dose alcohol (25%) causes an increase relative testis weight in rats. Viczian²⁵ has reported that relative testis weight in rats shows no difference in between the group exposed to cigarette smoke and their controls. In our study, no significant difference in relative testis weight of passive smoking, alcohol, alcohol + passive smoking and control groups was observed.

Measurement of the seminiferous tubule diameter was carried out to determine the effects of alcohol and cigarette on testes in previous studies. It was reported that alcohol consumption caused a decrease in the mean seminiferous tubule diameter of rats,^{7, 12, 21, 26} mice^{14, 18} and humans.⁹ Some researchers have reported that inhalation of cigarette smoke also caused a decrease in seminiferous tubule diameter in rats.^{27, 28} However, Martinez et al.¹³ found no difference in the diameter of the seminiferous tubules between alcohol consuming groups and controls. In the present study, mean seminiferous tubule diameters were gradually decreased in groups exposed to passive smoking, alcohol, and alcohol + passive smoking. However, the decrease in mean seminiferous tubule diameters of animals exposed to both alcohol and sidestream smoking was significant when compared with controls ($p=0,006$).

Anderson et al.¹⁸ reported that thickness of tunica albuginea was occasionally decreased in the ethanol-treated mice after 29 days as compared to the control group. In contrast, no differences could be observed in testes from animals maintained on the ethanol diet for an additional 14 days. In the present study, thickening of tunica albuginea was observed only in 2 animals exposed to alcohol. Thickening of peritubular membrane has also been described in alcoholic men^{8, 9} and rats.²⁶ Güven et al.²⁷ reported thickened and irregular shaped seminiferous tubule basement membrane in smoke-exposed rats. However, Yardimoğlu et al.¹⁴ did not find any peritubular fibrosis in mice exposed to alcohol. Similarly, in the present study, no peritubular fibrosis was observed in animals of all groups.

It was previously reported that testes of the alcohol-fed animals were highly variable when examined by

light microscopy, ranging from complete spermatogenesis with disorganization of seminiferous epithelium to complete atrophy. Seminiferous tubules with disorganized germinal epithelium have been described in alcohol-fed rats^{13, 29} and alcoholic men.^{8, 9} Increase in germ cell desquamation into the seminiferous tubule lumina,^{9, 13, 18, 22, 23} and inactive seminiferous tubules^{18, 22, 23} were described in alcohol-fed animals and alcoholic men. Decreased spermatogenesis was reported by some researchers in alcoholic animals and men.^{8, 9, 22} Presence of a large number of vacuoles in the seminiferous tubules was observed in fetal rats exposed to alcohol.³⁰ Vacuolization in seminiferous epithelium was also reported in ethanol-treated mice.^{14, 29} and rats.¹³ Moderate or severe loss of germinal epithelium have been reported in seminiferous tubules of the testes in alcohol-fed animals^{14, 19, 21} Presence of degenerating or sloughed cells into the seminiferous tubule lumen were also observed in the testes of rats exposed to cigarette smoke.^{27, 28} In the present study, degenerative changes in seminiferous epithelium were observed occasionally in a few tubules of animals from both passive smoking and alcohol groups. In addition, degeneration of germ cells and vacuolization in seminiferous epithelium were observed in the majority of alcohol + passive smoking groups.

A slightly increased number of Leydig cells were observed in testis biopsies of alcoholic men by Boiesen et al.⁸ In some of the cases, particularly those with more severe testicular damage, Leydig cell hyperplasia was not seen in a study by Boiesen et al.⁸ Galvao-Teles et al.⁹ reported that the number of Leydig cells in the testes of alcoholic patients was highly variable ranging from apparent hypoplasia to hyperplasia. However, they have only found one case with hyperplasia of the Leydig cells. They reported that there was no correlation between testicular histology and the daily alcohol ingestion or the duration of alcoholism for their subjects.⁹ Van Thiel et al.⁷ have also reported that Leydig cell hyperplasia was clearly prominent in some of the testes obtained from the alcohol-fed animals. However, some researchers found that Leydig cell number was not modified by ethanol.^{13, 19} No data are available related to Leydig cell number in animals exposed to cigarette smoke. Although the number of Leydig cells per unit area was not assessed in this study, the number of Leydig cells appeared to increase in only a few animals of the passive smoking and alcohol groups.

Experiments studying the effects of alcohol and cigarette smoke on testis tissue have given different

results. Reasons may include the differences in age and breed of the experimental animals used, exposure route, doses and duration of exposures, and the type of diet. However, researchers agree in general that alcohol and smoking causes damage of varying degree to testis tissue. In the present study, it was observed that alcohol, passive smoking and alcohol + passive smoking caused significant morphological changes in testis tissue of mice and that these changes were more severe in alcohol + passive smoking group.

In summary, light microscopic evidence that we provide in this study indicate that alcohol, sidestream smoking and alcohol plus sidestream smoking have deleterious effects in testis of Swiss albino mice. These effects were especially prominent when mice were exposed to both alcohol and sidestream smoking compared with alcohol or sidestream smoking alone. This indicates that alcohol and smoking may have additive or synergistic effects when used together.

REFERENCES

- Ross MH, Romrell LJ, Kaye GI. *Histology. A Text of Atlas*; 5th ed.; Williams & Willkins, Baltimore, Maryland, 1995 :636-659.
- Aşut Ö. Hekim ve Sigara. *Türk Tabipleri Birliği Yayınları* 1993; 45-48.
- Stillman RJ, Rosenberg MJ, Sachs BP. Smoking and reproduction. *Fertil Steril* 1986; 46(4): 545-66.
- Zenzes MT, Bielecki R, Reed TE. Detection of benzo(a)pyrene diol epoxide-DNA adducts in sperm of men exposed to cigarette smoke. *Fertil Steril* 1999; 72(2):330-5.
- Chia SE, Ong CN, Tsakok FM. Effects of cigarette smoking on human semen quality. *Arch Androl* 1994; 33(3): 163-8.
- Vogt HJ, Heller WD, Borelli S. Sperm quality of healthy smokers, ex-smokers, and never smokers. *Fertil Steril* 1986; 45(1): 106-10.
- Van Thiel DH, Gavaler JS, Cobb CF, et al. Alcohol-induced testicular atrophy in the adult male rat. *Endocrinology* 1979; 105: 888-895.
- Boiesen PT, Lindholm J, Hagen C, et al. Histological changes in testicular biopsies from chronic alcoholics with and without liver disease. *Acta Path. Microbiol. Scan. Sect.A* 1979;87:139-142.
- Galvao-Teles A, Gonçalves L, Carvalho H. Alterations of testicular morphology in alcoholic disease. *Alcohol Clin Exp Res* 1983; 7:144-149.
- Weinberg J, Vogl AW. Effects of ethanol consumption on the rat seminiferous epithelium. *Journal of Andrology* 1988; 9(4):261-269.
- Salonen I, Huhtaniemi I. Effects of chronic ethanol diet on pituitary-testicular function of the rat. *Biol Reprod* 1990; 42:55-62.
- Calleja Escudero J, Rodriguez Tovez LA, Fernandez del Busto E, et al. Testicular changes produced by alcohol. *Actas Urol Esp* 1997;21(4):337-42.
- Martinez FE, Martinez M, Padovani CR, et al. Morphology of testis and epididymis in an ethanol-drinking rat strain(UChA and UChB). *J Submicrosc Cytol Pathol.* 2000;32(2):175-184.
- Yardımoğlu M, Mısırlıoğlu D. Histological effects of ethanol and protective effects of vitamin E on the morphology of seminiferous tubules in mice. *Gaziantep Devlet Hastanesi Anadolu Tıp Dergisi* 2001; 3(3) : 147-154.
- Rosenblum E, Gavaler JS, Van Thiel DH. Lipid peroxidation: a mechanism for ethanol associated testicular injury in rats. *Endocrinology* 1985; 116(1): 311-8.
- Farghali H, Williams DS, Gavaler J, et al. Effect of short-term ethanol feeding on rat testes as assessed by 31 P NMR spectroscopy, 1 H NMR imaging, and biochemical methods. *Alcohol Clin Exp Res* 1991; 15:1018- 1023.
- Marja J. Norusis. *SPSS 9.0 Guide to data analysis.* Prentice-Hal, NewJersey 1999, 343-345.
- Anderson RA, Willis BR, Phillips JF, et al. Delayed pubertal development of the male reproductive tract associated with chronic ethanol ingestion. *Biochemical Pharmacology* 1987; 36(13):2157-2167.
- Gonzales-Reimers E, Martinez-Riera A, Santolaria-Fernandez F, et al. Relative and combined effects of ethanol and protein deficiency on gonadal function and histology. *Alcohol* 1994;11(5):355-360.
- Srikanth V, Balasubramanian K, Govindarajulu P. Effects of ethanol treatment on Leydig cellular NADPH-generating enzymes and lipid profiles. *Endocr.J.* 1995, 42(5): 705-12.
- Gavaler JS, Van Thiel DH, Lester R. Ethanol: A gonadal toxin in the mature rat of both sexes. *Alcoholism: Clinical and Experimental Research* 1980; 4(3):271-275.
- Willis BR, Anderson RA, Oswald C, et al. Ethanol-induced male reproductive tract pathology as a function of ethanol dose and duration of exposure. *J Pharmacol Exp Ther* 1983 ;225(2):470-8.
- Anderson RA, Willis BR, Oswald C. Spontaneous recovery from ethanol-induced male infertility. *Alcohol* 1985;2(3):479-84.
- Fermoso J, Esquifino AI, Mateos A, et al. Possible role of prolactin in the induction of hypogonadism by chronic alcohol treatment in the male rat. *Pharmacol Biochem Behav.* 1988; 29(3):489-93.
- Viczian M. The effect of cigarette smoke inhalation on spermatogenesis in rats. *Experientia* 1968;24(5):511-13.
- Shirai T, Ikemoto I. Mechanism of alcoholic testicular damage. *Nippon Hinyokika Gakkai Zasshi* 1992;83(3):305-14.
- Güven MC, Can B, Ergün A, Saran Y. Ultrastructural effects of cigarette smoke on rat testis. *Eur Urol* 1999; 36: 645-49.
- Rajpurkar A, Li H, Dhabuwala CB. Morphometric analysis of rat testis following chronic exposure to cigarette smoke. *J Environ Pathol Toxicol Oncol* 2000;19(4):363-8.
- Anderson RA Jr, Berryman SH, Phillips JF, et al. Biochemical and structural evidence for ethanol-induced impairment of testicular development: apparent lack of Leydig cell involvement. *Toxicol Appl Pharmacol* 1989; 100(1) : 62-85.
- Mc Givern RF, Raum WJ, Salido E, et al. Lack of prenatal testosterone surge in fetal rats exposed to alcohol: alterations in testicular morphology and physiology. *Alcohol Clin Exp Res* 1988; 12(2): 243-7.

Yazışma Adresi:

Yrd.Doç.Dr. Semra ERPEK
Adnan Menderes Üniversitesi Tıp Fakültesi
Histoloji-Embriyoloji AD, Aydın
E-Posta : semraerpek@yahoo.com
Tel : 256 2253 166
Faks : 256 2132 537