



## The Vanishing Twin

Önder Çelik\*, Şeyma Hasçalık\*, Mine Karaaslan\*\*, Bülent Mızrak\*\*\*

\*: Inonu University, Medical Faculty, Department of Obstetrics and Gynecology, Malatya, Turkey

\*\* :Malatya City Hospital, Clinic of Obstetrics and Gynecology, Malatya, Turkey

\*\*\*: Inonu University, Medical Faculty, Department of Pathology, Malatya, Turkey

Women with twin pregnancy have some rare problems and some of them occur more frequently than those seen in singleton pregnancies. Examples of the former are the vanishing twin and death of other fetus. With the advent of ultrasonography, a multiple pregnancy may be diagnosed in early stage of gestation. Serial sonographic evaluations can display the disappearance of one of two twins. One case of a vanishing twin is reported.

**Key Words:** Vanishing twin, Ultrasonography

### Kaybolan İkiz

İkiz gebeliklerde komplikasyon görülme oranı normal tekil gebeliklere göre daha yüksek olup, bazı nadir komplikasyonlar da bu gebeliğe özgüdür. Ultrasonografi yardımı ile çoğul gebelikler, erken gebelik dönemlerinde saptanabilir. "Kaybolan ikiz" fenomeni bu komplikasyonlardan birisi olup seri ultrasonografik takiplerde ikizlerden birisinin öldüğü, diğer gebeliğin ise devam ettiği gösterilebilir. Bir "Kaybolan ikiz" olgusu literatür gözden geçirilerek sunuldu.

**Anahtar Kelimeler:** Kaybolan ikiz, Ultrasonografi

+ The manuscript has been accepted in the 2<sup>nd</sup> World Congress Of Perinatal Medicine For Developing Countries And 8<sup>th</sup> National Congress on Perinatology 2002 as a poster presentation.

Vanishing twin is a common, maternal age-dependent phenomenon and the incidence of this event is estimated to be between 25 and 45%. Vaginal bleeding is the only complication that is associated with vanishing twin.<sup>1</sup> Although this information is not confirmed by other studies the prognosis for the living fetus seems good.<sup>2</sup>

### Case

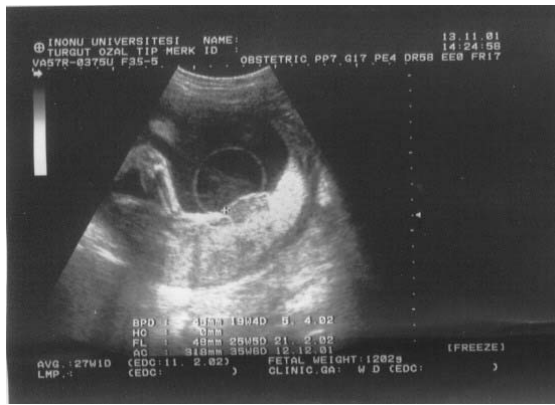A 30-year-old multipara, who had 7 weeks 2 days gestation according to last menses period, was admitted to our department for routine sonographic examination. She had previous 3 healthy term pregnancies but there were no history of curettage and abortion before. We observed twin pregnancy in woman, who had ultrasound examination at the 8th week of pregnancy. Positive heartbeat and yolk sac were registered in both embryos. When a further sonographic examination took place at the 11th week for nuchal translucency, intrauterine death one of the embryos was observed (Figure 1). Pregnancy continued as singleton pregnancy to uneventful term deliveries. After singleton term delivery a thickening of the membranes opposite to the main placenta showed degenerated chorionic villi embedded between one layer of amnion and chorion; no fetal parts were observed (Figure 2,3 and 4).

### Discussion

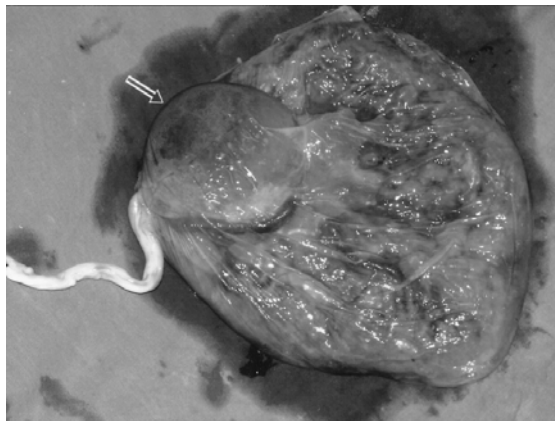
Until the advent of ultrasound, the ability to document early fetal loss in multiple gestation was difficult. Serial sonographic evaluations can display the disappearance of one of two twins, and 21.2% of them demonstrated the vanishing twin phenomenon, often with associated bleeding, but with a good prognosis for the other fetus. In spite of the higher abortion rate in IVF pregnancies compared with natural pregnancies, ovulation induction procedure did not appear to change these finding.<sup>3</sup> Several explanations are offered for mechanisms of disappearance, such an

artificial error and insufficient image technique. The only complication associated with disappearance of a fetus is slight vaginal bleeding.<sup>4,5</sup> Women with a vanishing conception should be counseled on the possibility of vaginal bleeding. If vaginal bleeding occurs 12 weeks after the conception rhesus prophylaxis should be done. Histopathological examination of the placental lesions were characterized by well-delineated plaques of perivillous fibrin deposition, but usually fetal parts do not determine.<sup>6</sup> After termination of multiple pregnancies the comprehensive check-up of the newborn and histopathological evaluation of the placenta, amnion and chorion are crucial.

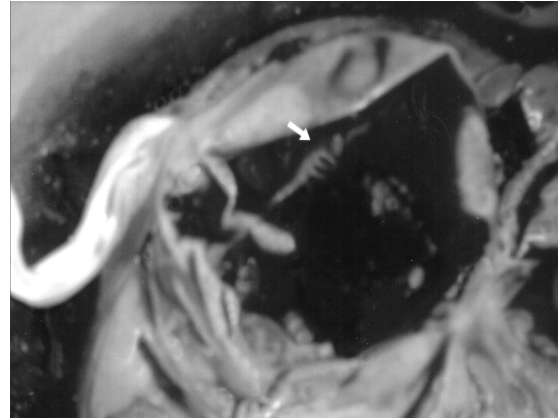
**Figure 1.** Vital fetus and empty gestational sac



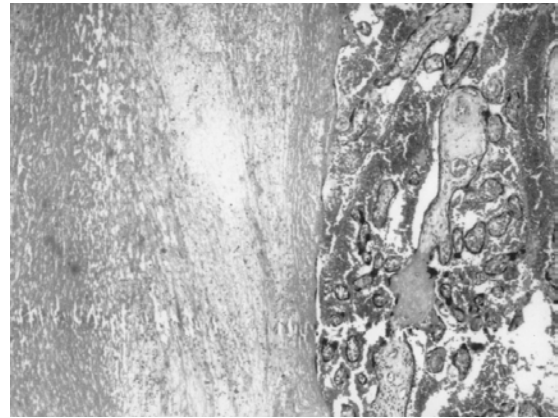
**Figure 2.** Macroscopic appearance of empty gestational sac (white arrow) and placenta after delivery.



**Figure 3.** When the gestational sac was opened no fetal parts were observed.



**Figure 4.** Normal appearing villi are seen on the right and sharply delineated fibrinoid mass on the left (Hematoxylin&Eosin, x50)



## REFERENCES

1. Landy HJ, Weiner S, Corson SL, Batzer FR, Bolognese RJ. The "vanishing twin": ultrasonographic assessment of fetal disappearance in the first trimester. *Am J Obstet Gynecol* 1986;155:14-9.
2. Landy HJ, Keith L, Keith D. The vanishing twin. *Acta Genet Med Gemellol* 1982;3:179-94.
3. FIVNAT (French In Vitro National). French National IVF registry: analysis of 1986 to 1990 data. *Fertil Steril* 1993;59:587-95.
4. Spellacy WN. Antepartum complications in twin pregnancies. *Clin Perinatol* 1988;15:79-86.
5. Saidi MH. First-trimester bleeding and the vanishing twin. A report of three cases. *J Reprod Med* 1988;33:831-4.
6. Sulak LE, Dodson MG. The vanishing twin: pathologic confirmation of an ultrasonographic phenomenon. *Obstet Gynecol* 1986;68:811-5.

## Corresponding Author:

Yrd.Doç.Dr.Önder Çelik  
Inonu University Medical Faculty  
Department of Obstetrics and Gynecology  
44069 Malatya, Turkey