

# MORGAGNI HERNIA ACCOMPANIED BY OBSTRUCTION OF URETERO-PELVIC JUNCTION IN CHILDHOOD

Hanifi SOYLU, MD \*  
Mehmet DOĞRUL, MD \*  
N.Onur KUTLU MD \*  
Tamer BAYSAL, MD \*\*  
Ergün SÖNMEZGÖZ, MD \*  
Ayşehan AKINCI, MD \*

*Diaphragmatic hernias (DH) are rare congenital defects with different types. Morgagni hernia (MH) is the least frequent one. Although Morgagni hernia is a surgical condition, for its asymptomatic course, diagnosis is usually incidental in a pediatric unit. Morgagni hernia can be associated with other congenital anomalies such as heart defects, omphalocele, mental retardation, pectus carinatum and trisomia 21. The association of Morgagni hernia and genitourinary anomaly is very rare. Here we report a case of Morgagni hernia accompanied by uretero-pelvic obstruction.*

**Key words:** Morgagni hernia, genito-urinary anomaly, childhood.

## **Üretero-pelvik obstrüksiyonun eşlik ettiği çocukluk çağı morgagni hernisi**

*Diyafragma hernileri nadir görülen konjenital defektlerdir. Bir çok tipleri olmakla birlikte, en az görülen tiplerinden birisi Morgagni hernisidir. Her ne kadar cerrahi bir olay olsa da, semptomsuz olması nedeniyle Morgagni hernilerinin çoğu bir pediatri ünitesinde tesadüfen saptanır. Morgagni hernisi ile kalp defektleri, omfalosel, mental retardasyon, güvercin göğsü anomalisi ve trizomi 21 birlikte bulunabilir. Genitoüriner sistem anomalisi ile birlikteliği de çok nadir olarak rapor edilmiştir. Biz de uretero-pelvik obstrüksiyonla birlikte olan Morgagni hernisini ünitemizde teşhis ederek, çok nadir görülmesi nedeniyle rapor ettik.*

**Anahtar kelimeler:** Morgagni hernisi, genito-üriner anomalisi, çocukluk çağı.

\* İnönü University  
Department of Pediatrics  
MALATYA - TURKEY  
\*\* İnönü University  
Department of Radiology  
MALATYA - TURKEY

### **Correspondence adress:**

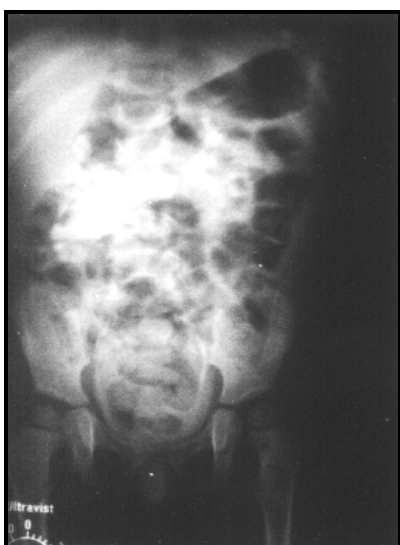Dr.Hanifi Soyulu  
İnönü University  
Department of Pediatrics,  
MALATYA, TURKEY.

Tel: 90 422 341 0660  
Fax: 90 422 341 0728-29

Morgagni hernia (MH) is a very rare congenital diaphragmatic hernia<sup>1</sup>. It is first described by Morgagni and Larrey in 1761 and 1829 respectively<sup>2</sup>. Therefore, it is also called as Morgagni-Larrey hernia. Although, MH is a surgical condition the patients are usually diagnosed incidentally at a pediatric unit because of their nonsurgical complaints<sup>3</sup>. For this reason, a pediatrician has to know its specific clinical and radiological features. Here we report a case of pediatric Morgagni hernia diagnosed on a routine chest roentgenogram in our pediatric clinic.

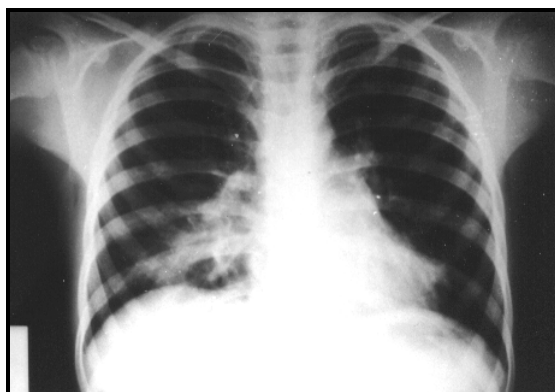
**CASE**

A 6-year old girl was admitted to our pediatric outpatient clinic with complaints of high fever and persistent cough. She was hospitalized two months ago and treated for ten days because of bronchopneumonia. She also was operated when she was forty five days old for obstruction of uretero-pelvic junction of the right kidney (Figure 1). Her familial history was unremarkable.

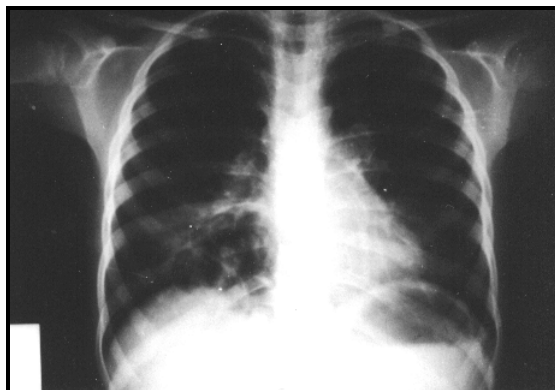


**Figure 1.** Intravenous pyelogram of the patient at 1 1/2 month: Obstruction of uretero-pelvic junction, and secondary pelvi-calixial dilatation on the right kidney are

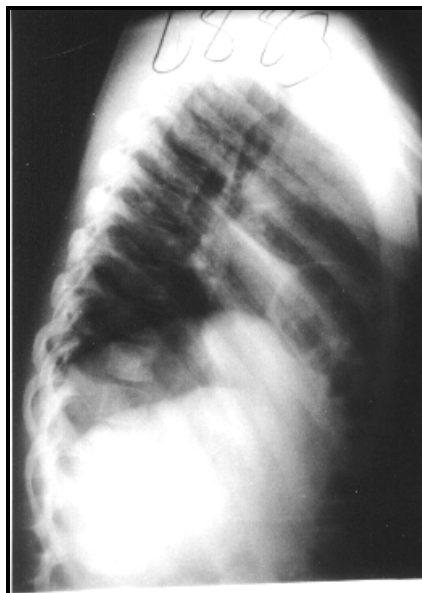Physical examination revealed high fever (38°C), tonsillopharyngeal hyperemia and bilateral crackling rales on chest auscultation. There was no abnormal laboratory result except mild anemia and leukocytosis. Plain chest x-ray showed a large paracardiac pneumonic consolidation localized on right cardio-phrenic angle (Figure 2). Although the symptoms and signs of the patient improved in seven days after adequate antibacterial treatment, the consolidation persisted and multiple cystic areas were noted in the consolidation area (Figure 3). Lateral chest x-ray also showed gas containing intestinal loops immediately behind the sternum (Figure 4). Diagnosis of MH was also confirmed by barium-mealed colon radiogram showing presence of transverse colon was in the thorax (Figure 5). The patient was referred to the pediatric surgery division with diagnosis of MH.



**Figure 2.** The plain chest roentgenogram, a lobular consolidated area on the right cardio-phrenic angle consisting a large cystic cavity at the supradiaphragmatic region.

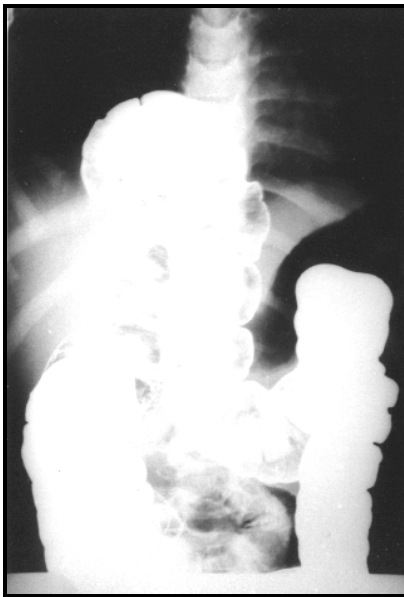


**Figure 3.** Seven days later, the consolidation has partially decreased and multiple air cysts on the same area were noted.



**Figure 4:** The lateral chest roentgenogram, multiple air-cysts and intestinal loops lining through retro xypho-sternal region to the thorax. Evidence of interlobar fissure between middle and inferior lobes is seen.

## Morgagni hernia accompanied by obstruction of uretero-pelvic junction in childhood



**Figure 5.** Barium mealed colon roentgenogram determined the thinned transverse colon in the thorax.

### DISCUSSION

Congenital diaphragmatic hernias (CDH) are rare congenital defects<sup>4</sup>. Torfs et al.<sup>5</sup> determined the frequency of CDH in 718,208 births, and they found 237 cases. MH is the least common form of CDH, represents 3,5 % of CDH<sup>4,5</sup>. It occurs in 90 % of the cases on the right side, or bilaterally 7% or rarely on the left side<sup>6</sup>. The hernia occurs secondary to potentially anterior medial defect in diaphragma<sup>4</sup>. It is usually covered with a sac which includes transverse colon, omentum, liver, stomach and small intestine<sup>3,7</sup>. In the present case, the defect was on the right side and the herniated abdominal content was transverse colon.

MH is usually asymptomatic. For this reason, the majority of the cases are diagnosed incidentally<sup>1,4,6</sup>. There are some cases as old as 78 years in literature<sup>4</sup>.

MH in childhood is more associated with symptoms than those of the adults. The symptoms may be gastrointestinal (i.e constipation, diarrhea, vomiting, abdominal pain mimicking peptic ulcer or gallbladder diseases), or respiratory (i.e recurrent respiratory infections, respiratory distress), which are not

specific<sup>8,9</sup>. The patient in our case had two bronchopneumonia attacks in the last months. Morgagni hernia was incidentally diagnosed during the investigation of her respiratory complaints.

MH may be associated with significant anomalies<sup>7</sup>, such as congenital heart defects, genitourinary abnormalities, omphalocele, mental retardation, pectus carinatum and trisomia 21<sup>10,11</sup>. Congenital heart defects are the most associated congenital defects<sup>12</sup>. However, the concurrence of genitourinary system anomalies and MH is extremely rare. This association was reported only one case among 153 cases of congenital diaphragmatic hernia (Table 1). Our patient was operated on the first year of life for uretero-pelvic junction obstruction. Thereby, this situation supports the relation between congenital defects and MH.

**Table 1.** Associated anomalies with congenital diaphragmatic hernia

•Malrotation
•Congenital heart lesions
Patent ductus arteriosus
Hypoplastic left heart
VSD
ASD+Coarctation of aorta
Pulmonary stenosis
•Undescendent testes
•Meckel's diverticulum
•Skeletal anomalies
Minor deformities
Talipes equinovarus
Multiple hemivertebrae
Craniostenosis
•Myelomeningocele
•Renal anomalies
Ectopic (thoracic) kidney
Ectopic (pelvic) kidney
UPJ obstruction
•Inguinal hernia
•Extralobar pulmonary sequestration
•Cystic adenomatoid malformation of lung
•Duodenal atresia
•Hirschsprung's disease
•Oesophageal atresia
•Omphalocele
•Choanal atresia
•Pectus carinatum
•Down syndrome

Chest x-ray is the most common diagnostic test for MH<sup>8</sup>. It usually shows a moderate dense

tumor, or gas containing intestinal loops, usually on the right cardiophrenic angle in the posteroanterior chest roentgenogram. The gas containing intestinal loops also can be determined behind the xiphosternum on the lateral chest roentgenogram<sup>3,8</sup>. The diagnosis is also confirmed later with barium meal studies, CT or MRI examinations<sup>3,13-15</sup>. On thorax CT, the hernia can mimic lipoma or liposarcoma, whereas MRI can clearly demonstrate and differentiate the mass<sup>14,15</sup>. In our case, the hernia was initially noticed as a right cardiophrenic mass on the plain chest X-ray, and showed cystiform appearance in a few days. The lateral chest x-ray and barium mealed colon radiogram confirmed the diagnosis.

When the diagnosis of MH was confirmed, the majority of the surgeons prefer the operation<sup>15</sup>. However, because of the non-specific complaints or asymptomatic course, MHs are usually diagnosed by pediatricians. We consider, a pediatrician has to remember MH on the presence of consolidation or cystic areas in the chest roentgenogram inconsistent with the clinical findings. Once MH diagnosed an

additional heart, genitourinary or chromosomal defects should be investigated.

## REFERENCES

1. Bettli G, Bianchi S, Camoglio FS, Baggio E, Consolaro G, Ottolenghi A . Morgagni's hernia in infancy. *Minerva Chir* 1997; 52:295-9.
2. Irving IM, Booker PD. Congenital diaphragmatic hernia and eventration of the diaphragm. In: Lister J, Irving IM, editors. *Neonatal Surgery*. London: Butterworths 1990. 199-220.
3. Sarihan H, İmamoğlu M, Abes M, Soylu H. Pediatric Morgagni hernia. Report of two cases. *J Cardiovasc Surg* 1996; 37:195-7.
4. Orita M, Okino M, Yamashita K, Morita N, Esato K. Laparoscopic repair of a diaphragmatic hernia through the foramen of Morgagni. *Surg Endosc* 1997; 11:668-70.
5. Torfs CP, Curry CJ, Bateson TF, Honore LH. A population based study of congenital diaphragmatic hernia. *Teratology* 1992; 46:555-65.
6. Şenyüz OF. Pectus carinatum associated with Morgagni hernia in a child. *Surgical Rounds* 1987; 12:60-3.
7. Milne LW, Morosin AM, Campbell JR, Harrison MW. Pars sternalis diaphragmatic hernia with omphalocele: a report of two cases. *J Ped Surg* 1990; 25:726-30.
8. Pul M, Pul N. Morgagni hernia in infants and children. *Yonsei Med J* 1995; 36:306-9.
9. Wong NA, Dayan CM , Heaton KW. Acute respiratory distress secondary to Morgagni diaphragmatic herniation in an adult. *Postgrad Med J* 1995; 71:39-41.
10. Polcorny WJ, McGill CW, Halberg FJ. Morgagni hernia during infancy: presentation and associated anomalies. *J Pediatr Surg* 1984; 19:394-7.
11. Quah BS, Menon BS. Down syndrome associated with retroperitoneal teratoma and Morgagni hernia. *Clin Genet* 1996; 50:232-4.
12. Berman L, Stringer D, Ein SH, Shandling B. The late presenting pediatric Morgagni hernia: a benign condition. *J Ped Surg* 1989; 24:970-2.
13. Komarow I. A case of Morgagni's hernia treated surgically. *Pneumonol Alergol Pol* 1996; 64:478-80.
14. Kamiya N, Yokoi K, Miyazawa N , Hishinuma S , Ogata Y , Katayama N. Morgagni hernia diagnosed by MRI. *Surg Today* 1996; 26:446-8.
15. Hussong RL Jr, Landreneau RJ, Cole FH Jr. Diagnosis and repair of a Morgagni hernia with video-assisted thoracic surgery. *Ann Thorac Surg* 1997; 63:1474-75.