

## Stargardt's Macular Dystrophy

Hamdi Er, MD<sup>1</sup>, Hüseyin Bayramlar, MD<sup>1</sup>, Serdar Marol, MD<sup>1</sup>

*Stargardt's macular dystrophy is primarily disorders of photoreceptor's cells (cone-rod) and pigment epithelium. It affects male and female equally, especially in the first and second decade of life and leads to bilateral, symmetric loss of visual acuity. The transmission of inheritance is frequently recessive trait. The purpose of this report is to present and review Stargardt's macular disease (that was detected in 5 siblings of a family) under the light of new literature studies. [Journal of Turgut Özal Medical Center 1996;3(2):113-115]*

**Key Words:** Genetics, macular degeneration, Stargardt's dystrophy

### Stargardt maküler distrofisi

*Stargardt maküler distrofisi primer olarak fotoreseptör hücrelerinin (kon-rod) ve pigment epitelyumunun bozukluğudur. Özellikle ilk ve ikinci dekatta kadın ve erkekleri eşit olarak tutar ve bilateral, simetrik görme keskinliği kaybına yol açar. Sıklıkla resesif geçişlidir. Bu vaka bildiriminin amacı bir ailede 5 kardeşte saptanan Stargardt maküler hastalığını yeni literatür bilgileri ışığı altında sunmak ve gözden geçirmektir. [Turgut Özal Tıp Merkezi Dergisi 1996;3(2):113-115]*

**Anahtar Kelimeler:** Genetik, maküler dejenerasyon, Stargardt distrofisi

Stargardt's macular dystrophy was firstly described in 1909 by Karl Stargardt (1). This macular disorder arises from photoreceptor cells (cone-rod). It generally affects several siblings in the same family, but the parents remain mostly unaffected that suggest an autosomal recessive inheritance. Moreover, an autosomal dominant transmission was also reported among the first-degree relatives and together with progressive loss of visual acuity (2).

The symptoms begin in the first and second decade of life with symmetric, bilateral gradual decline of visual acuity. In the initial stage, the first ophthalmoscopic signs are loss of the foveolar reflex and observation of perifoveolar flecks. After that, atrophic macular lesions ensue with varying number of yellowish deep retinal flecks. These all extend the midperiphery over time, but never

involve the periphery. No effective treatment is available for stopping or delaying of onset the progressive visual loss.

#### CASE REPORT:

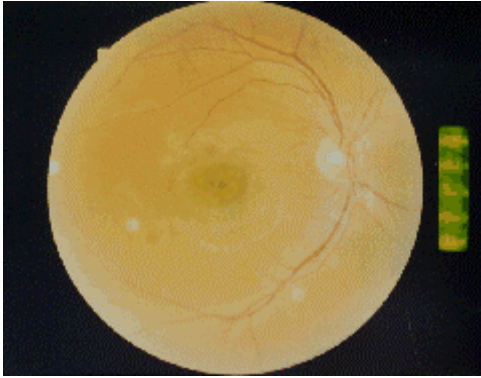
Two sisters (14-year-old and 24-year-old) admitted to our outpatient clinic three months ago with a complaint of gradually diminution of visual acuity in the past 5 to 6 years. From their history it was learned that their visions were entirely normal before and had no any family history in terms of eye problem. In the examination of their parents had no any ophthalmologic disorder and had fully normal fundus appearance.

24-year-old (FT)'s visual acuity was 2 mcf (meters counting fingers) to 3 mcf and 7/10 with pinhole in both eyes, and refraction was right eye -0.50-0.50x120, left eye -0.25-0.50x105. The slit-

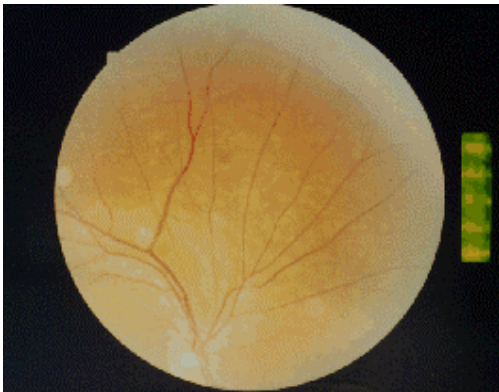
<sup>1</sup> İnönü University, School of Medicine, Department of Ophthalmology, Malatya

lamp biomicroscopic examination was unremarkable. She had moderate red-green dyschromatopsia in Ishihara color discrimination test. Intraocular pressure (IOP) by applanation was 18 mmHg in each eye. The pupil and light reflex were normal. A dilated fundus examination showed bilateral, symmetric atrophic macular lesion with surrounding yellowish flecks extending to the midperipheral area (Fig.1 and 2).

The other sister (ET)'s visual acuity was measured 5 mcf in both eyes and was no improvement with pinhole and her right eye refraction was plano+0.25x130, left eye refraction +0.50+0.50x110. Slit-lamp biomicroscopy revealed a normal anterior segment and intraocular pressures measured 15 mmHg in the right eye and 16 mmHg in the left eye. The pupil and light reflexes were normal as well. Ophthalmoscopic examination of both eyes showed loss of the foveolar reflex with numbers of flecks extending from perifoveola to



**Figure 1.** Fundus photography of patient's right eye showing prominent atrophic macular scar with surrounded flecks.



**Figure 2.** Same patient's right eye other photography showing flecks extended to the midperipheral area.

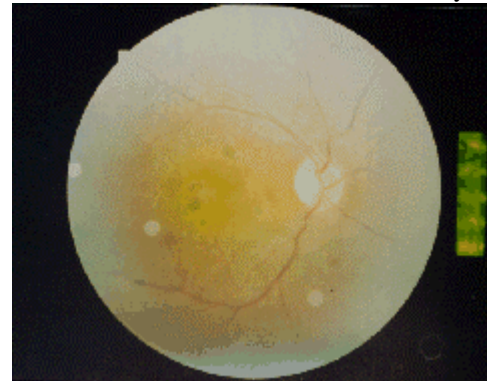
midperiphery (Fig.3). She had also mild red-green color discrimination defect in Ishihara test like her sister.

Having completed both sister's examinations, the other sister, 2 brothers and their parents called for ophthalmic examination. Though early macular pigmentary changes with a few dispersed, whitish, pigmentary changes in the posterior pole were present in both eyes of third sister who was 13-year-old (ST), her visual acuity was 10/10. The other examination findings were unremarkable.

Two brothers who were 25-year-old (MT) and 27-year-old (AT) both asymptomatic yet, funduscopic examinations showed mild pigment epithelium changes in their macular areas. Additionally one toxoplasmosis scar was detected in 27-year-old (AT)'s funduscopic examination. Past medical histories of all siblings were unremarkable and no any important findings was found systematically. These patients have been following up periodically for one year.

## DISCUSSION

Stargardt's disease is called with different names such as juvenile macular degeneration, cone-rod dystrophy, fleck retinopathy. There is still confusion about the use of the terms between fundus flavimaculatus from fleck retinopathies groups and Stargardt's disease. If the disease starts later in life like after 20-year-old, flecks embracing the macula with a few macular changes and partly preservations of visual acuity exist, the disorder should be described fundus flavimaculatus. Generally, the



**Figure 3.** Fundus photography of right eye shows moderate atrophic macula.

patients are classified into different groups according to angiographic and ophthalmoscopic features (3). If all this pathology starts in early like first and second decade of life, the term Stargardt's dystrophy is preferable (4).

Mode of inheritance is mostly autosomal recessive trait (5). Recently, some genetic analyses have demonstrated that the responsible mutated gene is placed on chromosome 1p. Furthermore, dominant transmission even mitochondrial traits has been reported. Chromosome 13 band q34 is accepted as a responsible gene for dominant transmission (6).

The visual fields are generally remain in the normal limits for these patients. Color vision is not affected as seen as many other macular diseases. Affected colors are frequently red-green and this affection remains at the mild to moderate levels. Moreover, the patients with Stargardt's disease suffer more difficulty in night time than daytime. Therefore, nighttime activities such as driving could be more dangerous than daytime ones (7). In our cases, there were mild red-green dyschromatopsia and similar difficulties in daytime and nighttime. Pathology in this dystrophy starts centrally in the photoreceptor cells and pigment epithelium, then involve perimacular areas and macular changes take snail-slime or beaten bronze appearance. Some studies reported that the defects in the photoreceptor ensue after pigment epithelium abnormality (8). Abnormality is thought in the intracellular transport mechanism or at the enzyme level of pigment epithelial cells (9). The accumulated substances are an acid mucopolysaccharide and lipofuscin in the pigment epithelial cells that eventually cause photoreceptor's death (10).

There is no any effective therapy to prevent the loss of visual acuity. However, both distances and near visions can be improved with the use of low vision aid methods like telescopic system (11,12).

In this paper, Stargardt's macular dystrophy which was detected among the members of a family has been reviewed under the light of new literature.

## REFERENCES

1. Editorial. Stargardt's macular dystrophy. Arch Ophthalmol 1994;112:752-4.
2. Cibis GW, Morey M, Harris DJ. Dominantly inherited macular dystrophy with flecks (Stargardt's). Arch Ophthalmol 1980;98:1785-9.
3. Atmaca LS, Özmert E. Stargardt hastalığı (Benekli atrofik makula distrofi). TOD XXIII Ulusal Kong Bült 1989;169-73.
4. Smith BF, Smith JB, Low J. Stargardt's disease: the evolution of a diagnosis. J Pediatr Ophthalmol Strabismus 1987;24:259-62.
5. Özbayrak H, Özkan F. Stargard hastalığının genetik özellikleri. TOD XXIV Ulusal Kong Bült.1990;168-71.
6. Zhang K, Bither PP, Park R, Donoso LA, Seidman JG, Seidman CE. A dominant Stargardt's macular dystrophy locus maps to chromosome 13q34. Arch Ophthalmol 1994;112:759-64.
7. Szlyk JP, Fishman GA, Severing K, Alexander KR, Viana M. Evaluation of driving performance in patients with juvenile macular dystrophies. Arch Ophthalmol 1993;111:207-12.
8. Eagle RC, Lucier AC, Bernardino VB, Yanoff M. Retinal pigment abnormalities in fundus flavimaculatus: a light and electron microscopic study. Ophthalmology 1980;87:1189.
9. Fishman GA, Farbman JS, Alexander KR. Delayed rod dark adaptation in patients with Stargardt's disease. Ophthalmology 1991;98:957-62.
10. Dorey CK, Wu G, Ebenstein D, Garsd A, Weiter JJ. Cell loss in the aging retina. Relationship to lipofuscin accumulation and macular degeneration. Invest Ophthalmol Vis Sci 1989;30:1691-9.
11. Fonda G, Gardner LR. Characteristics and low vision corrections in Stargardt's disease. educational and vocational achievements enhanced by low vision corrections. Ophthalmology 1985; 92:1084-91.
12. Collee CM, Jalkh AE, Weiter JJ, Friedman GR. Visual improvement with low vision aids in Stargardt's disease. Ophthalmology 1985;92: 1657-9.

### Correspondence Address:

Yrd.Doç.Dr. Hamdi ER  
İnönü University School of Medicine  
Department of Ophthalmology  
44100 MALATYA  
Tel: (422) 3258449  
Fax:(422) 3254132