



Lower Extremity abscess mimicking Baker's cyst rupture in a patient with diabetic ketoacidosis

Diabetik hastada baker kist rüptürünü taklit eden alt ekstremite absesi

Emre Gonullu¹, Çağrı Tiryaki², Goknur Yorulmaz³, Emel Gonullu³, Mustafa Diker⁴, Emine Karkac³

¹Eskisehir State Hospital, General Surgery Clinic, Eskisehir, Turkey

²Kocaeli Derince Education and Research Hospital, General Surgery Clinic, Kocaeli, Turkey

³Eskisehir State Hospital, Internal Diseases Clinic, Eskisehir, Turkey

⁴Eskisehir State Hospital, Orthopedics and Traumatology Clinic, Eskisehir, Turkey

Dear Editor,

Diabetes Mellitus can cause a number of complications including diabetic peripheral neuropathy, lower extremity fractures, Charcot arthropathy, ulcers and infections that may also interfere with rheumatic diseases (1-5). Here, a diabetic patient with staphylococcal abscess formation around the left leg muscles mimicking Baker's cyst rupture will be presented.

Sixty-year-old woman was admitted to the emergency department with severe pain in the left leg, with swelling and limitation of movement. Continuous fever around 39-40°C was present. The patient's blood glucose was 555 mg / dL and she was in diabetic ketoacidosis. She could not move her left lower extremity because of pain in our physical examination. She was keeping her left hip in internal rotation and knee in flexion with external rotation, constantly for relief of pain. Left lower extremity was tender with swelling as more marked under the left knee. Firstly, left femoral neck fracture was considered but there was no fracture in X-ray. This finding was confirmed with computed tomography, later. Lower extremity venous doppler was performed for differential diagnosis of deep vein thrombosis but there was not any thrombus. Physical examination also revealed mild effusion of the knee. A **magnetic resonance imaging** (MRI) was performed because of left knee pain which revealed a Baker cyst. We concluded that the left knee pain was due to the cyst rupture. The patient was also assessed by an orthopedist during the procedure. He planned a left cruris MRI for the patient. An abscess formation, showing a mass effect around the middle area of the left cruris, adjacent to the anterior muscle fascias was determined. The craniocaudal length of the abscess was about 140 mm with a depth of 45 mm (Figure 1).

Two liters of purulent material was aspirated from this area by orthopedist and parenteral antibiotics were started. Staphylococcus aureus was detected in culture of blood and abscess samples. The patient fully recovered with antibiotics, insulin and fluid replacement therapies.

Diabetes Mellitus can cause a number of complications including, diabetic peripheral neuropathy, lower extremity fractures, Charcot arthropathy, ulcers and infections that may also interfere with rheumatic diseases.

Additionally, diabetes also causes increased rates of orthopedic surgery or procedure complications as delayed healing. (1-5). Physicians may also face with other rare conditions like skeletal muscle infarction (6). Baker's cyst means popliteal synovial cysts and this results from intra-articular knee pathologic conditions (7). Cysts may rupture and cause pain and swelling of the leg. This leads the physicians to make a differential diagnosis like deep vein thrombosis, lymphedema, cellulitis and other conditions that cause swelling in the legs (8).

Received/Başvuru: 04.02.2016
Accepted/Kabul: 21.03.2016

Correspondence/İletişim

Çağrı Tiryaki
Kocaeli Derince Education and
Research Hospital, General Surgery
Clinic, Kocaeli, Turkey
E-mail: drcagritiryaki@hotmail.com

How to cite this article/Atıf için

Gonullu E, Tiryaki C, Yorulmaz G,
Gonullu E, Diker M, Karkac E. Lower
Extremity abscess mimicking Baker's
cyst rupture in a patient with diabetic
ketoacidosis. J Turgut Ozal Med Cent
2016;23(4):471-2.

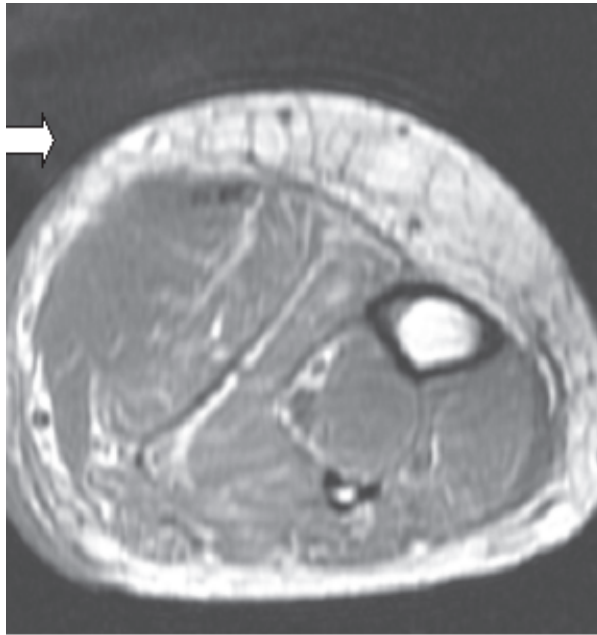


Figure 1. Abscess formation in the middle third area of the left cruris

Here we present a diabetic case with abscess formation in left lower extremity mimicking Baker's cyst rupture. She was fully recovered after abscess aspiration and antibiotherapy. In diabetic patients, many challenging situations may be involved in the differential diagnosis.

Physicians must also take into account rare conditions like abscess formation with common ones.

Rare differential diagnosis such as abscess formation should be considered especially in diabetic patients with muscle and joint complaints.

REFERENCES

1. Schreiber AK, Nones CF, Reis RC, Chichorro JG, Cunha JM. Diabetic neuropathic pain: Physiopathology and treatment. *World J Diabetes* 2015;15;6(3):432-44.
2. Gehling DJ, Lecka-Czernik B, Ebraheim NA. Orthopaedic Complications in Diabetes. *Bone* 2015;23.
3. Gear BJ, Rabinovich A, Brodsky JW. Charcot arthropathy of the foot and ankle associated with rheumatoid arthritis *Foot Ankle Int* 2013;34:1541-7.
4. Jones KB, Maiers-Yelden KA, Marsh JL, Zimmerman MB, Estin M, Saltzman CL. Ankle fractures in patients with diabetes mellitus. *J Bone Joint Surg Br* 2005;87:489-95.
5. Wolfson TS, Hamula MJ, Jazrawi LM. Impact of diabetes mellitus on surgical outcomes in sports medicine *Phys Sportsmed* 2013;41:64-77.
6. Mimata Y, Sato K, Tokunaga K, Tsukimura I, Tada H, Doita M. Diabetic Muscle Infarction of the Tibialis Anterior and Extensor Hallucis Longus Muscles Mimicking the Malignant Soft-Tissue Tumor. *Case Rep Orthop* 2015;2015:656307.
7. Frush TJ, Noyes FR. Baker's Cyst: Diagnostic and Surgical Considerations. *Sports Health* 2015;7(4):359-65
8. Kim JS, Lim SH, Hong BY, Park SY. Ruptured popliteal cyst diagnosed by ultrasound before evaluation for deep vein thrombosis. *Ann Rehabil Med* 2014;38:843-6.