



Glossodynia induced by panitumumab in metastatic colorectal cancer: report of two cases

Metastatik kolorektal kanserde panitumumab'a bağlı dil ağrısı: iki vaka takdimi

Melek Karakurt Eryilmaz¹, Hasan Mutlu¹, Fatma Yalcin Musri¹, Gokhan Tazegul²,
Derya Kivrak Salim¹, Hasan Senol Coskun¹

¹Department of Medical Oncology, Akdeniz University School of Medicine, Antalya, Turkey

²Department of Internal Medicine, Akdeniz University School of Medicine, Antalya, Turkey

Abstract

Colorectal cancer (CRC) is the third most common cancer, and is the third most common cause of death due to cancer in both women and men. Approximately 20 percent of patients with newly diagnosed colon cancer have distant metastatic disease at the time of diagnosis. Panitumumab is a fully human IgG2 monoclonal antibody targeting the epidermal growth factor receptor (EGFR), and it is commonly used to treat metastatic colorectal cancer (mCRC). Combinations of panitumumab plus an irinotecan or oxaliplatin-based regimen are reasonable both first-line and second-line options for mCRC with RAS wild type tumors. However, it has been associated with various side effects such as papulopustular acneiform rash, hypomagnesemia, and diarrhea. No previous reports on patients who developed tongue pain without stomatitis while treatment with panitumumab exists in the literature. Here we report two cases that developed tongue pain while on panitumumab for mCRC.

Keywords: Panitumumab; Tongue Pain; Metastatic Colorectal Cancer.

Öz

Kolorektal kanser en sık üçüncü kanserdir ve hem erkek hem de kadınlarda kansere bağlı ölümün üçüncü en sık sebebidir. Yeni tanı alan hastaların neredeyse %20'sinde tanı anında uzak saha metastazları mevcuttur. Panitumumab tam insan IgG2 monoklonal antikoru olup epidermal büyüme faktörü reseptörünü (EGFR) hedefler, metastatik kolorektal kanser (mKRC) tedavisinde sıklıkla kullanılmaktadır. Panitumumab'ın irinotekan ve oksaliplatin bazlı tedavi rejimleri ile kombinasyonları wild tip RAS tümörlerde hem ilk hem de ikinci basamakta makul seçimlerdir. Bununla birlikte, panitumumab ile papülopüstüler akneiform döküntü, hipomagnezemi ve diyare gibi yan etkiler bildirilmiştir. Daha önce panitumumab ile stomatit olmaksızın dil ağrısı vakası bildirilmemiştir. Bu vakada, mKRC için panitumumab alan iki hastada gelişen dil ağrısı sunulmaktadır.

Anahtar Kelimeler: Panitumumab; Dil Ağrısı; Metastatik Kolorektal Kanseri.

Received/Başvuru: 28.01.2016
Accepted/Kabul: 18.02.2016

Correspondence/İletişim

Gokhan Tazegul
Department of Medical Oncology,
Akdeniz University School of
Medicine, Antalya, Turkey
E-mail: drgtazegul@gmail.com

For citing/Atf için

Eryilmaz MK, Mutlu H, Musri FY,
Tazegul G, Salim DK, Coskun HS.
Glossodynia induced by
panitumumab in metastatic
colorectal cancer: report of two
cases. J Turgut Ozal Med Cent
2016;23(3):331-5.

INTRODUCTION

An estimated 132,700 new cases of colorectal cancer (CRC) are diagnosed annually approximately in the United States, including about 93,090 colon and 39,610 rectal cancers. It is the third most common cancer, and is the third most common cause of death due to cancer in both women and men (1). Approximately 20 percent of patients with newly diagnosed colon cancer have distant metastatic disease at the time of diagnosis. The most common metastatic sites are the regional lymph nodes, liver, lungs, and peritoneum. Surgical resection is the curative modality for localized colon cancer. Most patients with metastatic colorectal cancer (mCRC) are not surgical candidates, and palliative chemotherapy is generally recommended. Five-year survival rate for mCRC has been improved in recent decades (2)

Panitumumab is a fully human IgG2 monoclonal antibody directed against the epidermal growth factor receptor (EGFR). The activation of the EGFR signaling cascade plays an important role in cancer cell proliferation, inhibition of apoptosis, differentiation, adhesion and migration in CRC. In phase 3 trial, panitumumab plus best supportive care (BSC) have shown to provide a statistically significant improvement in progression free survival (PFS) compared with BSC alone in patients with chemo refractory mCRC (3). Combinations of panitumumab plus an irinotecan or oxaliplatin-based regimen are reasonable both first-line and second-line options for mCRC with RAS wild type tumors (4,5). However, various side effects associated with the use of panitumumab have been reported. Skin toxicities, hypomagnesemia, and diarrhea are the most common adverse events in patients treated with panitumumab. In this case, we present the development of tongue pain induced by panitumumab in two patients with mCRC.

CASE REPORT

Case 1

A 62 years old male patient was admitted with a history of 2 years of constipation. He recently started noticing fresh blood during defecation. Patient had chronic inactive hepatitis B for 5 years and had not received any therapy. Family history was unremarkable. He had no history of smoking or alcohol use. Patient stated no other drug use. Physical examination was unremarkable. Blood tests, including CBC, blood chemistry and coagulation tests were normal showed only a normocytic anemia. During colonoscopy a mass was seen on sigmoid colon and biopsy was reported as adenocarcinoma. PET/CT revealed multiple liver metastasis, peripancreatic, paraaortic, aortaintercaval, and mesenteric lymphadenopathies along with primary tumor. Right hemicolectomy was performed due to obstruction and was started on FOLFIRI regimen. After cycle 2, patient's K-RAS, N-RAS and BRAF mutations were reported to be negative. Panitumumab (6 mg/kg, day 1) was added to chemotherapy regimen. After the first administration of panitumumab, patient complained of pain in his tongue. He described it as a stinging sensation all over his tongue and not anywhere else the

mouth, unchanged with eating or drinking. He started feeling this pain after the first day of chemotherapy, and the pain lasted for three days. On physical examination, patient did not have mucositis or stomatitis (Figure 1). Serum vitamin B12 and folic acid levels were within normal limits. Serum zinc level was markedly low (47,94 L; reference range, 72,6-127). Anti-inflammatory therapy only mildly alleviated patient's symptoms. Tongue pain recurred on all 4 cycles of his chemotherapy regimen.

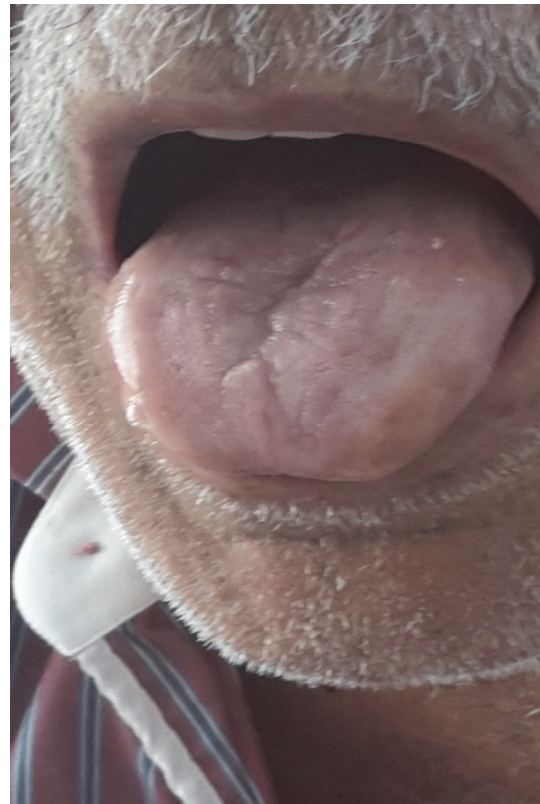

Figure 1. First patient with tongue pain did not have any signs of oral mucosal pathology.

Case 2

A 57 years old male patient was admitted with a history of 2 months of abdominal pain. Patient had type 2 diabetes for 10 years and was on intensive insulin treatment for 4 years. Family history was unremarkable. He had 20 pack years history of smoking. He never drank alcohol. Patient stated no other drug use. Physical examination was unremarkable. Routine blood tests showed only a normocytic anemia. Patient had a workup for chronic blood loss, and during colonoscopy ulcerovegetative obstructive mass was seen on sigmoid colon. Biopsy was consistent with adenocarcinoma. Positron Emission Tomography/Computed Tomography (PET/CT) revealed mesenteric involvement along with multiple bilobular liver metastasis. Patient had surgery (left hemicolectomy) due to obstruction and was started on XELOX-Bevacizumab (capecitabine 2 g/m²/day, 14 days; oxaliplatin 130 mg/m², day 1; bevacizumab 7.5 mg/m², day 1, 21 days per cycle). After cycle 5, PET/CT showed partial response on liver metastases and

mesenteric involvement; however new metastatic foci was found in both lungs. During follow-up, patient's K-RAS, N-RAS and BRAF mutations were reported to be negative. Chemotherapy was switched to "FOLFIRI+ panitumumab" combination regimen (folinic acid 400 mg/m², day 1; 5-fluorouracil 400 mg/m², day 1; and a total dose of 2400 mg/m², infusion for 46 hours; irinotecan 180 mg/m², day 1; panitumumab 6 mg/kg, day 1, 14 days per cycle). During cycle 3 of chemotherapy, patient complained of pain on his tongue. Pain was described as a burning sensation all over his tongue and not anywhere else the mouth, unchanged with eating or drinking. He started feeling this pain after the first day of chemotherapy, and the pain lasted for two days. During his physical examination, patient did not have mucositis or stomatitis (Figure 2). Serum folic acid was within normal limits. Serum zinc (24,04 L; reference range, 72,6-127) and vitamin B12 (166 pg/mL; reference range, 197-866) levels were markedly low (47,94 L; reference range, 72,6-127). Oral anti-inflammatory therapy did not alleviate patient's symptoms. Tongue pain recurred on 2 out of 3 cycles of his chemotherapy regimen.

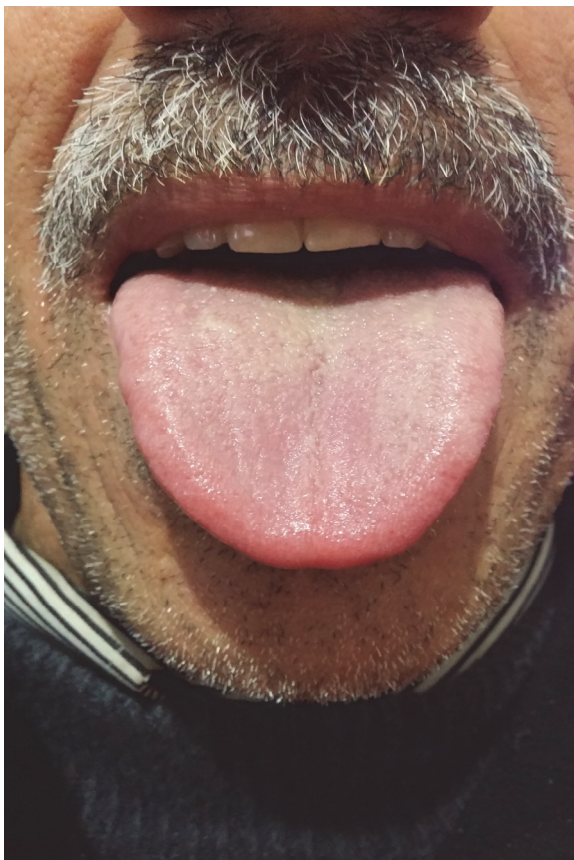


Figure 2. Second patient with tongue pain did not have any signs of oral mucosal pathology.

DISCUSSION

Panitumumab, a fully human monoclonal IgG2 antibody, binds to EGFR and prevents receptor dimerization. In

this way, it inhibits cellular proliferation and tumor growth, and induces apoptosis (6). The most frequent location for RAS mutations in mCRC patients is on KRAS exon 2 (7). Tumors with mutated KRAS are unresponsive to anti-EGFR therapy. Panitumumab when was added to chemotherapy as first-line treatment in the all RAS wild-type mCRC significantly improve PFS and overall survival (OS) (8,9). However, panitumumab has been showed improvement for both PFS and OS in all wild-type RAS mCRC group compared with the wild-type KRAS exon 2 mCRC group (10). Therefore, testing for both KRAS and NRAS mutational status as a negative predictive factor for anti-EGFR therapy for CRC is important routine pathological evaluation. Additionally, BRAF mutations, predominantly V600E, are found in about 5 to 10 percent of mCRC, and are associated with a poor prognosis. The addition of panitumumab to standard therapy in RAS wild type but BRAF mutant patients is not associated with a significant OS and PFS benefit (11).

Overall, panitumumab is well tolerated and toxicities are manageable. The most common panitumumab-related toxicities include dermatologic toxicities (e.g., erythema, dermatitis acneiform, pruritus, skin exfoliation, skin fissures) and non-dermatologic toxicities (e.g., diarrhea, fatigue, nausea, vomiting, neutropenia, hypomagnesemia, dehydration). Rarely, panitumumab has been associated with infusion reactions (4).

Skin-related toxicities occur in 85-90% of patients receiving panitumumab, and are severe (grade 3 and higher) in 15-20% of patients. The most common cutaneous side effect is a diffuse papulopustular acneiform rash. The acneiform rash is often dose-dependent, and usually begins within one week of treatment initiation. The lesions typically occur on the face, trunk, and extremities, sparing the palms and soles. Scaling of the interfollicular skin may also be present. Pruritus and paronychia are other common cutaneous side effects (12). Hypomagnesemia is another common adverse effect. Blood magnesium levels declines due to renal magnesium wasting in 36% of patients receiving panitumumab. Grade 3 or 4 hypomagnesemia requiring magnesium supplementation occurs in 3% of patients (3,13). Hypomagnesemia may lead to secondary hypocalcemia. For this reason, periodic monitoring of serum magnesium and calcium levels should be performed during therapy with panitumumab. Also, panitumumab may lead to a significant increase in the risk of venous thromboembolism but not arterial thromboembolism (14).

No previous reports on patients who developed tongue pain without stomatitis while treatment with panitumumab exists in the literature. Our patients are first reports of panitumumab-related tongue pain. Etiology of tongue pain is multifactorial. The cause may be local (xerostomia, stomatitis, candidiasis, tooth disease, or periodontitis), systemic (pernicious anemia, iron-deficiency anemia, pellagra, arteriosclerosis, or diabetic neuropathy), or psychological (hypochondriasis, depression, or cancer phobia) (15). Mechanism of tongue pain when there are no macroscopic

abnormalities is unknown. In general, these cases are often described as glossodynia. Axonal degenerative and sensory changes in glossal terminal nerve fibres have been demonstrated in glossodynia. Also, trigeminal somatosensory abnormalities have been demonstrated (16). Candidiasis may induce glossodynia without objective clinical manifestation (17,18). Also, deficiency of the serum zinc concentration can lead to glossodynia by causing organic changes such as atrophy and flattening in the lingual papillae (19). Zinc plays an important role for growth and development of the immune response, neurological function, and reproduction. Zinc deficiency may change immune functions and have a significant effect on the development of some diseases including bullous pustular dermatitis, alopecia, diarrhea, emotional disorder, weight loss, intercurrent infections, hypogonadism, neurosensory disorders, and problems with healing of ulcers. In a study, significantly greater thickness of the stratum corneum and epithelium in the middle dorsum of the tongue without gross oral mucosal lesions in the zinc-deficient rats were observed. In the same study, zinc replacement therapy had a greater effect on reducing the mean numerical pain scale in patients with zinc deficiency. However, zinc has not been found to play a definitive role in the etiology of glossodynia (20). Our patients with tongue pain did not have any signs of oral mucosal pathology, such as white lesions, erythema, atrophy, erosion, ulcer, mucositis, or stomatitis but have decreased serum zinc levels. Oral complications resulting from cancer and its therapy can cause both acute (mucositis, saliva changes, taste alterations, infection, bleeding) and late toxicities (mucosal atrophy, xerostomia). Mucositis is the principal manifestation of acute oral toxicity related to chemotherapy, while xerostomia is much less common. 10 to 20 percent of patients treated with agents that target the EGFR such as panitumumab; most cases are mild to moderate severe erosive mucositis that is accompanied by severe pain. All of these complications may cause pain on tongue but our patients had none of these complications.

As a result, this is the first report describing the tongue pain secondary to panitumumab when panitumumab is used in combination with chemotherapy. We believe panitumumab is responsible for the tongue pain in these patients because (a) pain presented after panitumumab was introduced into the regimen (b) pain recurred after and only after consecutive administrations of panitumumab. On case 1, tongue pain only occurred after initiating panitumumab. 5-Fluorouracil accumulation may have caused tongue pain on case 2, however tongue pain occurred after initiating panitumumab; we believe that panitumumab was the main cause of tongue pain. However, since there were no visible oral lesions, We could not hypothesize on the pathogenesis of panitumumab-related tongue pain. Serum zinc and vitamin B12 deficiency may probably contribute to the pathogenesis of tongue pain. Therefore, vitamin B12 and zinc should be replaced in patients with vitamin B12 and serum zinc deficiencies.

REFERENCES

1. Siegel RL, Miller KD, Jemal A. Cancer statistics, 2015. *CA Cancer J Clin* 2015;65(1):5-29.
2. Wolpin BM, Mayer RJ. Systemic treatment of colorectal cancer. *Gastroenterology* 2008;134(5):1296-310.
3. Van Cutsem E, Peeters M, Siena S, Humblet Y, Hendlisz A, Neyns B, et al. Open-label phase III trial of panitumumab plus best supportive care compared with best supportive care alone in patients with chemotherapy-refractory metastatic colorectal cancer. *J Clin Oncol* 2007;25(13):1658-64.
4. Mitchell EP, Piperdi B, Lacouture ME, Shearer H, Iannotti N, Pillai MV et al. The efficacy and safety of panitumumab administered concomitantly with FOLFIRI or Irinotecan in second-line therapy for metastatic colorectal cancer: the secondary analysis from STEPP (Skin Toxicity Evaluation Protocol With Panitumumab) by KRAS status. *Clin Colorectal Cancer* 2011;10(4):333-9.
5. Douillard JY, Siena S, Cassidy J, Tabernero J, Burkes R, Barugel M, et al. Randomized, phase III trial of panitumumab with infusional fluorouracil, leucovorin, and oxaliplatin (FOLFOX4) versus FOLFOX4 alone as first-line treatment in patients with previously untreated metastatic colorectal cancer: the PRIME study. *J Clin Oncol* 2010;28(31):4697-705.
6. Foon KA, Yang XD, Weiner LM, Beldegrun AS, Figlin RA, Crawford J et al. Preclinical and clinical evaluations of ABX-EGF, a fully human anti-epidermal growth factor receptor antibody. *Int J Radiat Oncol Biol Phys* 2004;58(3):984-90.
7. Peeters M, Kafatos G, Taylor A, Gastanaga VM, Oliner KS, Hechmati G et al. Prevalence of RAS mutations and individual variation patterns among patients with metastatic colorectal cancer: A pooled analysis of randomised controlled trials. *Eur J Cancer* 2015;51(13):1704-13.
8. Douillard JY, Siena S, Cassidy J, Tabernero J, Burkes R, Barugel M, et al. Final results from PRIME: randomized phase III study of panitumumab with FOLFOX4 for first-line treatment of metastatic colorectal cancer. *Ann Oncol* 2014;25(7):1346-55.
9. Douillard JY, Oliner KS, Siena S, Tabernero J, Burkes R, Barugel M, et al. Panitumumab-FOLFOX4 treatment and RAS mutations in colorectal cancer. *N Engl J Med* 2013;369(11):1023-34.
10. Peeters M, Oliner KS, Price TJ, Cervantes A, Sobrero AF, Ducreux M, et al. Analysis of KRAS/NRAS Mutations in a Phase 3 Study of Panitumumab With FOLFIRI Compared With FOLFIRI Alone as Second-Line Treatment for Metastatic Colorectal Cancer. *Clin Cancer Res* 2015;21(24):5469-79.
11. Pietrantonio F, Petrelli F, Coinu A, Di Bartolomeo M, Borgonovo K, Maggi C, et al. Predictive role of BRAF mutations in patients with advanced colorectal cancer receiving cetuximab and panitumumab: a meta-analysis. *Eur J Cancer* 2015;51(5):587-94.
12. Bergman H, Walton T, Del Bel R, Seki JT, Rafii A, Xu W, et al. Managing skin toxicities related to panitumumab. *J Am Acad Dermatol* 2014;71(4):754-9.
13. Gibson TB, Ranganathan A, Grothey A. Randomized phase III trial results of panitumumab, a fully human anti-epidermal growth factor receptor monoclonal antibody, in metastatic colorectal cancer. *Clin Colorectal Cancer* 2006;6(1):29-31.
14. Petrelli F, Cabiddu M, Borgonovo K, Barni S. Risk of venous and arterial thromboembolic events associated

- with anti-EGFR agents: a meta-analysis of randomized clinical trials. *Ann Oncol.* 2012;23(7):1672-9.
15. Terai H, Shimahara M. Tongue pain: burning mouth syndrome vs Candida-associated lesion. *Oral Dis* 2007;13(4):440-2.
 16. Mock D, Chugh D. Burning mouth syndrome. *Int J Oral Sci* 2010;2(1):1-4.
 17. Osaki T, Yoneda K, Yamamoto T, Ueta E, Kimura T. Candidiasis may induce glossodynia without objective manifestation. *Am J Med Sci* 2000;319(2):100-5.
 18. Terai H, Shimahara M. Glossodynia from Candida-associated lesions, burning mouth syndrome, or mixed causes. *Pain Med* 2010;11(6):856-60.
 19. Yoshida H, Tsuji K, Sakata T, Nakagawa A, Morita S. Clinical study of tongue pain: Serum zinc, vitamin B12, folic acid, and copper concentrations, and systemic disease. *Br J Oral Maxillofac Surg* 2010;48(6):469-72.
 20. Cho GS, Han MW, Lee B, Roh JL, Choi SH, Cho KJ. Zinc deficiency may be a cause of burning mouth syndrome as zinc replacement therapy has therapeutic effects. *J Oral Pathol Med* 2010;39(9):722-7.