



## Acute pulmonary embolism in a patient with symptomatic coronary artery disease

### Semptomatik koroner arter hastalığı olan bir hastada akut pulmoner embolizm

Necip Ermis<sup>1</sup>, Cem Dogan<sup>2</sup>, Suzan Hatipoglu Akpınar<sup>2</sup>

<sup>1</sup>İnönü University, Faculty of Medicine, Department of Cardiology, Malatya, Turkey

<sup>2</sup>Malatya State Hospital, Cardiology, Malatya, Turkey

#### Abstract

Pulmonary embolism (PE) is a life-threatening emergency that is sometimes difficult to diagnose due to nonspecific symptomatology and laboratory findings. A 65 years old woman who has past stable angina pectoris history was admitted to the our emergency department with severe acute dyspnea and chest pain. The ECG revealed negative T waves in leads V1 through V6 and initial troponin was 16.8 ng/ml and D-dimer 897µg/L. Since these both laboratory and echocardiographic findings and clinical presentation did not let us establish a definite diagnosis, we sent the patient to the catheterization laboratory in order to perform both coronary and pulmonary angiography. We detected severe stenosis of proximal-mid left anterior descending artery and partially occluded left main pulmonary artery by large thrombo-emboli at the catheterization laboratory and treated successfully.

**Keywords:** Coronary Artery Disease; Acute Pulmonary Embolism; Catheterization Laboratory.

#### Öz

Pulmoner embolizm spesifik olmayan semptomatoloji ve laboratuvar bulguları nedeniyle bazen tanı konulması zor olan, yaşamı tehdit eden acil bir durumdur. Stabil angina pectoris öyküsü olan 65 yaşındaki bir kadın, acil servisimize ciddi akut nefes darlığı ve göğüs ağrısı nedeniyle başvurdu. EKG'de V1'den V6'ya kadar T negatifliği saptandı ve ilk troponin değeri 16.8 ng/ml, D-dimer 897µg/L idi. Laboratuvar ve ekokardiyografik bulgular, klinik tablo kesin tanıyı koymada yetersiz kaldığı için hastayı koroner ve pulmoner anjiyografi yapmak maksatlı kateter laboratuvarına gönderdik. Kateter laboratuvarında sol ön inen koroner arter proksimal-orta kısmında ciddi daralma ve sol ana pulmoner arterde geniş bir trombo-emboli nedeniyle kısmi tıkanıklık saptadık ve başarılı bir şekilde tedavi ettik.

**Anahtar Kelimeler:** Koroner Arter Hastalığı; Akut Pulmoner Emboli; Kateter Laboratuvarı.

Received/Başvuru: 25.08.2015  
Accepted/Kabul: 19.10.2015

#### Correspondence/İletişim

Necip Ermis  
İnönü University, Faculty of Medicine,  
Department of Cardiology, Malatya,  
Turkey  
E-mail: necipermis@yahoo.com

#### For citing/Atıf için

Ermis N, Dogan C, Akpınar SH. Acute pulmonary embolism in a patient with symptomatic coronary artery disease. J Turgut Ozal Med Cent 2016;23(2)217-9.

## INTRODUCTION

Acute Pulmonary embolism (APE) is a frequent cardiovascular disease with an overall annual incidence of 100–200 per 100000 inhabitants. APE is also cardiovascular emergency that can result in significant morbidity and mortality for patients (1, 2). As a result, rapid and effective diagnosis is critical. Symptoms of patients include chest or upper back pain, shortness of breath, hemoptysis, unilateral leg pain and feeling of light-headedness or fainting. However, APE may escape prompt diagnosis since its clinical signs and symptoms are generally non-specific. When clinical presentation raises suspicion of APE in an individual patient, it should prompt further objective testing including computed tomography of the thorax, echocardiography, scintigraphic examination or pulmonary angiography.

## CASE REPORT

A 65-year-old female patient was admitted to our emergency department with dyspnea and chest pain. The symptoms had started 4-5 hours ago. She described retrosternal squeezing pain and dyspnea. She had a history of hypertension and diabetes mellitus. Her blood pressure was measured 125/78 mmHg and her pulse was 88 bpm. The ECG revealed negative T waves in leads V1 through V6 (Figure 1).

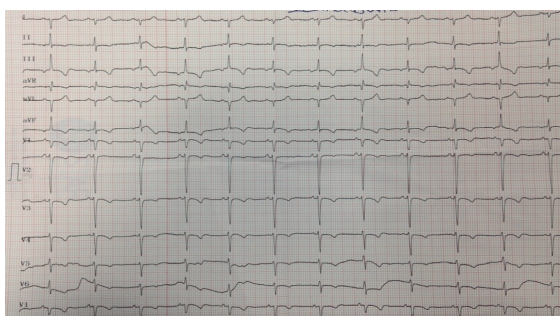


Figure 1. Patient's initial ECG

The initial troponin was 16.8 ng/ml and D-dimer 897 $\mu$ g/L. An echocardiographic examination was undertaken in order to make differential diagnosis between acute coronary syndrome (ACS) and APE. Apical and anterior segmental mild contraction defect, right ventricular (RV) enlargement, ejection fraction (EF) of 52% and systolic pulmonary artery pressure (PABs) of 55 mmHg were detected. Since these echocardiographic findings and clinical presentation did not let us establish a definite diagnosis, we decided to refer the patient to the catheterization laboratory in order to perform both coronary and pulmonary angiography. We observed a proximal-mid left anterior descending artery (LAD) lesion causing approximately 90% stenosis with TIMI-3 flow in coronary angiography (Figure 2) and partially occluded left main pulmonary artery by large emboli in the pulmonary angiography (Figure 3). We concluded that the primary diagnosis for the patient was acute PE. In the coronary care unit, she was treated with unfractionated heparin (UFH) and warfarin. Her

symptoms disappeared in a week and she was discharged with an effective INR level. Following a 3-month anticoagulant treatment, resolution of the emboli in pulmonary artery was observed in the computed tomography (CT) scan. Afterwards, coronary angiography was repeated and it was followed by a successful percutaneous coronary intervention to the LAD lesion (Figure 4).

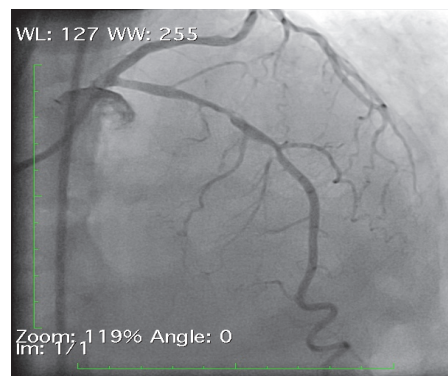


Figure 2. Right anterior oblique view of left coronary system showing 90% stenosis of proximal-mid left anterior descending artery.

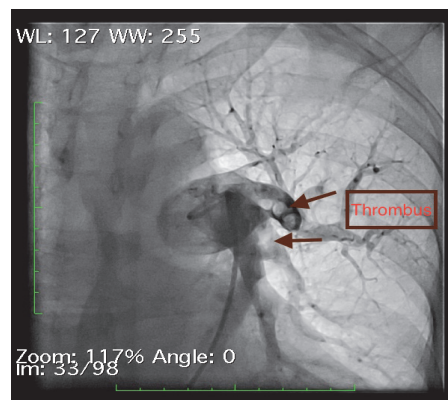


Figure 3. Partially occluded left main pulmonary artery by large emboli in pulmonary angiography.

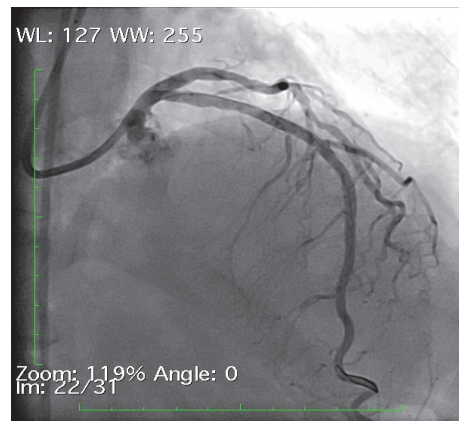


Figure 4. Three month after stenting of left anterior descending artery.

## DISCUSSION

Venous thromboembolism (VTE) encompasses deep vein thrombosis (DVT) and PE and it is the third most frequent cardiovascular disease (1, 2). VTE is a mortal disease in acute phase but it is also preventable (3, 4). Defined as 'the implantation of material into branches of the pulmonary arterial bed,' PE usually consists of clots dislocated from peripheral veins. However, they might also consist of neoplastic cells, fat emboli, amniotic fluid, air bubbles, and other exogenous materials, such as talc, cornstarch particles, or pieces of catheters. Most commonly the clots migrate from deep veins of the pelvis and the lower extremities. The formation of venous thrombosis is usually due to one or more of the following factors: endothelial injury, hypercoagulability, or stasis of blood. The diagnosis of PE is often difficult to establish. PE differs considerably in size and number, and the underlying disorders (e.g. underlying malignancy, trauma, hypercoagulable state resulting from protein C or S deficiency, antithrombin III deficiency, and obesity) are numerous. Thus, the clinical picture of PE is variable, which accounts for the frequent failure to recognize its presentation. Indeed, most emboli are not recognizable on clinical grounds because they are too small to produce cardiorespiratory symptoms and the lung is devoid of pain fibers. Because only the parietal pleura have pain fibers and typical pleuritic pain occurs only when an embolus is complicated by pulmonary infarction. It therefore follows that most instances of PE are clinically silent. The key to diagnose APE is to include it in the differential diagnosis.

Physical examination, history and laboratory tests for the initial evaluation of our patient were not enough to decide between ACS and PE. In our case, we recorded the ECG changes in detail. The initial ECG showed negative T waves in leads V1–6 mimicking an anterior myocardial ischemi in our patient, which made a proper recognition very difficult. The initial ECG had no reciprocal changes in inferior leads. The reasons for the ECG changes including ST segment elevations and inverted T waves in the precordial leads are unclear. (6) In our case, dyspnea that is discordant with the severity of chest pain, risk factors and a history of left leg swelling after a long distance journey led us to think of pulmonary embolism as a possible diagnosis.

Probability of pulmonary embolism was in the intermediate range according to Wells score. Because D-dimer test was positive, according to recent European Society of Cardiology clinical practice guidelines on acute PE, a CT scan was recommended in this patient (1). But acute coronary syndrome could not be excluded and the patient's hemodynamic condition was stable we proceeded with echocardiographic study. Finding both segmental contraction defect and RV dilatation with elevated PABs made the diagnosis more challenging. Since we had a 7/24 active catheterization laboratory and it was possible to proceed with revascularization in

case of ACS, we preferred diagnostic coronary and pulmonary angiography. With this approach, which was also mentioned in the latest ESC guidelines, the patient had the diagnosis of acute PE and coincidental coronary artery disease (5). There is no consensus about the treatment of coincident pulmonary embolism and coronary artery disease. In the literature, there are some case reports but most of them are high-risk patients (patient with hypotension and shock). The coronary lesion is accepted as stable because there was no irregularities and thrombus; also there was TIMI III flow in the LAD. The patient didn't have any angina before this acute situation so we accepted her as a stable coronary artery disease patient. When the coronary anatomy and hemodynamic stability of the patient were considered, conventional therapy for PE followed by elective intervention to LAD was determined as the therapeutic route.

## CONCLUSION

In patients presenting with chest pain and dyspnea, APE should always be included in the differential diagnosis. In such patients, if it is not possible to discriminate between ACS and PE after the initial evaluation, concomitant conventional coronary and pulmonary angiography is a useful option that should be kept in mind. Besides, it is possible to detect concomitant PE and coronary artery disease. In such cases, therapy for the most acute and life-threatening condition should precede.

## REFERENCES

1. Konstantinides SV, Torbicki A, Agnelli G, Danchin N, Fitzmaurice D, Galiè N, et al. 2014 ESC guidelines on the diagnosis and management of acute pulmonary embolism. The task force for the diagnosis and management of acute pulmonary embolism of the European Society of Cardiology (ESC). *Eur Heart J* 2014;35(43):3033-69.
2. Heit JA. The epidemiology of venous thromboembolism in the community. *Arterioscler Thromb Vasc Biol* 2008;28:370-2.
3. Klok FA, van Kralingen KW, van Dijk AP, Heyning FH, Vliegen HW, Kaptein AA, et al. Quality of life in long-term survivors of acute pulmonary embolism. *Chest* 2010;138:1432-40.
4. Condliffe R, Kiely DG, Gibbs JS, Corris PA, Peacock AJ, Jenkins DP, et al. Prognostic and aetiological factors in chronic thromboembolic pulmonary hypertension. *Eur Respir J* 2009;33:332-8.
5. Van Beek EJ, Reekers JA, Batchelor DA, Brandjes DP, Büller HR. Feasibility, safety and clinical utility of angiography in patients with suspected pulmonary embolism. *Eur Radiol* 1996;6:415-9.
6. Vranckx P, Hector H, Heidbuchel H. A case of extensive pulmonary embolism presenting as an acute myocardial infarction – notes on its possible pathophysiology. *Eur J Emer Med* 1998;5:253-8.