



## An unusual presentation of acute pericarditis; a case of transient constrictive pericarditis

### Akut perikarditin nadir bir başvuru şekli: geçici bir konstriktif perikardit vakası

Emrah Acar, Suleyman Barutcu, Aykun Hakgor, Murat Cap, Seyfettin Gurbuz, Cetin Gecmen

Kartal Kosuyolu Cardiovascular Research And Training Hospital, Department of Cardiology, Istanbul, Turkey

#### Abstract

Classic constrictive pericarditis (CP), a progressive and debilitating condition, is characterized by pericardial fibrosis, with or without calcification, which results in chronic refractory congestive heart failure and for which pericardiectomy is often required. Until relatively recently, the development of constrictive physiology was presumed to be irreversible. But transient constrictive pericarditis, which is rare but well known complication of self-limiting acute pericarditis, shares the same clinical features with the chronic form but resolves without surgical intervention. Most of them have resolved without any surgical interventions by administration of non-steroidal anti-inflammatory drugs (NSAID) or steroids. In this report, we present the case of a patient with transient constrictive pericarditis which subsided conservatively.

**Keywords:** Acute Pericarditis; Constrictive Pericarditis; Transthoracic Echocardiography; Computed Tomography; Pericardial Effusion; Non-Steroidal Anti-Inflammatory Drugs.

#### Öz

Klasik konstriktif perikardit; refrakter konjestif kalp yetersizliği semptom ve bulgularına yol açan ve pek çok defa perikardiyektomi gerektiren, perikardiyal fibrozise kalsifikasyonun eşlik ettiği, ilerleyici bir hastalık formudur. Çok yakın bir tarihe kadar konstriktif perikardit vakalarının geriye dönüşü olmayan bir prognoza sahip oldukları düşünülmüştü. Çoğu kendini sınırlayan akut perikardit vakalarında nadir ancak bilinen bir komplikasyonu olan geçici konstriktif perikardit; kronik konstriktif perikardit formundaki vakalarla ortak özellikler göstermektedir ancak kronik formunun aksine cerrahi müdahale olmaksızın düzelme imkanına sahiptirler. Bu olguların pek çoğu cerrahi müdahaleye gerek kalmaksızın non-steroidal antiinflatuar ilaçlar (NSAİİ) ve steroidlerle tedavi edilmiştir. Biz de bu olgu sunumunda konservatif tedavi ile düzelme gösteren bir geçici konstriktif perikardit vakası tartışılmaktadır.

**Anahtar Kelimeler:** Akut Perikardit; Konstriktif Perikardit; Transtorasik Ekokardiyografi; Bilgisayarlı Tomografi; Perikardiyal Effüzyon; Nonsteroidal Antiinflatuar İlaçlar.

Received/Başvuru: 15.09.2015  
Accepted/Kabul: 06.10.2015

#### Correspondence/İletişim

Emrah Acar  
Kartal Kosuyolu Cardiovascular  
Research And Training Hospital,  
Department of Cardiology, Istanbul,  
Turkey  
E-mail: dreacar44@hotmail.com

#### For citing/Atıf için

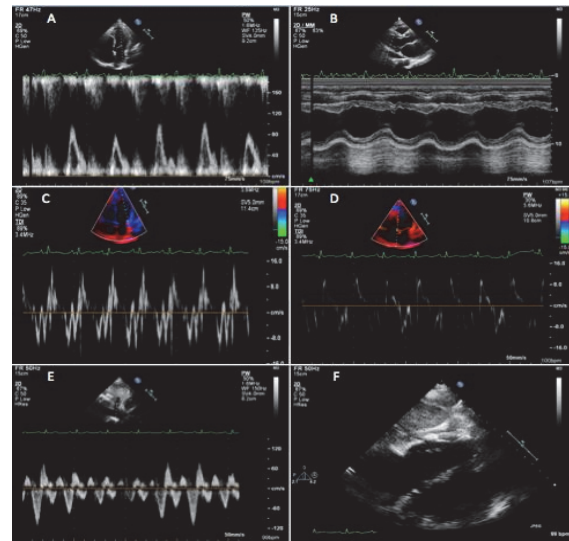
Acar E, Barutcu S, Hakgor A, Cap M, Gubuz S, Gecmen C. An unusual presentation of acute pericarditis; a case of transient constrictive pericarditis. J Turgut Ozal Med Cent 2016;23(2)229-31.

## INTRODUCTION

Constrictive pericarditis is typically a chronic and progressive condition characterised by pericardial thickening and calcification commonly representing a late sequela of pericarditis. This condition traditionally presents with debilitating chronic right heart failure and surgical pericardiectomy remains the treatment of choice (1). In spite of this, the development of constrictive physiology has also been described in the acute phase of pericarditis (2-5) and most of them have resolved without any surgical interventions by administration of non-steroidal anti-inflammatory drugs (NSAID) and steroids.

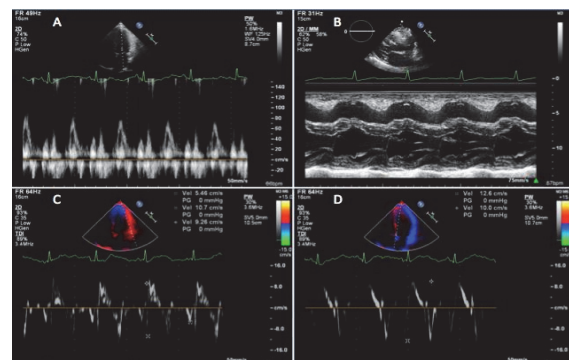
## CASE REPORT

A 28-year-old white man with no significant past medical history was admitted to our clinic. He had sharp chest pain that increased with inspiration and radiated to his left shoulder and neck. The pain had begun three weeks before the presentation. The patient recalled having had an upper respiratory infection that he presumed viral. A review of systems was non-contributory. He denied any unusual exposures. He used tobacco occasionally and denied recreational drug use. On examination, he was afebrile with a blood pressure of 120 mmHg systolic tension and 55 mmHg diastolic tension, pulse rate 110 beat per minute, normal oxygen saturation about 98%. Pulsus paradoxus of 14 mmHg was measured and no jugular venous distention was noted. He appeared to be in moderate distress from the pain and respiratory effect. Cardiac examination revealed faint heart sounds without a pericardial rub or murmurs. Complete blood count showed that white blood cell was  $15,9 \times 10^3/\mu\text{L}$  and C-reactive protein (CRP) was 7,9 mg/dL. Three sets of measurement for cardiac enzymes were negative. The chest radiography revealed moderate cardiomegaly suggestive of pericardial effusion. Electrocardiogram (ECG) showed non-specific signs. Transthoracic echocardiography (TTE) revealed an ejection fraction of about 55-60% and a moderately sized pericardial effusion with no major valvular pathology we noted while significant respiratory variation of mitral and tricuspidal inflow pattern (Figures-1A, B). However, no right atrial and ventricular collapse was seen. We also observed that pericardial thickness was about 10 mm especially over the right ventricular free wall at the subcostal window (Figure-1F). After the initial assessment, we drained the pericardial fluid and laboratory samples were obtained to identify the possible cause. The fluid was transudate. Then we performed a control TTE and revealed constrictive physiology such as septal bouncing, significant respiratory variation in the mitral inflow E wave, annular reversing of the tissue doppler velocities, increased diastolic flow reversal in the hepatic vein on expiration (Figures-1B, C, D, E). For a detailed assessment, we took a chest computed tomography (CT) showing increased pericardial thickness, small pericardial effusion with a minimal pleural counterparting effusion. A diagnosis of acute idiopathic effusive-constrictive pericarditis was established and the treatment with NSAID was initiated.



**Figure-1A.** Mitral inflow pulsed wave doppler velocity variation with respiration, **Figure-1B.** Septal bouncing in diastole on M-Mode, **Figure-1C.** Decreased lateral mitral annular tissue doppler velocity ("annular reversing"), **Figure-1D.** Increased septal mitral annular tissue doppler velocity ("annular reversing"), **Figure-1E.** Increased diastolic flow reversal in the hepatic vein on expiration, **Figure-1F.** On subcostal view; increased pericardial thickness

There was no apparent specific causes. The Montoux, ANA, and viral serologies including HIV, hepatitis, CMV were all negative. After a week of treatment period, clinical signs of pericarditis resolved gradually and control echocardiography showed marked amelioration of the constrictive physiology with lateral tissue doppler velocity dominating the septal velocity. We also found out that inferior vena cavae respiratory variation was increased up to 30% and that there was no pericardial effusion, minimal septal bouncing, nor significant respiratory variation of mitral and tricuspidal inflow velocities (Figures-2A, B, C, D). The patient was discharged. Four weeks later, the follow up TTE showed no pericardial effusion or constrictive physiology.



**Figure-2A.** Normal mitral inflow pulsed wave doppler velocity, **Figure-2B.** Normal septal movement on M-Mode, **Figure-2C.** Normal lateral mitral annular tissue doppler velocity, **Figure-2D.** Normal septal mitral annular tissue doppler velocity

## DISCUSSION

Transient constrictive pericarditis complicating acute pericarditis was first reported by Sagrista-Sauleda et al. in 1987 (2). They described 16 patients from a series of 177 with effusive acute idiopathic pericarditis the constriction features of which were detected in the acute phase. After a mean period of 2,7 months, the observed features spontaneously subsided in these patients. In another series of 36 patients who were diagnosed with transient constrictive pericarditis, viral and idiopathic pericarditis were the most common causes (3). In this study, it has been reported that most of these patients showed resolution of constrictive haemodynamic features without the need for pericardiectomy during the follow-up echocardiographic examinations; over an average of 8 weeks, these patients were treated conservatively with NSAID and steroids for the signs to resolve. A transient form of constrictive pericarditis has also been described in the setting of purulent bacterial pericarditis (4) and chemotherapy (5). Pericardiectomy is the gold standart for the treatment of recurrent or constrictive pericarditis (6). However, in some patients such as our own, constrictive pericarditis may resolve spontaneously or after treatment with anti-inflammatory agents mentioned above. It has been suggested that patients with constrictive features early in the course of illness and those who are haemodynamically stable should be considered for conservative therapy with NSAID administration before pericardiectomy is pursued (6). Our patient recovered with conservative treatment or sequelae.

In summary, our patient with transient constrictive pericarditis following acute pericarditis with effusion was successfully treated with administration of NSAID. Patients who have constrictive features early in the course of illness and those who are haemodynamically stable should be considered for conservative therapy with NSAID administration before pericardiectomy is pursued. Nevertheless, there are few reports of transient constrictive pericarditis and, thus, further investigation is required.

## REFERENCES

1. Sagristà-Sauleda J, Angel J, Sánchez A. Effusive-constrictive pericarditis. *N Engl J Med* 2004;350:469-75.
2. Sagristà-Sauleda J, Permanyer-Miralda G, Candell-Riera J. Transient cardiac constriction: an unrecognized pattern of evolution in effusive acute idiopathic pericarditis. *Am J Cardiol* 1987;59:961-6.
3. Haley JH, Tajik AJ, Danielson GK. Transient constrictive pericarditis: causes and natural history. *J Am Coll Cardiol* 2004;43:271-5.
4. Oh JK, Hatle LK, Mulvagh SL. Transient constrictive pericarditis: diagnosis by two-dimensional Doppler echocardiography. *Mayo Clin Proc* 1993;68:1158-64.
5. Woods T, Vidarsson B, Mosher D. Transient effusiveconstrictive pericarditis due to chemotherapy. *Clin Cardiol* 1999;22:316-8.
6. Lange RA, Hillis LD. Clinical practice: acute pericarditis. *N Engl J Med*. 2004;351:2195-202.
7. Maeda K, Saito S, Toda T, Ueno T, Kuratani T, Sawa Y, et al. Transient Constrictive Pericarditis Following Cardiac Surgery. *Ann Thorac Cardiovasc Surg* 2014;20Suppl:897-900.