



Renal trauma management and current approaches

Böbrek travmalarına güncel yaklaşımlar

Huseyin Celik¹, Ahmet Camtosun¹, Caner Ediz¹, Sukru Gurbuz², Ramazan Altintas¹

¹İnönü University, Turgut Ozal Medical Center, Urology, Malatya, Turkey

²İnönü University, Turgut Ozal Medical Center, Emergency Medicine, Malatya, Turkey

Abstract

Urinary tract injuries happen in approximately 8-10% of all abdominal trauma patients. Kidney is the most frequently injured organ in the urinary tract with penetrating or blunt trauma, and, if not suitable care is carried out, it may lead to morbidity and mortality. The most important laboratory tests are urinalysis, haematocrit and creatinine for evaluating renal trauma. Hematuria is often seen as microscopic or gross, but it is not enough to differentiate the condition between minor and major injuries. The management of kidney trauma has always been and will always be controversial. Conservative (follow-up) and aggressive (surgical) approach both have their proponents. The conservative management of blunt kidney trauma was first suggested in the first half of the 1900s. Since then, it has been reported that the utilities of this approach have become gradually decreased in terms of rate of nephrectomy, complications, and hospital stay. This approach has gained popularity in penetrating kidney trauma cases especially after the 1980s. Nowadays, conservative management is usually favoured, even in the case of grade IV / V traumas. In addition to this, while many studies have shown the conservative approach to be successful, surgical treatment is used only in appropriate cases in grade V injuries. In this survey, relevant articles and guidelines published between 2000 and 2014 have been reviewed, retrospectively. We aim to review the literature and suggest advices regarding conservative and surgical management of renal trauma.

Keywords: Kidney Injury; Renal Trauma; Management; Renal Surgery.

Öz

Üriner sistem yaralanmaları, tüm karın travma hastalarının yaklaşık %8-10'unda meydana gelir. Künt ve delici yaralanmalar ile üriner sistemde en çok böbrek yaralanır ve uygun bir şekilde tedavi edilmediği takdirde ciddi mortalite ve morbiditeye neden olabilir. Renal travma değerlendirilmesi için en önemli laboratuvar testleri idrar tahlili, hematokrit ve kreatinin. Hematüri genellikle mikroskopik veya makroskopik görülür, ancak majör ve minör yaralanmaları ayırt etmek için yeterli değildir. Renal travmalı hastaya yaklaşım hep tartışmalı olmuştur ve tedavide konservatif (izlem) ve agresif (cerrahi) tedaviler önerilmektedir. Konservatif yaklaşım ilk olarak 1900'lü yılların ilk yarısında önerildi. O zamandan buyana nefrektomi oranları, komplikasyon ve hastanede kalış süreleri giderek azaldığı bildirilmiştir. Delici yaralanmalarda ise bu yaklaşım 1980'lerden sonra ivme kazanmıştır. Son yıllarda grade 4 ve 5 travma bile olsa konservatif yaklaşım daha ön plana çıkmıştır. Bir çok çalışmada konservatif yaklaşım başarılı olarak görülmüş ve cerrahi tedavi sadece grade 5 renal travmalı uygun hastalarda uygulanmıştır. Bu yazımızda 2000 ve 2014 arasında yayınlanmış makaleler ve klavuzlar geriye dönük olarak incelendi. Biz bu çalışmada literatürü gözden geçirerek böbrek travmasında konservatif ve cerrahi yönetim ile ilgili genel tavsiyelerde yapmayı hedefledik.

Anahtar Kelimeler: Böbrek Yaralanması; Renal Travma; Yönetim; Böbrek Cerrahisi.

Received/Başvuru: 31.08.2015
Accepted/Kabul: 01.09.2015

Correspondence/İletişim

Huseyin Celik
İnönü University, Turgut Ozal
Medical Center, Urology, Malatya,
Turkey
E-mail: drhuseyin@hotmail.com

For citing/Atf için

Celik H, Camtosun A, Ediz C,
Gurbuz S, Altintas R. Renal trauma
management and current
approaches. J Turgut Ozal Med
Cent 2016;23(2)265-9.

Renal trauma exists in about 1-5% of all trauma cases and renal injury occurs in approximately 8-10% of abdominal traumas (1). Renal injuries are classified according to their mechanism as blunt or penetrating. At most trauma centres, blunt trauma is more common than penetrating trauma. Ninety or ninety-five per cent of kidney injury occurs after blunt trauma (2). Renal trauma generally affects young adult males, and the ethology originates from blunt trauma (3). Both kidneys are at same disposition for injury (4). Blunt renal injuries mechanisms comprise of motor vehicle collision, falls, vehicle-associated pedestrian accidents, assault and sports. Traffic accidents cause almost half of all blunt injuries (5). In a frontal crash, renal injuries may be caused by accelerated hits into the steering wheel or the seat belt itself. In a collateral crash, injuries happen when the vehicle side panel intrudes into the partition and hits the occupant (6). Penetrating renal injuries may be more critical. Especially stab wounds and gunshot are the most common causes of penetrating injuries and tend to be more severe and less presumable than those of blunt trauma. Penetrating injury produces direct tissue disruption of the collecting system, renal parenchyma or vascular tissues (7).

The aim of this review is to illustrate and discuss management of renal trauma. The article also discusses the conditions and procedures that can be applied to treat renal trauma. It should be noted that evidence-

based guidelines help physicians select the best treatment and are considered to be an important method to regulate and optimize medical care.

Based on a meta-analysis, our study is a retrospective review of the literature between 2000 and 2014. The protocol of this review is in accordance with PRISMA checklist (8). Electronic database searches of PUBMED, EMBASE, and SCOPUS were performed using the following keywords: renal trauma; renal trauma management; blunt renal trauma; penetration renal trauma; renal trauma imagines; and renal trauma guidelines.

Renal Trauma

Most renal injuries (90%) are due to blunt trauma causing direct damage (e.g. accidents or crush injuries) or indirect damage causing instantaneous displacement of the kidney (e.g. fall) and penetrating injuries account for the remaining 10% (1). About 40% have been associated intra-abdominal injuries. Direct trauma crushes of kidney against ribs and indirect trauma can result in vascular or pelviureteric disruption.

Two of the most popular approaches are radiologic classification and the AAST grading system for renal injury (9). Commonly used system is that of the American Association for the Surgery of Trauma (AAST) (Table 1) (10).

Table 1. AAST renal injury grading scale

Grade*	Description of injury
1	No laceration.
2	Contusion or non-expanding subcapsular haematoma Non-expanding peri-renal haematoma
3	Cortical laceration < 1 cm deep without extravasation
4	Cortical laceration > 1 cm without urinary extravasation
4	Laceration: through corticomedullary junction into collecting system or Vascular: segmental renal artery or vein injury with contained haematoma, or partial vessel laceration or vessel thrombosis 4a (low-risk cases** are likely to be managed non-operatively)
4	4b (high-risk cases** are likely to benefit from angiographic embolization, repair or nephrectomy)
5	Laceration: shattered kidney or Vascular: renal pedicle or avulsion

*Advance one grade for bilateral injuries up to grade III.

**Peri-renal haematoma, intravascular contrast extravasation, and laceration complexity are the most important radiographic risk factors.

Diagnosis

Clinical examination and further evaluation are essential. Signs of major renal injury include a rapid deceleration event or direct blow to the flank. Patient should be interrogated for a precise medical history. Renal surgery history and known pre-existing renal abnormalities should be recorded. Findings on physical examination, such as, flank pain, flank abrasions, hematuria, abdominal distension or mass, could indicate possible renal involvement. Clinical examination alone is insufficient because patients may change mental status or have other distracting injuries. Hemodynamic stability should be defined upon admission.

The most important laboratory tests are urinalysis, haematocrit and creatinine for evaluating renal trauma. Hematuria is often seen microscopic or gross, but it is not enough to differentiate between minor and major

injuries (11). Serial haematocrit definition and vital signs are used for continuous evaluation of the trauma patient; a decrease in hematocrit is an indirect sign of loss of blood rate and may require operation. Increased creatinine level generally reflects pre-existing renal pathology (12).

Preference of radiographic imaging in cases of suspected renal trauma depends on the mechanism of injury and clinical findings. Indications for radiographic evaluation are gross hematuria, microscopic hematuria with hypotension, or the presence of major combined injuries.

Ultrasonography provides a non-invasive and quick evaluation of detecting peritoneal fluid collections without radiation (13). Ultrasonography scans can define lacerations, but cannot exactly identify their extent or

depth. Functional information about excretion or urine leakage is not provided with ultrasound. But it is useful for the common follow-up of parenchymal lesions or haematomas (11).

Nowadays Contrast-enhanced ultrasound (CEUS) is a very popular diagnostic approach to determine the stage of renal trauma. Contrast enhanced computerized tomography (CECT) is considered to be the best form in diagnosis, but Lin et al. report that no significant differences were observed in the trauma detection rates between CEUS and CECT at grade 3 and 4 renal trauma (14).

Although Intravenous pyelography (IVP) is a sensitive method, it has largely been displaced by CT scanning (15). Function and extravasation are the most findings. Non-function is a sign of pedicle injury in extensive trauma to the kidney. The sensitivity of IVP is high (> 92%) for all degrees of trauma intensity (15, 16).

In renal trauma, Computed tomography (CT) is the best method for evaluation of stable patients. Computed tomography is more specific and sensitive than US, IVP, or angiography, since it exactly defines the location of injuries. Intravenous contrast should be administered for renal assessment (17, 18).

Magnetic resonance imaging (MRI) is not the first imaging option in patients with renal trauma because it takes a longer imaging time and patient access is

limited. When CT is not available or in patients with iodine allergy, MRI is useful in detecting renal trauma (19).

Computed tomography can provide most of the information required about vascular injuries but angiography can be used to describe the area of injury as well as it offers the chance for treatment by embolization. Angiography is indicated mainly for stable patients who are candidates for radiological control of haemorrhage described on CT (17).

Treatment

a) Non-operative management of renal injuries

Non-operative assessment has become the treatment of choice for most renal injuries (18). In stable patients, this means supportive care with observation and bed-rest (20,21).

All grade 1 and 2 renal injuries due to blunt or penetrating trauma can be treated non-operatively (Figure 1). The treatment of grade 3 injuries has been controversial, but ultimate studies support expectant treatment (22). Most patients with grade 4 and 5 injuries present with major associated injuries and these patients are often treated with exploration, sometimes nephrectomy is preferred for treatment (23) although emerging data indicate that many of these patients can be managed safely with an expectant approach (23).

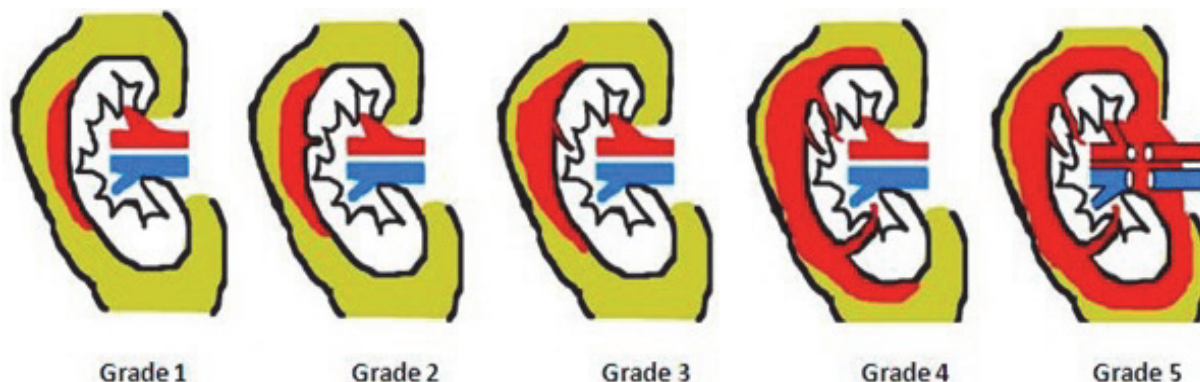


Figure 1. Image of renal injury grading

Penetrating wounds have classically been approached surgically. However, a systematic procedure based on clinical laboratory findings and radiological evaluation minimizes wrong exploration without increasing morbidity from a missed injury (24). Selective non-operative management of abdominal stab wounds is usually accepted by an increasing rate at trauma centres (25). Consistent bleeding represents the main indication for exploration and reconstruction (26). Management of approximately 50% of stab wounds and up to 40% of gunshot wounds of penetrating injuries are curable with non-operative treatment in selected stable patients (27-29).

Super selective transcatheter renal artery remobilization is the treatment option for hemorrhage due to non-iatrogenic blunt renal trauma and low-grade penetrating renal trauma. This method is an effective, minimally invasive therapy for the treatment of renal trauma haemorrhage (30). Also, some studies suggest this method for the treatment of high-grade renal trauma (31).

In children, the main objective of renal trauma treatment is to protect the kidneys. If hemodynamic findings are stable, a conservative approach should be the first preferred process of treatment in every grade of renal trauma in childhood (32).

b) Operative management of renal injuries

The requirement for renal exploration might be predicted considering the type of injury with injury grade, blood urea nitrogen (BUN) and creatinine levels as well as transfusion needs (33). Even so, the assessment of renal injury may be influenced by the decision to explore or follow up associated abdominal injuries (34). Indications for renal exploration contain exploration for associated injuries, expanding or pulsatile peri-renal hematoma identified during laparotomy, grade 5 vascular injury, and hemodynamic instability.

Complications

Renal trauma is an unusual cause of hypertension, generally in young men. The frequency of post-traumatic hypertension is predicted to be <5% in all published series (34, 35). Hypertension may occur as a consequence of external compression from perirenal hematoma or scar formation.

Arteriovenous fistulae (AVF) usually presents with belated onset of significant hematuria, most often after penetrating trauma. Percutaneous embolization is frequently effective for symptomatic AVF (36).

Renal artery pseudo aneurysms are unusual complications of blunt abdominal or back trauma in renal injuries that can cause hypertension. If there is a past history of renal trauma, especially renovascular hypertension patients should be examined carefully in terms of renal artery pseudo aneurysms (37).

Consequently, the goals of treatment of renal injuries include correct staging and minimal complications. Physicians may be avoided in most blunt renal injury cases but there is also a trend towards conservative management of penetrating trauma. Surgical treatment is related to high-grade renal injuries, whereas minor renal injuries may safely be managed conservatively. In other words, medical management and minimally invasive techniques should be the first choice for the management of complications.

REFERENCES

- 1- McAninch JW: Renal injuries. In: Gillenwater JY, Grayhack JT, Howards SS, Duckett JW, eds. Adult and pediatric urology. 3 rd edition. St Louis, Mo Mosby; 1996. P. 539-53.
- 2- Kansas BT, Eddy MJ, Mydlo JH, Uzzo RG. Incidence and management of penetrating renal trauma in patients with multiorgan injury: extended experience at an inner city trauma center. *J Urol* 2004;172:1355-60.
- 3- Voelzke BB, Leddy L. The epidemiology of renal trauma. *Transl Androl Urol* 2014;3:143-9.
- 4- Miller KS, McAninch JW. Radiographic assessment of renal trauma: our 15-year experience. *J Urol*. Aug 1995;154:352-5.
- 5- Santucci RA, Wessells H, Bartsch G, Descotes J, Heyns CF, McAninch JW et al. Evaluation and management of renal injuries: consensus statement of the renal trauma subcommittee. *BJU Int* 2004;93:937-54.
- 6- Kuan JK, Kaufman R, Wright JL, Mock C, Nathens AB, Wessells H et al. Renal injury mechanisms of motor vehicle collisions: analysis of the crash injury research and engineering network data set. *J Urol* 2007;178:935-40.
- 7- Najibi S, Tannast M, Latini JM. Civilian gunshot wounds to the genitourinary tract: incidence, anatomic distribution, associated injuries, and outcomes. *Urology* 2010;76(4):977-81.
- 8- Moher D, Liberati A, Tetzlaff J, Altman DG, and The PRISMA Group, "Methods of systematic reviews and metaanalysis preferred reporting items for systematic reviews and meta-analyses: the PRISMA statement," *J Clin Epidemiol* 2009;62(10):1006-12.
- 9- Kawashima A, Sandler CM, Corl FM, West OC, Tamm EP, Fishman EK et al. Imaging of renal trauma: a comprehensive review. *RadioGraphics*, 2001;21:557-74.
- 10- Moore EE, Shackford SR, Pachter HL, McAninch JW, Browner BD, Champion HR et al. Organ injury scaling: spleen, liver, and kidney. *J Trauma* 1989;29:1664-6.
- 11- Buchberger W, Penz T, Wicke K, Eberle J. Diagnosis and staging of blunt kidney trauma. A comparison of urinalysis, i.v. urography, sonography and computed tomography. *Rofo* 1993;158:507-12.
- 12- Hoke TS, Douglas IS, Klein CL, He Z, Fang W, Thurman JM, Tao Y et al. Acute renal failure after bilateral nephrectomy is associated with cytokine-mediated pulmonary injury. *J Am Soc Nephrol* 2007;18(1):155-64.
- 13- Rippey JC, Roysse AG. Ultrasound in trauma. *Best Pract Res Clin Anaesthesiol* 2009;23:343-62.
- 14- Lin Q, Lv F, Luo Y, Song Q, Xu Q, Su Y et al. Contrast-enhanced ultrasound for evaluation of renal trauma during acute hemorrhagic shock: a canine model. *J Med Ultrasonics* 2015;42:199-205.
- 15- Qin R, Wang P, Qin W, Wang H, Chen B. Diagnosis and treatment of renal trauma in 298 patients. *Chin J Traumatol* 2002;5:21-3.
- 16- Bent C, Iyngkaran T, Power N, Matson M, Hajdinkak T, Buchholz N et al. Urological injuries following trauma. *Clin Radiol* 2008;63:1361-71.
- 17- Kawashima A, Sandler CM, Corl FM, West OC, Tamm EP, Fishman EK et al. Imaging of renal trauma: a comprehensive review. *RadioGraphics* 2001;21:557-74.
- 18- McCombie SP, Thyer I, Corcoran NM, Rowling C, Dyer J, Le Roux A et al. The conservative management of renal trauma: A literature review and practical clinical guideline from Australia and New Zealand. *BJU Int* 2014;14:13-2.
- 19- Leppäniemi A, Lamminen A, Tervahartiala P, Salo J, Haapiainen R, Lehtonen T. MRI and CT in blunt renal trauma: an update. *Semin Ultrasound CT MR* 1997;18:129-35.
- 20- Schmidlin FR, Rohner S, Hadaya K, Iselin CE, Vermeulen B, Khan H et al. The conservative treatment of major kidney injuries. *Ann Urol (Paris)* 1997;31:246-52.
- 21- Bazan AA, Perez S, Bañuelos B, Alonso-Dorrego JM, Diez J, De La Peña J. Incidence and management of isolated renal injury and polytrauma patients. *Archivos Espanoles de Urologia* 2014;67:175-80.
- 22- Alsikafi NF, McAninch JW, Elliott SP, Garcia M. Nonoperative management outcomes of isolated urinary extravasation following renal lacerations due to external trauma. *J Urol* 2006;176:2494-7.
- 23- Santucci RA, McAninch JW. Grade IV renal injuries: evaluation, treatment, and outcome. *World J Surg* 2002;25:1565-72.

- 24- Armenakas NA, Duckett CP, McAninch JW. Indications for nonoperative management of renal stabwounds. *J Urol* 1999;161:768-71.
- 25- Jansen JO, Inaba K, Resnick S, Fraga GP, Starling SV, Rizoli SB et al. Selective non-operative management of abdominal gunshot wounds: survey of practise. *Injury* 2013;44:639-44.
- 26- Buckley JC, McAninch JW. Selective management of isolated and nonisolated grade IV renal injuries. *J Urol* 2006;176:2498-502.
- 27- DuBose J, Inaba K, Teixeira PG, Pepe A, Dunham MB, McKenney M. Selective non-operative management of solid organ injury following abdominal gunshot wounds. *Injury* 2007;38(9):1084-90.
- 28- Shefler A, Gremitzky A, Vainrib M, Tykochinsky G, Shalev M, Richter S et al. The role of nonoperative management of penetrating renal trauma. *Harefuah* 2007;146:345-8.
- 29- Hope WW, Smith ST, Medieros B, Hughes KM, Kotwall CA, Clancy TV. Non-operative management in penetrating abdominal trauma: is it feasible at a Level II trauma center? *J Emerg Med* 2012;43:190-5.
- 30- Rao D, Yu H, Zhu H, Yu K, Hu X, Xie L. Superselective transcatheter renal artery embolization for the treatment of hemorrhage from non-iatrogenic blunt renal trauma: Report of 16 clinical cases. *Ther Clin Risk Manag* 2014;10:455-8.
- 31- Glass AS, Appa AA, Kenfield SA, Bagga HS, Blaschko SD, McGeady JB et al. Selective angioembolization for traumatic renal injuries: A survey on clinician practice *World J of Urol* 2014;32:821-7.
- 32- Piriñçi N, Kaba M, Geçit I, Güneş M, Tanik S, Ceylan K. Conservative approach in the treatment of renal trauma in children. *Urol Int* 2014;2:215-8.
- 33- Shariat SF, Trinh QD, Morey AF, Stage KH, Roehrborn CG, Valiquette L et al. Development of a highly accurate nomogram for prediction of the need for exploration in patients with renal trauma. *J Trauma* 2008;64:1451-8.
- 34- Monstrey SJ, Beerthuisen GI, vander Werken C, Debruyne FM, Goris RJ. Renal trauma and hypertension. *J Trauma* 1989;29:65-70.
- 35- Lebech A, Strange-Vognsen HH. Hypertension following blunt kidney injury. *Ugeskr Leger* 1990;152:994-7.
- 36- Wang KT, Hou CJ, Hsieh JJ, Chou YS, Tsai CH. Late development of renal arteriovenous fistula following gunshot trauma - a case report. *Angiology* 1998;49:415-18.
- 37- Judd E, Lockhart ME, Rizk DV. Renovascular hypertension associated with pseudoaneurysm following blunt trauma. *American J Kidney Dis* 2013;62:839-43.