



## F-18 FDG PET/CT in primary and metastatic pleural involvement

Gul Ege Aktas, Selin Soyluoglu Demir, Ali Sarikaya

Trakya University Medical Faculty, Department of Nuclear Medicine, Edirne, Turkey

### Abstract

**Aim:** The aim was to determine the contribution of FDG PET/CT to differential diagnosis of pleural involvements.

**Material and Methods:** Images of the patients who were referred for PET/CT evaluation with suspicion of mesothelioma were respectively analysed. They were classified according to final histopathologic diagnosis. Involvement patterns, SUVmax of the lesions, mediastinal and extrathoracic lymph node, peritoneum involvement, distant metastasis were evaluated.

**Results:** Findings of 25 patients were analysed. According to final diagnosis; eight patients were mesothelioma, 9 patients were lung cancer, a patient was colon cancer, other 2 patients were diagnosed as renal cell cancer and metastasis of lymphoma. In 5 patients; involvements were inflammatory. SUV max values of inflammatory cases ( $5.6 \pm 2.4$ ) and cases with malign involvement ( $9.1 \pm 2.3$ ) and pleural involvement patterns of benign and malignant cases were significantly different ( $p=0.001$ ,  $p=0.01$ ). SUV max of mesotheliomas, metastatic lesions were not statistically different ( $p=0.367$ ). There were no significant differences between the pleural involvement patterns of pleural mesothelioma and metastatic pleural involvements ( $p=0.14$ ). Mediastinal LAP's were detected in 8 metastatic and in 6 mesothelioma cases. There was not any mediastinal LAP in benign cases. Peritoneal involvement was determined in 8 patients with pleural metastases, in 4 patients with mesothelioma. Bone marrow involvement, chest wall invasion was determined in one each mesothelioma cases. Contralateral lung lesion was determined in 1 metastatic patient. Invasion of chest wall was seen in 2, bone marrow involvement in 1, bone metastasis was detected in 4 patients. Two patients with metastatic involvement had hepatic metastasis, 4 had surrenal metastasis.

**Conclusion:** SUV max values of benign lesions were significantly lower than malign involvements. Involvement patterns could be useful for differentiating benign from malign pleural involvements, when evaluated together with the SUVmax. There was not any difference between mesothelioma and metastatic involvements according to patterns, SUVmax values. PET/CT could determine the thoracic/extra-thoracic primary tumor. This would reduce the burden, cost of diagnostic process. Whole-body evaluation contributes a more accurate staging of malignant cases.

**Keywords:** Pleural Diseases; Mesothelioma; Positron-Emission Tomography; Pleural Neoplasms.

### INTRODUCTION

The most common cause of pleural malignancies is metastasis of adenocarcinomas. Malignant tumors that may metastasize to pleura are lung carcinomas, breast carcinomas, lymphomas and gastrointestinal carcinomas. Metastatic pleural involvement may occur as a result of direct tumor invasion as in lung cancer or hematogenous spread as in breast cancer (1).

Mesothelioma is the most common cause of primary pleural malignancy. Generally the clinical manifestations are chest pain, pleural effusion and dyspnea. Mesothelioma patients are often diagnosed in the late stages of the disease. The median life expectancy after diagnosis is low and reported to be about 12 months

after chemotherapy. Even if the cross-sectional anatomical imaging results are compatible with an initial diagnosis of mesothelioma; a definitive diagnosis should be confirmed by histopathological examination. Imaging techniques are mainly used to determine the extent of the disease, to guide biopsies and to evaluate the response to therapy (2).

After pleural malignancy was suspected on clinical history and x-ray imaging, it is usually evaluated with computed tomography (CT) and Magnetic Resonance Imaging (MRI). Recently Fluorodeoxyglucose Positron Emission Tomography/Computed Tomography (FDG PET/CT) imaging comes into use increasingly. In recent studies FDG PET/CT is suggested as an important modality to evaluate response to therapy, predict prognosis and guide the biopsy region to apply high doses of radiotherapy (3,4).

Some radiological parameters have been suggested in distinguishing between mesothelioma, metastatic pleural involvement and benign pleural changes. However, an adequate level of sensitivity and specificity was not reported (5,6). In this study; we investigated the contribution of FDG PET/CT to the differential diagnosis of pleural involvements; by evaluating involvement

Received: 28.05.2016

Accepted: 02.11.2016

### Corresponding Author

Gül Ege Aktaş

Trakya University Medical Faculty, Department  
of Nuclear Medicine, Edirne, Turkey

E-mail: dr.gulege@yahoo.com

patterns, maximum standard uptake (SUVmax) values of lesions, mediastinal and extrathoracic lymph node involvement, peritoneal involvement and distant metastases.

## MATERIALS and METHODS

In this retrospective study, we evaluated twenty five patients who were referred to PET/CT imaging with suspicion of mesothelioma according to the initial CT evaluations, between January 2010 and June 2014. None of the patients had previously diagnosed or treated.

PET/CT scans were performed on G.E. Discovery STE equipment, in our department. Patients were fasted for 4 hours prior to imaging. Blood glucose levels were measured before the procedure by glucometer (One Touch Select. China) and 296-555 MBq (8-15 mCi) FDG was injected intravenously to the patients with glucose values lower than 180 mg/ml. Patients were advised to stay idle for 60 minutes to accurately monitor the radiopharmaceutical agent bio-dispersion. Subsequent to bladder drainage, each patient was positioned onto supine on a PET/CT monitoring bed. 3D emission and transmission scanning were completed in 30 minutes with average 7-9 bed positions from vertex to thigh. The scope of the monitored regions covered axial, coronal and sagittal plans and 0.6 cm thick sequential cross-section were prepared.

FDG PET/CT images were reevaluated with the knowledge of pre-diagnosis, but aware of the histopathologic final diagnosis. Involvement patterns, SUVmax values of lesions, mediastinal and extrathoracic lymph node involvement, peritoneal involvement and distant metastases were evaluated. Involvement patterns were classified visually into four groups as; diffuse shell, patchy shell, nodular and plaque type. SUVmax values were obtained by drawing regions of interest (ROIs) on cross-sectional images and calculated based on the activity concentration measured at the end of the scan and corrected for patient's body weight and dose injected. Results were evaluated by three experienced

nuclear medicine specialist, as blinded to the histopathologic final diagnosis.

The final diagnoses were established by histopathological examination in all patients: lymph node biopsy in one patient, bone marrow biopsy in one, and pleural biopsy in all of the remaining patients. The findings were classified according to their pathological diagnosis. This study was approved by Trakya University Scientific Research Ethics Committee: date/decision number: 03.18.2015/ 05/07.

## RESULTS

PET/CT results of twenty five patients, aged between 38-82 (mean:  $67.6 \pm 10.9$ ) were examined retrospectively. Eight patients had histopathologic diagnosis of malignant mesothelioma, nine patients had lung cancer, one colon cancer, and the other two were identified as renal cell carcinoma and lymphoma respectively. Five patients were diagnosed as benign chronic inflammatory pathology. SUVmax values of cases with inflammation (mean:  $5.6 \pm 2.4$ ) and cases with malignant involvement ( $9.1 \pm 2.3$ ) were significantly different ( $p=0.001$ ). There were no significant differences between SUVmax values of malignant mesothelioma cases and metastatic pleural disease cases (mean:  $9.1 \pm 2.3$  vs  $10.3 \pm 5.4$ , respectively), ( $p=0.367$ ).

Eight of metastatic patients and 6 of malignant mesothelioma patients had mediastinal lymphadenopathy. No significant differences were found between the SUVmax values of mediastinal lymph nodes ( $p=0.25$ ). Mediastinal lymphadenopathy was not observed in any of the benign cases. Four of malignant mesothelioma cases and eight of metastatic cases had peritoneal involvement. One malignant mesothelioma case had bone marrow involvement, and another case presented chest wall invasion. In the group of pleural metastatic patients; one contralateral lung lesion, two chest wall invasion, one bone marrow involvement, four bone metastases, two liver metastases and four adrenal metastases were determined. Extrathoracic lymph node involvements were also detected in three cases (Table 1).

**Table 1.** Characteristics of cases with mesothelioma, metastatic pleural involvement and benign pleural involvements

	Pleura SUVmax*	MLAP SUVmax*	Extrathoracic LAP (n)	Peritoneum (n)	Chest wall (n)	CL (n)	Surrenal met (n)	Bone met (n)	BM met (n)	Lmet (n)
<b>MM</b>	9.1±2.3	8.6±3.8	-	4	1	-	-	-	1	-
<b>PM</b>	10.3±5.4	11.1±6.4	3	7	2	2	4	4	1	2
<b>B</b>	5.6±2.4	-	-	-	-	-	-	-	-	-

MM: Malign Mesothelioma, PM: Pleural metastasis, B: Benign, MLAP: Mediastinal LAP, CL: Contralateral Lung, BM: Bone marrow, L: Liver Met: Metastasis, N: number of cases

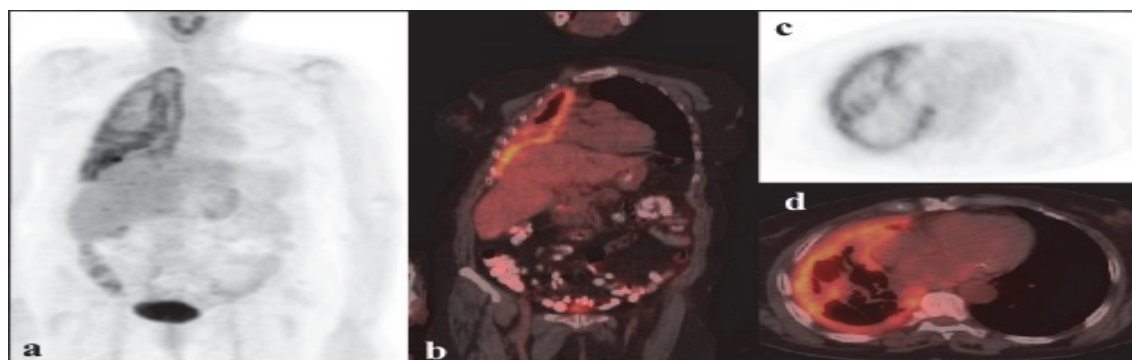
The diffuse shell or patchy shell form of involvements were observed in the majority of malignant pleural involvements (Figure 1,2). Diffuse nodular involvement was detected in one patient with malignant pleural mesothelioma. There were no significant differences between the pleural involvement patterns of pleural mesothelioma and metastatic pleural involvements

( $p=0,14$ ). Only one patient had shell formation, although pathology result was benign. While the only two of malignant cases had plaque style, all the remaining with benign pathology had plaque type of pleural involvements (Table 2) (Figure 3). Pleural involvement patterns of benign and malignant cases were significantly different ( $p=0,01$ ).

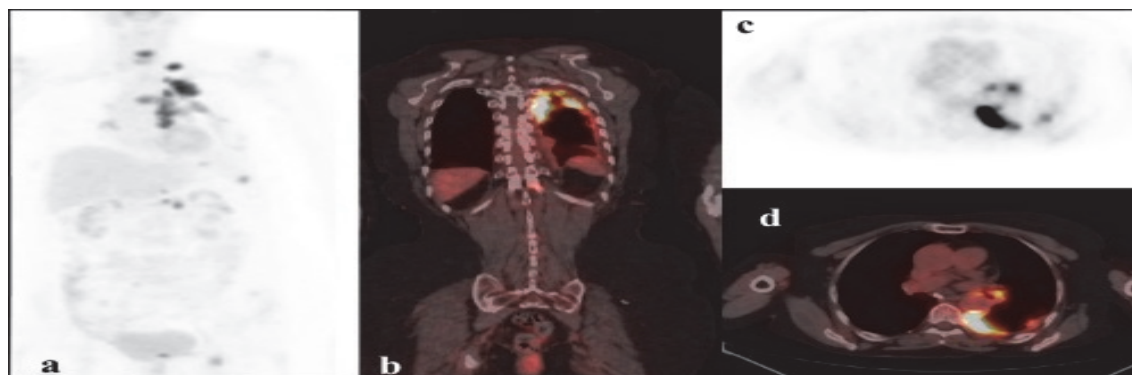
**Table 2.** Patterns of pleural mesothelioma, pleural metastasis and benign pleural involvements

	Shell (n)	Patchy-shell (n)	Shell+ Nodularity (n)	Plaque(n)
MM*	3	4	1	0
PM*	8	2	0	2
B**	0	1	0	4

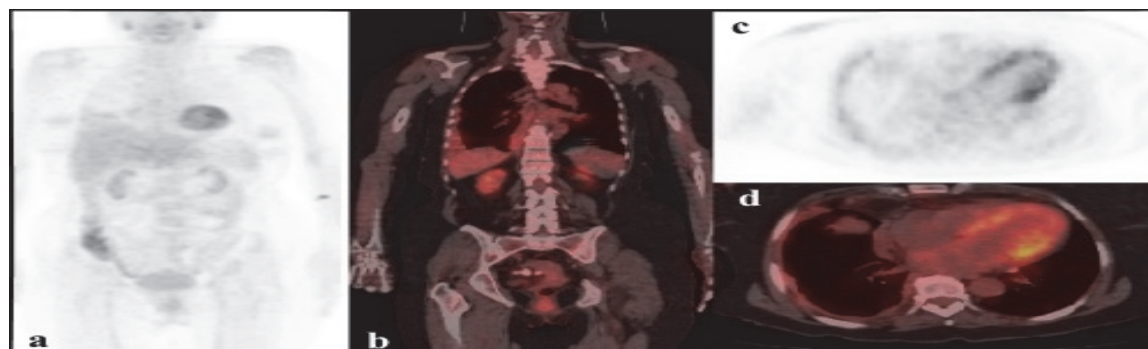
MM: Mesothelioma, PM: Pleural metastasis, B: Benign, n: number of cases, \*:  $\chi^2$ : df=1, p= 0,14, \*\*:  $\chi^2$ : df=1, p=0,01



**Figure 1.** FDG PET/CT images of a 72 year old patient with epithelial and sarcomatoid type malign mesothelioma: On maximum intensity projection image (a) and on coronal fused FDG PET/CT (b) note the diffuse pleural shell formation. It is also clearly seen on axial PET (c) and axial fused PET/CT (d) images. The calculated SUVmax of the pleura was 6.2. There were not peritoneal/or distant metastasis in whole-body evaluation



**Figure 2.** FDG PET/CT images of a 75 year old patient with lung adenocancer: On maximum intensity projection image (a); the shell type of pleural involvement, mediastinal lymph node involvements and bone, left sided surrenal metastasis are shown. The pleural shell formation is seen more clearly in caudal coronal fused FDG PET/CT (b) and lower thoracic vertebral metastatic lesion is also covered. On axial PET (c) and axial fused PET/CT (d) images; posterior pleural thickening, mediastinal LAP's and the pleural nodular lesion where the punch pleural biopsy was conducted are seen. The calculated SUVmax of the pleura was; 11.8. SUVmax of the LAP's were; 10.



**Figure 3.** FDG PET/CT images of a 63 year old patient: On maximum intensity projection image (a), on coronal fused FDG PET/CT (b), axial PET (c) and axial fused PET/CT (d) images; the plaque type of pleural involvement are shown. The calculated SUVmax of the pleura was; 3. There was not mediastinal involvement, distant metastasis or any suspicious lesion in whole-body evaluation of the patient. Pleural biopsy revealed that the pleural lesions were benign and inflammatory.

## DISCUSSION

Pleural diseases are one of the worldwide important causes of mortality and morbidity. They can broadly be split into two sections: neoplastic and infection. Suspected pleural malignancies are evaluated by clinical history, x-ray imaging and further assessed by CT or MRI. FDG PET/CT is gaining importance recently (2).

Most common cause of pleural malignancy is metastasis of adenocarcinoma of other primary sites. The tumors that most frequently metastasize to the pleura are: lung carcinoma, breast carcinoma, lymphoma, and gastrointestinal carcinoma. Unfortunately it is not always easy to determine the primary tumor and it cannot be found in 10% of the cases (1,7). Nine patients final diagnosis were lung cancer, one was determined as colon cancer and the other two were diagnosed as renal cell cancer, lymphoma respectively, in the present study.

It is very important to differentiate benign and malignant pleural involvements because the prognosis and the treatment strategies are different. The prognosis of malignant pleural involvements is low and surgery is generally contraindicated. CT, MR, thoracentesis, biochemical parameters are some of the diagnostic tools that are being used in this manner. But most of them have limitations and some are reasonable invasive (8,9). PET/CT is gaining importance recently and the sensitivity, specificity of PET/CT in differentiating malign and benign lesions of pleura are reported to be variable in the literature (10). Especially SUVmax values of infective lesions and malign involvements cannot always be discriminative (11-13). However FDG affinity is reported to be the most reliable parameter in differentiating the malign pleural involvement (11,12,14). SUVmax values of inflammatory cases ( $5.6 \pm 2.4$ ) and cases with malign involvement ( $9.1 \pm 2.3$ ) were significantly different ( $p=0.001$ ) in our study. We suggest that SUVmax values can reliably differentiate the malign pleural involvements from benign lesions. We did not determine the sensitivity and specificity especially due to the low number of patients with benign pleural involvements in our study.

Mesothelioma is the most frequent malignancy of pleura. Pleural effusions and dyspnea are the frequent sign, symptoms of the patients presenting with mesothelioma. Long lasting asbestosis exposure is determined to be a well-defined cause of mesothelioma. Patients with mesothelioma are usually diagnosed lately and the prognosis is very low following the initial diagnosis (2). Eight patients' final diagnoses were mesothelioma, 12 patients were metastasis of other adenocarcinomas and in 5 patients involvements were inflammatory, in our study.

Although cross-sectional imaging may be suggestive of mesothelioma, histological biopsy is required to determine the final diagnosis. Imaging is mainly used for evaluating the disease extent, guiding biopsy, and following up the therapy response (2). Recently, PET/CT is suggested to be an important tool in predicting both prognosis and response to chemo- therapy and in

selection of the regions to be delivered high dose radiotherapy (3,4).

The widely excepted staging system of mesothelioma is the system of International Mesothelioma Interest Group suggested in 1995. T1 disease is restricted in pleura and T2 disease spreads to the diaphragm. T3 mesothelioma spreads further; diaphragm, mediastinum and one side of the endothoracic fascia are involved. Pericardium can also be invaded. T4 disease include diffuse or multifocal chest wall invasion, invasion of rib, spine, brachial plexus, or mediastinal organs, invasion through the diaphragm and peritoneum. Also contralateral pleural involvement and malign pericardial effusion are covered in T4 mesothelioma (15). T3 tumor is expected to be operable, but T4 is an inoperable tumor sage. Lymph node staging (N) is as the same as lung cancer and it is consistent with visceral pleural lymphatic drainage pathways. An important finding can be the involvement of atypical lymph node stations like subpleural and cardiophrenic stations which parietal pleura drains (2).

Thoracoscopy is still the gold standard method for evaluation of the local invasion of mesothelioma. PET/CT is useful in predicting the thoroscopic findings of mesotheliomas, but the correlations are reported to be moderate. However, PET/CT is suggested to be an important modality in prediction of thoroscopic findings related to the prognosis, in staging, follow-up and assessing the response to the therapy: A significant relationship has been determined between SUVmax values and visceral pleural involvement, presence of nodule formation. The cases with higher SUVmax values are suggested to be more likely to have nodular pleural lesions and visceral pleural involvement (16). Nodular pleural involvement pattern was detected in only one case in our study: The final histopathologic diagnosis was confirmed as mesothelioma and the SUVmax of the pleura was considerably high (SUVmax: 12.3) compared to our series. Mediastinal lymph node involvement, peritoneal dissemination and bone marrow metastasis were detected in this patient.

Although, distant metastasis was accepted to be rare in mesothelioma previously, it is reported to be more frequent with the widely use of modern cross-sectional imaging modalities. The most common reported sites are; bone, liver and lungs (2,17). In our study: Bone marrow involvement, chest wall invasion was determined in one each mesothelioma cases. But in metastatic pleural involvements from other primary tumors; contralateral lung lesion was determined in 1 patient, invasion of chest wall was seen in 2, bone marrow involvement in 1, bone metastasis was detected in 4 patients. Two patients with metastatic involvement had hepatic metastasis, 4 patients had surrenal metastasis (Table 1). Duysinx et al suggested PET as a guiding method in determining the primary tumour that is thoracic or extrathoracic (10). This would reduce the extra burden and cost of diagnostic process: Because currently there is no consensus on the any single modality which should be used to confirm diagnosis prior to surgery. Recently a meta-analysis suggested that PET-CT is superior to MRI and CT in terms of specificity and sensitivity of disease detection and staging (18).



However, surgical pleural biopsy is still reported to be the most accurate definitive diagnosis; but it is a more invasive procedure than PET-CT. Unexpected distant metastases indicated a primary tumor other than mesothelioma of the pleura in the present study; and whole-body evaluation contributed determining inoperable cases and more accurate dissemination of malignant disease.

Various radiological findings have been suggested in differentiating benign and malign pleural involvements, mesotheliomas and metastatic pleural lesions: In particular, the most frequent diagnostic problem is the differentiation of mesothelioma and adenocarcinoma. Often additional immunohistochemical studies are needed to establish the final diagnosis as mesothelioma in this manner and sometimes radiologic differential diagnosis may be required for the judgment of compensation (19). The CT features that are suggested in the differential diagnosis of malignant and benign pleural involvements are; 1) circumferential pleural thickening, 2) nodular pleural thickening, 3) pleural thickening > 10 mm, and 4) mediastinal pleural involvement (5,20). Although these findings are frequently seen in mesothelioma, they are not characteristic. To the best of our knowledge, there are only a few studies investigating the difference of CT features of malignant pleural mesothelioma and metastatic pleural disease (5,21,22): Metintas et al, have suggested that pleural shell formation, pleural thickness over 1cm could differentiate mesothelioma and metastatic pleural involvement. They determined that the sensitivity and specificity of these patterns were; 70/85, 85/67 and 59/82%, respectively. They have also suggested that, mediastinal pleural involvement and nodularity of pleural involvement were the most determining findings with the sensitivity and specificity of 54/95, 70/83 and 38/96%, respectively (5). Kim et al concluded that, circumferential pleural thickening, fissural pleural thickening, diaphragmatic pleural thickening, pericardial involvement, and the presence of a pleural mass and pleural plaque were frequent CT findings suggesting mesothelioma, whereas nodular pleural thickening, hilar lymph node enlargement, mediastinal lymph node enlargement, and hematogenous lung metastasis were significantly suggestive of metastatic pleural involvements (20). Eight of metastatic patients and 6 of malignant mesothelioma patients had mediastinal lymphadenopathy. No significant differences were found between the SUVmax values of mediastinal lymph nodes ( $p=0.25$ ) in our study. So, mediastinal lymphadenopathy was not a significant criterion in differentiating mesothelioma and metastatic pleural involvements in this study. But; Mediastinal lymphadenopathy was not observed in any of the benign cases; so, we suggest that presence of mediastinal lymphadenopathy is suggestive of a malignant pleural involvement. The reason for this discordance in both results might be due to low number of patients in our study. The shell formation or circumferential pleural thickening was also a significant criterion for differentiating benign and malign pleural disease in our study. Only 1 patient with benign inflammatory involvement of the pleura had patchy pleural shell

formation in our study. None of the benign cases had mediastinal lymph node involvement. SUVmax values of inflammatory cases ( $5.6\pm 2.4$ ) were significantly lower than the malign ( $9.1\pm 2.3$ ) involvements ( $p=0.001$ ). We suggest that, low SUVmax values, absence of mediastinal lymphadenopathies and lesions in form of plaques evaluated together could differentiate benign lesions from malignant involvements. On the other hand, there were no differences between the SUVmax values ( $9.1\pm 2.3$  vs  $10.3\pm 5.4$ ), pleural involvement patterns between mesotheliomas and metastatic pleural involvements. In both patient populations, we could not determine any difference in mediastinal involvements, lymphadenopathies and peritoneal dissemination. There was not any significant difference between the SUVmax values of mediastinal lymph nodes ( $p=0.25$ ). Distant metastases were noteworthy in cases with metastatic pleural involvements from other primary tumors. On the other hand, bone marrow involvement, chest wall invasion was determined in only one each mesothelioma cases. Although the other radiological parameters (CT findings) were not evaluated in this study due to low number of patients and the study design; we suggest that well controlled prospective studies evaluating the high-resolution CT characteristics together with FDG PET/CT findings, particularly SUVmax of the lesions and whole-body contributions, are needed in the manner of differentiating pleural mesothelioma from malign metastatic pleural involvements.

Taken as a whole, there was not any difference between mesothelioma and metastatic involvements according to pleural involvement patterns, mediastinal lymph node involvements and SUVmax values. Distant metastases were noteworthy in metastatic pleural involvements of primary tumor other than mesothelioma. SUVmax values of benign lesions were significantly lower than malign involvements. Malign pleural involvements were mostly in type of shell formation, while benign pleural lesions were mostly in the form of pleural plaques. Involvement patterns were useful in differentiating benign, malign pleural involvements, when evaluated together with the SUVmax. Although the final diagnosis should be determined with histopathologic evaluation, PET/CT was useful in indicating another primary than mesothelioma when whole-body disease distribution was taken into account, in guiding the biopsy sites and in determining a more accurate stage of the diseases which affected the therapy selection.

## CONCLUSION

SUVmax values of benign lesions were significantly lower than malign pleural involvements. Involvement patterns were useful in differentiating benign, malign pleural involvements, when evaluated together with the SUVmax. There was not any difference between mesothelioma and metastatic involvements according to pleural involvement patterns, mediastinal lymph node involvements and SUVmax values. Unexpected distant metastases indicated a primary tumor other than mesothelioma of the pleura in the present study: PET/CT could determine the thoracic/extrathoracic primary tumor. This would reduce the burden, cost of diagnostic

process. Whole-body evaluation contributes determining more accurate stage of malignant cases.

## REFERENCES

1. Antunes G, Neville E, Duffy J, Ali N. BTS guidelines for the management of malignant pleural effusions. *Thorax* 2003;58(Suppl 2):ii29–ii38.
2. Helm EJ, Matin TN, Gleeson FV. Imaging of the pleura. *J Magn Reson Imaging* 2010;32(6):1275-86.
3. Fuccio C, Spinapoliche EG, Ferretti A, Castellucci P, Marzola MC, Trifirò G, et al.  $^{18}\text{F}$ -FDG-PET/CT in malignant mesothelioma. *Biomed Pharmacother* 2013;67(6):539-42.
4. Flores RM, Akhurst T, Gonen M, Zakowski M, Dycoco J, Larson SM, et al. Positron emission tomography predicts survival in malignant pleural mesothelioma. *J Thorac Cardiovasc Surg* 2006;132(4):763-8.
5. Metintas M, Ucgun I, Elbek O, Erginel S, Metintas S, Kolsuz M, et al. Computed tomography features in malignant pleural mesothelioma and other commonly seen pleural diseases. *Eur J Radiol* 2002;41(1):1-9.
6. Hierholzer J, Luo L, Bittner RC, Stroszczyński C, Schröder RJ, Schoenfeld N, et al. MRI and CT in the differential diagnosis of pleural disease. *Chest* 2000;118(3):604-9.
7. Sahn S. Malignant pleural effusions. *Eur Respir monograph* 2002;22:177-88.
8. Doelken P. Management of pleural effusion in the cancer patient. *Semin Respir Crit Care Med* 2010;31(6):734-42.
9. Murthy SC, Rice TW. Surgical management of malignant pleural effusions. *Thorac Surg Clin* 2013;23(1):43-9.
10. Duysinx B, Corhay JL, Larock MP, Withofs N, Bury T, hustinx R, et al. Contribution of positron emission tomography in pleural disease. *Rev Mal Respir* 2010;27(8):e47-53.
11. Toaff JS, Metser U, Gottfried M, Gur O, Deeb ME, Lievshitz G, et al. Differentiation between malignant and benign pleural effusion in patients with extra-pleural primary malignancies: assessment with positron emission tomography-computed tomography. *Invest Radiol* 2005;40(4):204-9.
12. Kim BS, Kim IJ, Kim SJ, Pak K, Kim K. Predictive value of F-18 FDG PET/CT for malignant pleural effusion in non-small cell lung cancer patients. *Onkologie* 2011;34(6):298-303.
13. Alkhalwaleh K, Biersack HJ, Henke A, Ezziddin S. Impact of dual-time-point F-18 FDG PET/CT in the assessment of pleural effusion in patients with non-small-cell lung cancer. *Clin Nucl Med* 2011;36(6):423-8.
14. Letovanec I, Allenbach G, Mihaescu A, Nicod Lalonde M, Schmidt S, Stupp R, et al.  $^{18}\text{F}$ -fluorodeoxyglucose PET/CT findings in pleural effusions of patients with known cancer: a cytopathological correlation. *Nuklearmedizin* 2012;51(5):186-93.
15. Rusch VW. A proposed new international TNM staging system for malignant pleural mesothelioma. From the International Mesothelioma Interest Group. *Chest* 1995;108(4):1122-8.
16. Pinelli V, Roca E, Lucchini S, Laroumagne S, Loundou A, Dutau H, et al. Positron Emission Tomography/Computed Tomography for the Pleural Staging of Malignant Pleural Mesothelioma: How Accurate Is It? *Respiration* 2015;89(6):558-64.
17. Truong MT, Marom EM, Erasmus JJ. Preoperative evaluation of patients with malignant pleural mesothelioma: role of integrated CT-PET imaging. *J Thorac Imaging* 2006;21(2):146–53.
18. Zahid I, Sharif S, Routledge T, Scarci M. What is the best way to diagnose and stage malignant pleural mesothelioma? *Interact Cardiovasc Thorac Surg* 2011;12(2):254-9.
19. Robinson BW, Lake RA. Advances in malignant mesothelioma. *N Engl J Med* 2005;353(15):1591-603.
20. Leung AN, Müller NL, Miller RR. CT in differential diagnosis of diffuse pleural disease. *AJR Am J Roentgenol* 1990;154(3):487-92.
21. Kim YK, Kim JS, Lee KW, Yi CA, Koo JM, Jung SH. Multidetector CT Findings and Differential Diagnoses of Malignant Pleural Mesothelioma and Metastatic Pleural Diseases in Korea. *Korean J Radiol* 2016;17(4):545-53.
22. Bakhshayesh Karam M, Karimi S, Mosadegh L, Chaibakhsh S. Malignant Mesothelioma Versus Metastatic Carcinoma of the Pleura: A CT Challenge. *Iran J Radiol* 2016;13(1)e10949.