

Trial of dimethyl sulfoxide on systemic tissue damage due to kerosene ingestion

Yrd.Doç.Dr.Ünsal ÖZGEN*, Prof.Dr.N.Engin AYDIN**, Öğr.Gör.Dr.Mustafa ERBİLEN***,
Araş.Gör.Dr.Sabit ŞAHİN*, Araş.Gör.Dr.İ.Öğuz TURHAN**

Oxygen-derived free radicals promote tissue injury by cumulating in ischemic sites, and it was previously reported that hypoxic tissue lesions occur secondarily to chemical pneumonia following hydrocarbon intoxication. Dimethyl sulfoxide (DMSO) can reduce tissue damage in gastrointestinal system by its radical removing effect, but it is not known whether it is effective similarly in other systems. From this point of view, 30 rabbits were divided equally into three groups, and kerosene and DMSO were instilled into the stomach of the first group through an orogastric tube. The second group received only kerosene and the third group received only DMSO by the same way as the first group. At the end of 48 hours rabbits were sacrificed and organs were examined histologically. Statistical analysis revealed a non-significant difference between the first and second group ($p > 0.05$) and there was no pathological lesion in the third group. As a conclusion, DMSO is ineffective in reducing hypoxic tissue damage secondary to chemical pneumonia. [Journal of Turgut Özal Medical Center 1(1):7-9,1994]

Key Words: Kerosene ingestion, dimethyl sulfoxide, ischemic injury

Gaz yağı alımına bağlı sistemik doku hasarına karşı dimetil sülfoksidin etkisinin incelenmesi

İskemik dokularda serbest oksijen radikallerinin biriktiği, doku hasarını artırdığı ve hidrokarbon zehirlenmelerinde sık görülen kimyasal pnömoniye sekonder hipoksik doku lezyonlarının oluştuğu bilinmektedir. Radikal temizleyici etkisi ile doku hasarını azalttığı gastrointestinal sistem lezyonlarında gösterilen dimetil sülfoksit'in (DMSO) benzer etkisinin diğer sistemlerde de etkili olup olmadığı bilinmemektedir. Konuya açıklık getirmek amacıyla 10' ar adetlik üç gruba ayırdığımız tavşanlarda orogastrik tüp ile 1. gruba gaz yağı ve DMSO, 2. gruba gaz yağı, 3. gruba DMSO verildikten sonra 48. saatte denekler öldürüldü. Histopatolojik lezyonların gruplara dağılımı istatistiksel olarak değerlendirildiğinde grup 1 ve grup 2 arasında anlamlı fark bulunamazken grup 3 deki hiç bir denekte patolojik lezyon gözlenmedi. Bulgularımız kimyasal pnömoniye sekonder hipoksik doku hasarını azaltmada DMSO nun etkisiz olduğu yönündedir. [Turgut Özal Tıp Merkezi Dergisi 1(1):7-9,1994]

Anahtar Kelimeler: Gaz yağı alımı, dimetil sülfoksit, iskemik zedelenme

* : İnönü Ün.Tıp Fakültesi Çocuk Sağlığı ve Hastalıkları Anabilim Dalı - Malatya

** : İnönü Ün.Tıp Fakültesi Patoloji Anabilim Dalı - Malatya

*** : İnönü Ün.Tıp Fakültesi Genel Cerrahi Anabilim Dalı - Malatya

It is known that tissue ischemia leads to the accumulation of oxygen derived free radicals which promote tissue injury^{1,2}. Dimethyl sulfoxide (DMSO), has been shown to reduce ischemic damage due to its radical removing effect in the gastrointestinal system²⁻⁴. Free radical levels increase in the liver and lung after ischemia⁵. The most life-threatening complication of hydrocarbon intoxication, especially in 1-5 age group, is chemical pneumonia and almost all of the tissue suffer from hypoxia secondary to this condition⁶⁻⁸. There is no satisfactory data in the literature about systemic damage reducing effect of DMSO. In this study, we aimed to determine the effect of DMSO on chemical pneumonia and hypoxic tissue damage secondary to kerosene ingestion.

MATERIALS AND METHODS

Thirty Chinchilla rabbits of either sex, 16-22 weeks of age and weighing 720-900 g were used in this study. Rabbits were grouped in three randomly with 10 in each. After an 8 hour fasting period 20 ml/kg kerosene and 10 ml/kg 5 % DMSO were instilled into the stomach of the first group through an orogastric tube. Second group received 20 ml/kg kerosene and the control group received 20 ml/kg 2.5 % DMSO by the same route. At the end of 48 hours the rabbits were sacrificed under penthotal anaesthesia. All organs were removed for histopathological examination. After overnight fixation in buffered 10 % formalin representative sections from various organs were processed routinely for paraffin embedding. 5-6 µ sections were stained by hematoxyline and eosin, van Gieson's picrofuchsin, and periodic acid- Schiff method. Histopathological examinations were made by two pathologists independently.

Fischer's exact test was used for statistical analysis.

RESULTS

All rabbits, except one in the second group which died after 48 hours, survived the experimental period. No significant difference was observed between the groups due to mortality (p > 0.05).

The results are presented in Table I and Figure 1. The most prominent lesions observed in the experimental

groups were in the lungs. These were fresh hemorrhage, hemorrhagic infarction and dilatation of distal airways. These were all focal lesions observed in both lung fields. One rabbit in each experiment group showed multiple pulmonary infiltrations involving peribronchial areas. Brain edema was observed in a significant number in both groups. The congestion in the kidneys were not accompanied with any other change. The sections from the gastrointestinal tract did not reveal any remarkable change. The statistical analysis of the pathological findings were not statistically significant (p > 0.05). The control group was free from the lesions depicted above.

DISCUSSION

The application of kerosene in our experimental model has not yielded a significant mortality in a 48 hour period. However, the pathological changes observed in the lungs, brain and minor changes in the kidneys could be taken into account as an intoxication model due to ingestion of kerosene with this rodent species. We could not observe a corrosive effect after 48 hours in both experimental groups. All other changes are to be taken as a systemic effect of hydrocarbon intoxication.

In order to decrease the damage due to free radicals in ischemic tissue, studies were focused on DMSO and allopurinol²⁻⁴. The effected organs from hypoxia secondary to chemical pneumonia which is the major complication of hydrocarbon ingestion, were found to be brain and kidney⁵. It was previously demonstrated that DMSO could reduce lesions in the gastrointestinal tractus which was effected directly by hydrocarbon and hydrocarbon-like corrosive substances^{3,4,9}. However, amounts of free radical formation in brain, lungs and kidneys during hydrocarbon intoxication and the possible systemic effects of DMSO on tissue damage are not known. As shown in previous studies with DMSO in the gastrointestinal tractus a systemic effect of this compound on reducing tissue injury could be expected²⁻⁴. However, our results did not reveal such an effect. Further studies about the interaction between DMSO and free radicals are needed to understand why DMSO has not yielded for detailed effects in this experimental model. In this context, the application of DMSO in kerosene intoxication does not seem advisable.

Table I. Histopathological findings in groups.

	LUNGS				BRAIN		KIDNEYS
	Hemorrhage	Infarction	Infiltration	D.D.A.*	Congestion	Edema	Congestion
Group 1	4	2	1	2	0	2	3
Group 2	5	3	1	1	1	3	4
Group 3	0	0	0	0	0	0	0

* Dilatation of distal airway (p > 0.05)

Figure 1. Diagrammatic distribution of the lesions.

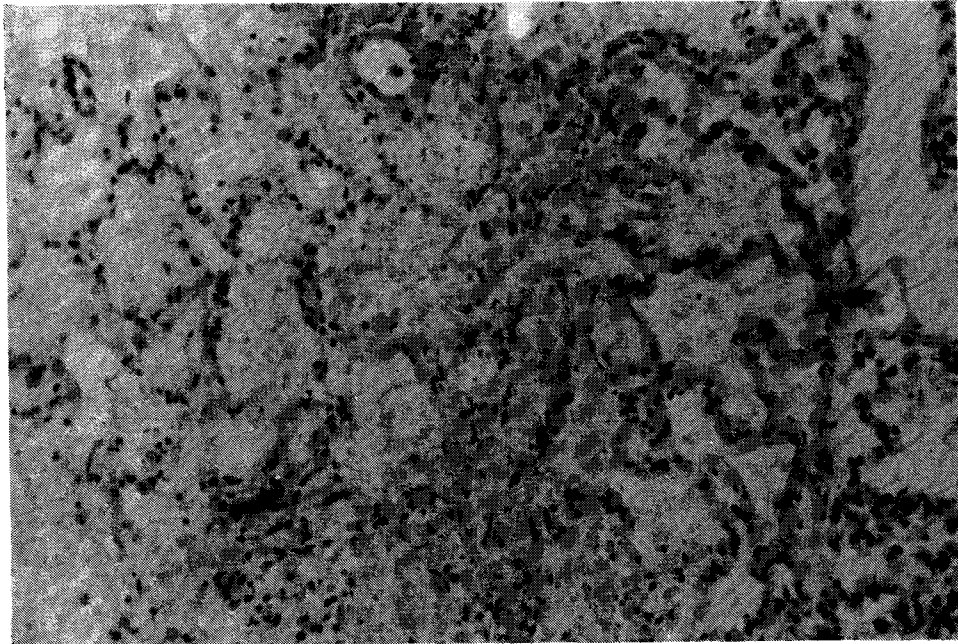
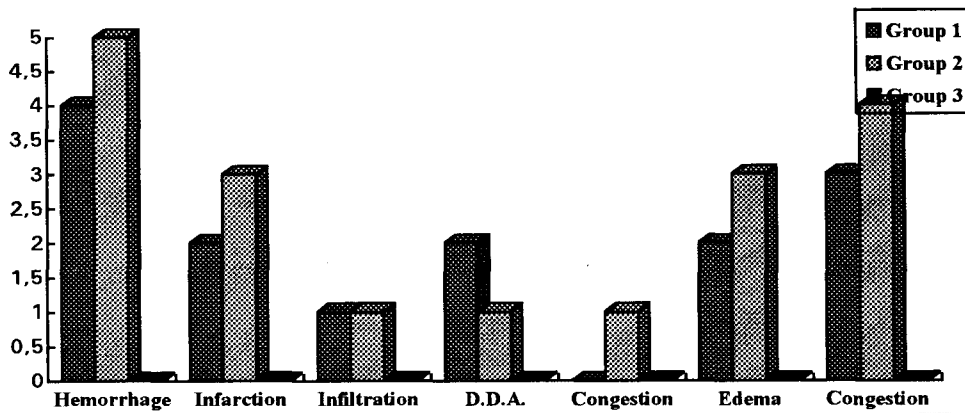


Figure 2 : Lesion defined as infarction with erythrocyte extravasation and necrosis of alveolar septa (H. E. x 400).

REFERENCES

1. Mc Cord JM. Oxygen-derived free radicals in post ischemic tissue injury. *New Eng J Med* 1985; 312: 159-65.
2. Salim AS. Role of oxygen-derived free radicals in the mechanism of chronic gastric ulceration in the rat: Implications of cytoprotection. *Digestion* 1989; 43: 113-9.
3. Salim AS. Removing oxygen-derived free radicals stimulates healing of ethanol-induced erosive gastritis in the rat. *Digestion* 1990; 47:24-8.
4. Coşkun İ, Uzunköy A, İrfanoğlu ME. Ratlarda akut eroziv gastritte dimetil sulfoksit'in (DMSO) etkisi. *Çağdaş Cerrahi Dergisi* 1993; 7:91-2.

5. Pihan G ,Regillo C, Szabo S. Free radicals and lipid peroxidation in ethanol-or aspirin-induced gastric mucosal injury. *Digest Dis Sci.* 1987;32: 1395-401.
6. Eade NR, Taussing LM, Marks MI. Hydrocarbon pneumonitis. *Pediatrics* 1974; 54:351-56.
7. Hotz P, Pilliod J, Bernard A, Berode M, Rey F, Mazzacato C et al. Hydrocarbon exposure, hypertension and kidney function tests. *Int Arch Occup Environ Health* 1990; 62:501-8.
8. Karlson KH. Hydrocarbon poisoning in children. *South Med J* 1982;839-40.
9. Ali BH. Effect of dimethyl sulfoxide or cystamine-induced duodenal ulceration in rats. *Clin Exp Pharmacol Physiol* 1990; 17:463.

Correspondence: Prof.Dr.N.Engin AYDIN
İnönü Üniversitesi Tıp Fakültesi
PK 6. Karakaş MALATYA