



Avascular necrosis of the femoral head in sickle cell disease

Neslihan Karakurt¹, Mehmet Ali Deveci²

¹Hitit University Çorum Training and Research Hospital, Pediatric Hematology, Oncology, Çorum, Turkey

²Çukurova University, Faculty of Medicine, Orthopaedics and Traumatology Department, Adana, Turkey

Abstract

Sickle cell disease (SCD) is a life threatening hemoglobinopathy effecting various systems. SCD is an important health issue in Turkey, especially in the southern areas. The patients suffer from complications resulting from vaso-occlusion and hemolysis. Twenty- two percent of children and 49% of adults with Hb SS are reported to have avascular necrosis (AVN). The SCD panel 2014 recommends to evaluate all children with SCD and hip pain for AVN by history, physical examination, radiography and magnetic resonance imaging. Long term daily oral treatment with hydroxyurea has been shown to reduce complications in SCD. Hydroxyurea does not only increase the level of fetal hemoglobin but also it causes a reduction in the number of circulating leukocytes, increases red blood cell size. Here in two SCD patients who developed AVN in femoral head are reported and it is aimed to raise awareness to this morbidity and the importance of regular use and dosage escalation of hydroxyurea therapy.

Keywords: Sickle Cell Disease; Avascular Necrosis; Pediatrics.

INTRODUCTION

Sickle cell disease (SCD) is a life threatening hemoglobinopathy effecting various systems. Incidence of Hb S is 0.3% in Turkey, whereas it is 10% in southern coastal cities (1). The patients suffer from complications resulting from vaso-occlusion and hemolysis. 26% of children and 49% of adults with Hb SS are reported to have avascular necrosis (AVN). AVN occurs mostly in femoral head, humerus and vertebrates (2). Here in two SCD patients who developed AVN in femoral head are reported and it is aimed to raise awareness to this morbidity and the importance of regular use and dosage escalation of hydroxyurea therapy.

CASE REPORT

First case is a 12 year old boy seeking medical attention for pain in his right hip. He had a diagnosis of SCD and was on hydroxyurea (20mg/kg/day) for 5 years. On the first visit, he complained of pain in weight bearing right hip, which lasted for 6 months. Physical examination did not reveal organomegaly and neurological examination was normal. Passive internal rotation was 5 degrees and

flexion of the hip was 60 degrees with pain. He had a hemoglobin level of 8.4 g/dL, white blood cells of 12000/mm³, trombocytes of 439000/mm³, MCV of 96.0 fL. Hemoglobin electrophoresis showed that Hb S was 75%, Hb A 0.6%, Hb F 10.9% and Hb A2 5.5%. The patient was diagnosed with avascular necrosis of femoral head by means of x ray films and MRI (Figure 1).

Orthopedical consultation was done and follow-up with walking with crutches and without weight bearing was recommended and dosage of hydroxyurea was increased. Appropriate analgesics were prescribed. In the follow-up the avascular necrosis has worsened radiologically in two years but the patient has no symptoms other than restriction of the internal rotation of the hip and 1 cm of shortening.

Second case is an 11 year old boy with a diagnosis of SCA, who complained of pain in hip lasting for 3 months. He was using hydroxyurea irregularly for 7 years (18 mg/kg/day) and he started to use the drug regularly 3 years ago, when he suffered from acute chest syndrome. He did not have organomegaly; neurological examination was normal. There was loss of internal rotation of the hip up to 5 degrees. Hemoglobin level was 9.7 g/dL, leukocyte 9000/mm³, trombocyte 348000/mm³, MCV 96.6 fL; Hb S 68%, Hb A.7%, Hb F 16.7% and Hb A2 2.9%. Radiological examination revealed AVN in the femoral head. The dosage of hydroxyurea was increased. It was recommended to walk with the help of crutches without weight bearing until the pain resolved. Both patients did not have any crisis about the hip but the avascular necrosis has showed radiological progression.

Received: 16.08.2016

Accepted: 21.09.2016

Corresponding Author

Neslihan Karakurt

Hitit University Çorum Training and Research Hospital, Pediatric Hematology, Oncology, Çorum, Turkey

E-mail: neslihankarakurt@gmail.com

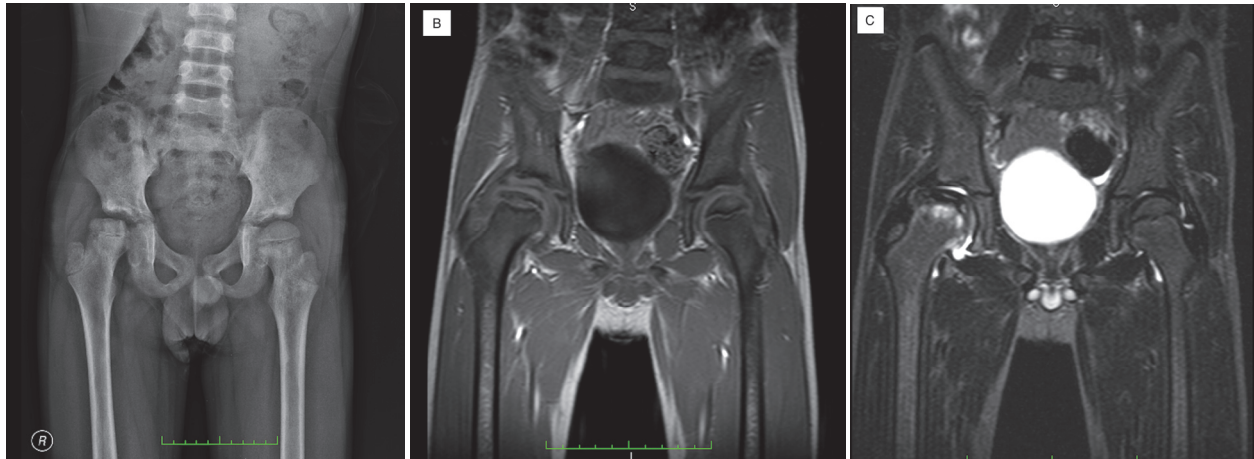


Figure 1. Anteroposterior plain radiography shows sclerosis, loss of height and irregularity on the head of femur of the right hip. The coronal T1 weight MRI shows loss of epiphyseal height, synovitis on the right hip (B) edema in metaphysis on coronal fat sat T1 image (C).

DISCUSSION

Hydroxyurea is a ribonucleotide reductase inhibitor which has been used for SCD since 1980s. It increases fetal hemoglobin levels (3,4). Long term daily oral treatment with hydroxyurea has been shown to reduce complications in SCD (4). Hydroxyurea does not only increase the level of fetal hemoglobin but also it causes a reduction in the number of circulating leukocytes, increases red blood cell size (4).

The SCD panel 2014 recommends hydroxyurea therapy at the age of 9 months (4). Starting dosage is 20 mg/kg/day and dose escalation is based on clinical and laboratory findings. It is recommended to increase the dosage up to 35 mg/kg/day with a target of mild myelosuppression (absolute neutrophil count $\geq 2000/\mu\text{l}$, platelet $\geq 80000/\mu\text{l}$). A clinical response to treatment may take 3-6 months and patients are to be reminded that adherence to daily dosing is very important to get a good response (4). There may be personal differences in between the clinical response to hydroxyurea therapy. Various *single nucleotide polymorphisms* (SNPs) have been identified which modify hemoglobin F response (5-6). Since the cases described here were on hydroxyurea treatment at the lowest dosage, the dosage is increased and it is planned to check for hemoglobin F response in at least 3 months.

The SCD panel 2014 recommends to evaluate all children with SCD and hip pain for AVN by history, physical examination, radiography and magnetic resonance imaging (4). Analgesic use and consultation of

physical therapy and orthopedic departments for follow up is recommended (4). The prognosis of the avascular necrosis of the hip in children depends on the age of the patient, stage and progression of the disease. Early onset arthroplasty usually in second and third decades of life might be necessary in advanced osteoarthritis.

To sum up, SCD is an important health issue, especially in the southern areas. Follow up of SCD patients with hydroxyurea and raise awareness of the disease and its complications is of great value.

REFERENCES

1. Canatan Duran, Türkiye'de Hemoglobinopatilerin Epidemiyolojisi. Hematolog 2014;4(1):11-23.
2. Aygün Banu. Orak Hücreli Anemi: Fizyopatogenez ve Klinik Bulgular. Hematolog 2014;4(1):66-79.
3. Ünal Selma, Orak Hücreli Anemi Tedavi ve İzlem. Hematolog. Hematolog 2014;4(1):79-94.
4. Yawn BP, Buchanan GR, Afenyi-Annan AN, Ballas SK, Hassell KL, James AH et al. Management of sickle cell disease: summary of the 2014 evidence-based report by expert panel members. JAMA 2014;10;312(10):1033-48.
5. Bae HT, Baldwin CT, Sebastiani P, Telen MJ, Ashley-Koch A, Garrett M et al. Meta-analysis of 2040 sickle cell anemia patients: BCL11A and HBS1L-MYB are the major modifiers of HbF in African Americans Blood 2012;30;120(9):1961-2.
6. Sheehan VA, Crosby JR, Sabo A, Mortier NA, Howard TA, Muzny DM et al. Whole exome sequencing identifies novel genes for fetal hemoglobin response to hydroxyurea in children with sickle cell anemia. PLoS One 2014;31;9(10):e110740.