



Synovial hemangioma originating from the 4 th finger tendon sheath

Erdal Uzun¹, Yakup Ekinci², Mehmet Yetis³

¹Kayseri Research and Training Hospital, Orthopedic and Traumatology Clinic, Kayseri, Turkey

²Develi State Hospital, Orthopedic and Traumatology Clinic, Kayseri, Turkey

³Ahi Evran University Research and Training Hospital, Department of Orthopedic and Traumatology, Kirsehir, Turkey

Abstract

Synovial haemangiomas are benign vascular lesions that originate from any synovial tissue, which may behave like locally aggressive. Haemangiomas developing in the hand in relation to tendon and the tenosynovium (tendon sheath) are very rare. Among the differential diagnosis for lesions of the hand, synovial hemangioma of the articular surface and tendon sheath is often overlooked due to its rare nature. A 49 year-old woman applied for a mass on her right dominant hand forth finger above the flexor tendon at the 4th metacarpophalangeal joint site is presented in this study. An ultrasonography was planned which confirmed a soft tissue lesion above the 4th flexor tendon at the 4th metacarpophalangeal joint site with appearance similar to giant cell tumour of the tendon sheath. After excision, the histopathologic analysis demonstrated tenosynovial haemangioma. The rare causes of finger masses should be considered also during the differential diagnosis. Local invasions and recurrence may be prevented with early surgical treatment and total excision of the lesion.

Keywords: Synovial Haemangioma; Tendon Sheath; Tumor, Benign.

INTRODUCTION

Congenital vascular malformations are rare and may involve any region of the body (1). The upper extremity is involved in 30% to 60% of patients with vascular malformations (2). Haemangiomas occurring in relation to the tenosynovium in the hand are also uncommon. In the literature only a few cases are reported arising in relation to the tenosynovium of the tendons of the hand (3-7).

Treatment for these lesions represents a challenge because recurrence of these lesions is common and lesions are often much more extensive than suggested by the physical examination. Surgical intervention often depends on the location of the malformation, symptoms, and the vessels involved. In this article we report a patient with a synovial haemangioma arising from her right hand forth finger flexor tendon.

CASE REPORT

A 49-year-old right hand dominant woman admitted to orthopaedic clinic with a swelling and severe pain on her

right 4th finger. From her history the lesion was painful and it had first appeared about six months before and it had been gradually enlarging until the last two months. The swelling extended over the volar surface of her 4th finger in the zone II region and the pain was worsening radiating along her ring and palm. She noted nearly 1*0.5 cm soft tissue mass at the volar base of her 4th finger which was tender to touch and normothermic. There was moderate pain with passive and active extension of the 4th finger, localized to the volar aspect of the 4th metacarpophalangeal (MCP) joints.

She reported no additional pathology or trauma or any associated fevers or rigors. No neurovascular deficit or limitation of hand function was observed. There was no pathologic sign on XR Imaging. An ultrasonography (USG) was arranged which confirmed an uniform distribution of septal soft tissue mass above the 4th flexor tendon sheath. Surgical exploration was considered with a probable diagnosis of a giant cell tumour because of the location and clinical presentation of the tumour. A zigzag incision was made and a 1*1 cm dark red non-pulsatile, fleshy, dusky, vascular tumour was appeared over the 4th flexor tendon sheath (figure 1).

The pathological specimen was sent to the pathologist for examination. Histology report revealed that the tenosynovium was expanded by a dilated, thin-walled vascular lesion. The appearances were those of a synovial haemangioma of the tenosynovium of the flexor tendons. The patient was informed of the histology and

Received: 25.09.2016

Accepted: 31.10.2016

Corresponding Author

Erdal Uzun

Kayseri Research and Training Hospital, Orthopedic and Traumatology Clinic, Kayseri, Turkey

E-mail: nuzuladre@gmail.com

its prognosis and is under regular review in clinic. There became no limitation of hand function and the patient could return her daily activities after 2 weeks after the operation. At her last follow-up at six months following the procedure there was no evidence of any recurrence

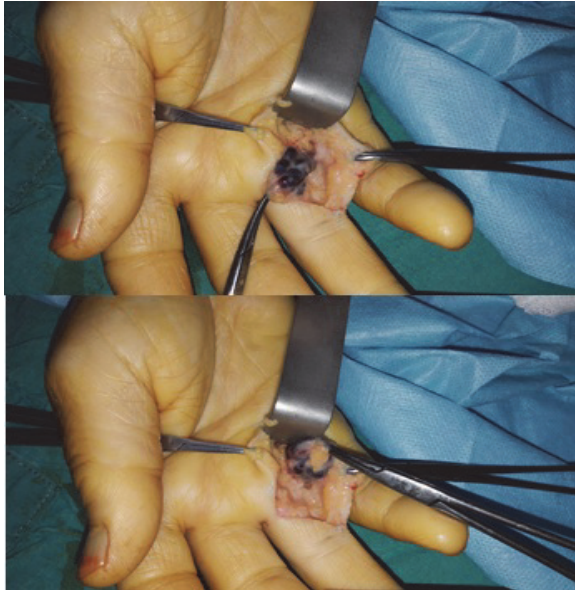


Figure 1. Intraoperatif photo of a 1*1 cm dark red non-pulsatile, fleshy, dusky, vascular tumour over the 4th flexor tendon sheath.

DISCUSSION

Although hemangiomas are common in the upper extremity involving in 30% to 60% of patients with vascular malformations (2), haemangiomas occurring in relation to the tenosynovium in the hand are relatively uncommon. In the hand these tumours generally have been described in relation to peripheral nerves or muscles (8-10). Also the literature describes only a few cases of a vascular malformation in a tendon sheath (3-7). For this reason they don't come to mind at the differential diagnosis of hand tumors. Due to the non specificity of the symptoms and physical examination clinical diagnosis of these uncommon tumours is quite difficult, Devaney et al reported a low rate of 22% clinically and 67% in the first pathological evaluation (11). As in our case, more often it is involved in the differential diagnosis of giant cell tumor.

Synovial hemangiomas are typically seen in children and young adults who present with complaints of pain and/or swelling. Often these masses have been present for many months before they cause a complaint which prompts medical attention (12). Our case was a 46 year old woman and there was nonspecific symptoms as swelling and severe pain for 6 months and the differential diagnosis could be made after excisional biopsy and histologic examination.

Although these lesion are generally benign and have slow-growing process, early diagnosis and treatment is important to prevent local invasions and recurrences. Wide surgical excision is the treatment of choice and ensures reduced rates of recurrence which can be common with this lesion (13). We completely excise the synovial hemangiomas from the normal tendon sheath. There became no limitation of hand function and the patient could return her daily activities after 2 weeks after the operation. At her last follow-up at six months following the procedure there was no evidence of any recurrence.

In conclusion, surgeons must consider synovial hemangioma as a rare cause of finger masses and it should be kept in mind during the differential diagnosis. Although these lesions commonly occur as a slow-growing process, local invasions and recurrences may be prevented with early surgical treatment and total excision of the lesion.

REFERENCES

1. Malan E, Puglionisi A. Congenital angiodysplasias of the extremities (Note 1: Generalities and classification; venous dysplasias). *J Cardiovasc Surg (Torina)* 1964;5:87-130.
2. Kaplan EN. Valcular malformation of the extremities. In: Williams HB, editor. *Symposium of vascular malformation and melanotic lesion*. St Louis: CV Mosby 1983;44-061.
3. Rico AA, Holguin PH, Gonzalez IG, Coba JM. Flexor tendon synovial sheath haemangioma imicking subacute tenosynovitis. *J Hand Surg Br* 1994;19(6):704-5.
4. Spinner M, Moon S, Young L. Recurrent cavernous haemangioma of the extensor tendons of the hand. *Hand* 1983;15(2):223-7.
5. Waddell GF. A haemangioma involving tendons. *J Bone Joint Surg Br* 1967;49(1):138-41.
6. Hill FC, Yuen A, Ramakrishnan A. Vascular malformation of the flexor tendon presenting as tenosynovitis. *Hand (N.Y)* 2012; 7(2):200-3.
7. Talwalkar S, Hayton M, Stilwell J, Temperley D, Freemont A. Tenosynovial haemangioma of the finger. *Acta Orthop Belg* 2005;71(5):618-21.
8. Nagay L, McCabe SJ, Wolff TW. Haemangioma of the digital nerve: a case report. *J Hand Surg Br* 1990;15(4):487-8.
9. Prosser AJ, Burke FD. Haemangioma of the median nerve associated with Raynaud's phenomenon. *J Hand Surg Br* 1987;12(2):227-8.
10. Chen VT. Haemangioma of adductor pollicis. *Hand* 1977;9(2):187-94.
11. Devaney K, Vinh TN, Sweet DE. Synovial hemangioma: a report of 20 cases with differential diagnostic considerations. *Hum Pathol* 1993;24(7):737-45.
12. Holzapfel BM, Geitner U, Diebold J, Glaser C, Jansson V, Durr HR. Synovial hemangioma of the knee joint with cystic invasion of the femur: a case report and review of the literature. *Arch Orthop Trauma Surg* 2009;129(2):143-8.
13. Chow LT, Ho PC, Kumta SM. Papillary endothelial hyperplasia within synovial haemangioma of the flexor tendon sheath of the wrist. *APMIS* 2004;112(4-5):314-8.