



Idiopathic Infected Spermatic Cord Hydrocele: A Case Report

İlhan Ciftci¹, Pinar Karabagli², Mustafa Koplay³

¹Department of Pediatric Surgery, Selcuk University Medical Faculty, Konya, Turkey

²Department of Pathology, Selcuk University Medical Faculty, Konya, Turkey

³Department of Radiology, Selcuk University Medical Faculty, Konya, Turkey

Abstract

Spermatic cord hydrocele is a loculated fluid collection along the spermatic cord, separated from and located above the testicle and the epididymis. This entity is a rare congenital anomaly and generally they are congenital or acquired. Infected cord hydrocele in infants is extremely rare. Idiopathic infected cord hydrocele has not been reported in the literature. We report the patient of an idiopathic infected spermatic cord hydrocele in a 3-year-old boy who unresponded to antibiotics. An infected infected spermatic cord hydrocele in a child has not been described and consequently not included in the differential diagnoses of patients with acute surgical conditions of the scrotal region. Attention should be called to and emphasis is placed on the emergency surgical exploration of this unusual case.

Key Words: Spermatic Cord Hydrocele; Child; Scrotum.

Sebebi Bilinmeyen Enfekte Spermatik Kord Hidroseli: Olgu Sunumu

Özet

Spermatik kord hidroseli testis ve epididimin üzerinde spermatic korddan ayrı şekilde lokalize kistik sıvı toplanmasıdır. Bu durum az görülen konjenital anomalilerdendir. Akkız olarak ta ortaya çıkabilir. İnfantlarda kord hidroselinin enfekte olması oldukça nadirdir. İdiyopatik oluşması literatürde bildirilmemiştir. Biz çalışmamızda sebebi bilinmeyen ve antibiyotik tedavisine cevap vermeyen 2 yaşında enfekte spermatik kord hidroseli olguyu sunduk. Enfekte kord hidroseli nadir görülsede scrotal bölgedeki cerrahi lezyonlarında ayrıncı tanıya yer almasa bile akılda tutulmalıdır. Bu az görülen durum acil cerrahi müdahale gerektirebilir, bu açıdan dikkat edilmelidir.

Anahtar Kelimeler: Spermatik Kord Hidroseli; Çocuk; Skrotum.

INTRODUCTION

Benign intrascrotal lesions are a common finding in the male children. Most of them occur in paratesticular tissue and are cystic in nature. Spermatic cord hydrocele (SCH) is a loculated fluid collection along the spermatic cord, separated from and located above the testicle and the epididymis. This entity is a rare congenital anomaly (1). SCH are congenital or acquired. Hydroceles are generally asymptomatic unless associated with trauma or infection. Affected children usually present with a firm groin swelling, and ultrasound (US) evaluation of the inguinal region is performed to exclude an incarcerated inguinal hernia, inguinal lymphadenopathy or an extratesticular tumour. Idiopathic infected cord hydrocele in infants is an extremely rare. We report the case of an idiopathic infected cord hydrocele in a 2-year-old boy who unresponded to antibiotics.

CASE REPORT

A 3-year-old boy with painful, redness and swelling right hemiscrotum was presented in the pediatric surgery outpatient clinic. On physical examination, he had a temperature of 39.5°C and his vital signs were stable. External genitals revealed tender, swollen, redness and heat on the right side of the scrotum (Figure 1).

Due to pain and swelling his right testis could not be palpated. The left scrotum and testis were normal. The systemic examination did not reveal any positive findings. We suspected testicular torsion. He underwent emergency color doppler ultrasonography of the scrotum, which suggested turbid fluid with fibrin in the cord hydrocele sac with normal blood flow and size of testicles wall of the hydrocele sac thickened. The urine examination did not show any positive findings.

The blood results did not reveal any abnormality including WBC of $16 \times 10^3 \mu\text{l}$. The blood culture did not grow any organisms. The patient was admitted to the pediatric surgery clinic care and was started on analgesia and intravenous ceftriaxone. The patient did not respond to antibiotics. His redness, swelling and pain did not decrease. He received surgical treatment. Surgical procedure started with right inguinal incision.



Figure 1. Swollen and redness at right side of the scrotum.

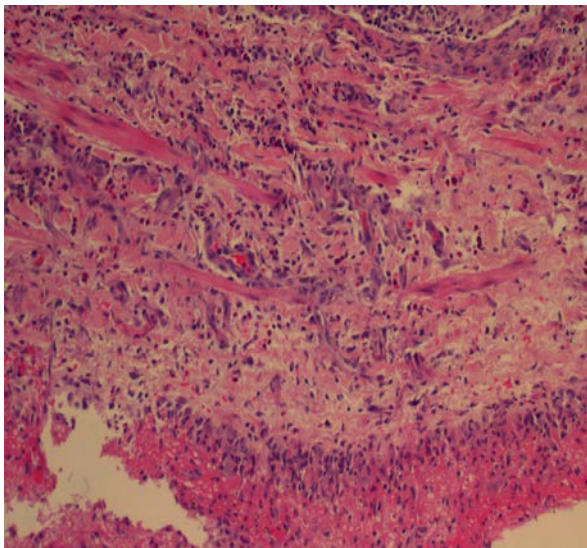


Figure 2. Eosinophil leukocytes, neutrophils and lymphocytes in inflammation (Hematoxylin-eosin stain, original magnification, X 200)

The infected cyst and abscess were found in the exit of the inguinal canal. Cyst and abscess were drained purulent discharge and high ligation of a patent processus vaginalis. Tissue pathology has been reported as “*the inflammatory infiltrate*” in the wall of cyst consist predominantly of chronic inflammatory cells with prominent eosinophilic component (Figure 2). A drain was put into abscess region. The patient was discharged on the 4th day with follow-up arranged as an outpatient in a week’s time.

DISCUSSION

Infected hydrocele most commonly result from the spread of intraabdominal infection through a patent processus vaginalis into the scrotum (2). Appendicitis is the most common source but can occur with necrotizing enterocolitis or other intra-abdominal infections in premature neonate (3,4). Less common causes include testicular torsion, incarcerated inguinal hernia, epididymo-orchitis, and urinary tract infection (5-6). Accurate diagnosis before exploration is difficult because symptoms cannot be distinguished from these conditions. Because ultrasonography or color doppler ultrasonography is an effective tool for the evaluation of an acute scrotal swelling, an infected hydrocele may be diagnosed initially (7).

Sonography shows a complex fluid collection with associated inflammatory changes such as adjacent hyperemia and scrotal skin and hydrocele wall thickening that help to differentiate pyocele from other complex collections.

Infected hydrocele in a child is rare but the acute onset of scrotal pain and swelling is usually considered to be indicative of surgical exploration. We did not found infected cord hydrocele in literature. In our patient, we could not find any preliminary cause for infected cord hydrocele.

There are no distinguished clinical features pertaining to the infected cord hydrocele. As with other common conditions such as testicular torsion, incarcerated inguinal hernia, lymphadenitis and epididymo-orchitis, acutely swollen, tender, erythematous, and irreducible scrotal mass with fever is the common presentation. As the testicular

torsion and incarcerated inguinal hernia are emergent surgical conditions requiring immediate surgical interventions, these must be excluded before considering infected hydrocele and lymphadenitis. Surgical debridement, hydrocelectomy and systemic antibiotics are effective treatment in the infected hydrocele if the testis appears normal (8). The exception of an article (9), as conservative management of infected hydrocele has not been documented in the literature before, it is very difficult to say that the infected hydrocele would resolve itself or not after conservative treatment, though in their case, the patient would need further repair of the hydrocele as it did not resolve after conservative treatment.

Before surgical exploration, ultrasonography may be helpful for evaluation of an acute scrotal swelling (10).

An infected SCH in a child has not been described and consequently not included in the differential diagnosis of patients with acute surgical conditions of the scrotal region. Attention should be called to and emphasis is placed on the surgical exploration of this unusual case.

REFERENCES

1. Martin LC, Share JC, Peters C, Atala A. Hydrocele of the spermatic cord: Embryology and ultrasonographic appearance. *Pediatr Radiol* 1996;26:528-30.
2. Lim GY, Lim SA, Jeong YJ, Hahn ST, Lee JM. Infantile scrotal pyocele simulating missed testicular torsion on sonography. *J Clin Ultrasound* 2003;31:116-8.
3. Friedman SC, Sheynkin YR. Acute scrotal symptoms due to perforated appendix in children: Case report and review of literature. *Pediatr Emerg Care* 1995;11:181-2.
4. Hsieh DS, Jeng SY, Liu YS. Bilateral idiopathic infantile pyoceles: A case report. *Zhonghua Yi Xue Za Zhi (Taipei)* 1998;61:39-43.
5. Dehner LP, Scott D, Stocker JT. Meconium periorchitis: A clinicopathologic study of four cases with a review of the literature. *Hum Pathol* 1986;17:807-12.
6. Kim KK, Park HW. An unusual infected hydrocele-A case report. *J Korean Med Sci* 1995;10:42-3.
7. Coley BD. Sonography of pediatric scrotal swelling. *Semin Ultrasound CT MR* 2007;28:297-306.
8. Yang YJ, Liu CC, Lin YJ, Yao WJ, Cheng HL. Idiopathic infected hydrocele in infants: A case report and review. *Pediatr Infect Dis J* 1996;15:545-6.
9. Sagar J, Kumar S, Mondal D, Shah DK. Idiopathic infected hydrocele in a toddler: A case report with review. *ScientificWorldJournal* 2006;23:2396-8.
10. Ku JH, Yim YS, Lee NK, Park YH. Infected hydrocele in a neonate. *Urol Int* 2000;65(4):216-7.

Received/Başvuru: 06.07.2012, Accepted/Kabul: 27.09.2012

Correspondence/İletişim

İlhan CİFTCI
Selcuk Universitesi Tıp Fakultesi, Çocuk Cerrahisi
Anabilim Dalı, KONYA
Tel: 90 332 2415000- Fax: 90 332 2412184
E-mal: drciftci@yahoo.com

For citing/Atıf için:

Ciftci I, Karabagli P, Koplay M. Idiopathic infected spermatic cord hydrocele: A case report. *J Turgut Ozal Med Cent* 2013;20(1): 65-67 DOI: 10.7247/jtomc.20.1.14