



## Ovarian Pregnancy at the 13<sup>th</sup> Weeks of Gestation: A Case Report

Oktaç Kaymak<sup>1</sup>, Yavuz Şimşek<sup>2</sup>, Şevki Çelen<sup>1</sup>, Serkan Kahyaoğlu<sup>1</sup>, Hakan Timur<sup>1</sup>, Nuri Danışman<sup>1</sup>

<sup>1</sup>Zekai Tahir Burak Eğitim ve Araştırma Hastanesi Kadın Hastalıkları ve Doğum, Ankara

<sup>2</sup>İnönü Üniversitesi Tıp Fakültesi, Kadın Hastalıkları ve Doğum Anabilim Dalı, Malatya

### Abstract

Ovarian pregnancy is a rare form of ectopic pregnancy in which the gestational sac is implanted within the ovary. The incidence is 0.5 to 3% of all ectopic gestations. Mostly diagnoses are made by the first trimester routine ultrasonography or during the operation for acute abdominal pain. In this case report, we present a 13 weeks spontaneous ovarian gestation who had no risks of ectopic pregnancy. On the transvaginal sonographic scan, an alive fetus with a crown-rump length measured 67 mm (13 weeks) was detected in the left ovarian region. A ruptured ovary which contained a fetus of 13 weeks gestation was observed during laparotomy. A left oophorectomy was performed with the transfusion of two units of fresh blood peroperatively. The possibility of ovarian pregnancy should always be kept in mind that emergent laparotomy with concurrent oophorectomy can be necessary surgical interventions for this rare clinical condition.

**Key Words:** Ectopic Pregnancy; Ovarian Pregnancy; Abdominal Pain.

### On Üçüncü Gebelik Haftasında Ovaryan Gebelik: Bir Olgu Sunumu

#### Özet

Ovaryan gebelik, gestasyonel kesenin over içerisine implante olduğu nadir bir ektopik gebelik türüdür. Tüm ektopik gebelikler içerisinde %0.5-3 oranında görülür. Sıklıkla tanı ya ilk trimester rutin ultrasonografisi sırasında ya da akut abdominal ağrı nedeni ile yapılan cerrahi girişimde konur. Biz bu vakada herhangi bir risk faktörü olmayan 13 haftalık ovaryan gebelik sunduk. Transvajinal ultrasonografik taramada sol ovaryan bölgede baş-popo mesafesi (CRL): 67 mm (13 hafta) canlı bir fetüs saptandı. Laparotomi esnasında içinde 13 haftalık fetüs içeren ruptüre over görüldü. Peroperatif 2 ünite taze kan transfüzyonu ile beraber sol ooforektomi yapıldı. Acil laparotomi ve eşzamanlı ooforektomi gibi cerrahi girişimleri gerektirebilen nadir bir klinik durum olarak ovaryan gebelik olasılığı daima akılda tutulmalıdır.

**Anahtar Kelimeler:** Ektopik Gebelik; Ovaryan Gebelik; Karın Ağrısı.

## INTRODUCTION

About 0.5-3% of ectopic pregnancy is presented by the ovarian pregnancy (OP) whose incidence seems to be increasing from a rate of 1/ 40000 pregnancies in 1950 to a rate of 1/7000 pregnancies in 1983 (1).

Today the actual etiology of OP is not yet fully understood. In the etiology and pathogenesis of OP; primary OP with intra-follicular fertilization, retrograde flow in the fallopian tube of the fertilized ovum released on to the ovary and previous PID that increase the incidence of OP because of the impairment in tubal motility and thickening of tunica albuginea of ovary due to inflammatory reaction are possible mechanisms.

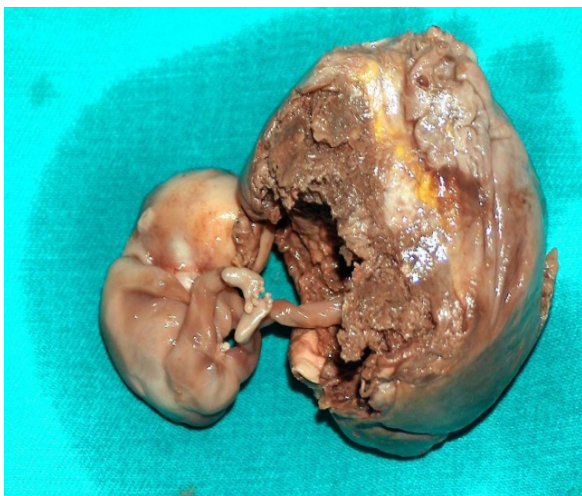
An intrauterine contraceptive device is frequently mentioned as the etiology. In cases of OP, haemorrhagic follicular rupture has led to discovery of ovarian implantations, which would have been missed if only macroscopic investigation of the ovary had been done. In OP, it has been mentioned that an increase in ovarian vascularity generally results in rupture of the ovarian capsule and haemoperitoneum. The essential diagnosis of OP necessitate histopathologic investigations on the basis of the four Spiegelberg's criteria (2,3). Here, we report a case of spontaneous OP as a rare localisation of ectopic pregnancy at 13<sup>th</sup> weeks of gestation.

## CASE REPORT

A 34-years-old primigravid Turkish patient attended to our tertiary referral center with lower abdominal pain and vaginal bleeding. During physical examination; tachycardia, hypotension, active vaginal bleeding, direct and indirect rebound tenderness of the abdomen were determined. On admission serum  $\beta$ -hCG level was  $>5000$  and hematocrit was 29.3%. On transvaginal sonographic scan, an alive fetus with a crown-rump length measured 67 mm (13 weeks) was detected in the left ovarian region. Intraabdominal excess fluid collection was established.

Defibrinated blood sample was obtained by culdosynthesis. She had an emergency laparotomy and 1400 ml hemoperitoneum has been removed. A ruptured ovary which contained a fetus of 13 weeks gestation was observed. The patient was free of pelvic adhesions. A left oophorectomy was performed with the transfusion of two units of fresh blood peroperatively. The patient had an uneventful postoperative recovery and was discharged on day 3 postoperatively.

In macroscopic pathologic examination, an ovary sized  $6 \times 4 \times 2,5$  cm co-existent with a male fetus was detected (Figure 1). Microscopically; hemorrhagic tissues, including chorionic villi were present exclusively in the ovary.



**Figure 1.** Macroscopic appearance of the surgical specimen presenting a ruptured left ovarian pregnancy

## DISCUSSION

Preoperative diagnosis of ovarian pregnancy is very difficult. Spiegelberg's criteria are used for definite diagnosis. Spielberg, in 1878, stated that (1), the fallopian tube must be intact and separate from ovary (2); the gestational sac must occupy the normal position of the ovary (3); the gestational sac must be connected to the uterus by the utero ovarian ligament; and (4) ovarian tissue must be demonstrated within the mass of the sac. Our case fulfilled all of these four criteria. For the diagnosis of OP histopathological evaluation is mandatory.

Raziel and Coll reported a 6.3 weeks gestational period up to surgery within a range of 5-7.5 weeks (4). However, our patient has been diagnosed at 13 weeks of gestation. Separately in this patient, there was no significant risk factor for OP. Although it is possible to treat ovarian pregnancy with partial oophorectomy; in this patient, we had to perform a total oophorectomy due to bleeding concerns during the surgery because of the burden of the pathological process within the ovary caused by a 13 weeks gestation fetus. In addition to well known reasons, recent case reports notify an increase in the incidence of ovarian pregnancy in infertile couples who were medicated by clomiphene citrate, intracytoplasmic sperm injection, prolonged invitro culture and embryo transfer at blastocyst stage (5-7). Widespread use of routine transvaginal ultrasonography at first trimester enables us to diagnose such cases earlier and manage them under elective conditions (8-10).

Definitive treatment of OP consist medical treatment with methotrexate or other chemotherapeutics for clinically suitable patients and surgical treatment by partial or total oophorectomy based on the clinical situation during surgery. Ovarian pregnancy should always be kept in mind that emergent laparotomy with concurrent oophorectomy can be necessary surgical interventions for this rare clinical condition.

## REFERENCES

1. Gaudoin MR, Coulter KL, Robins AM, Verghese A, Hanretty KP. Is the incidence of ovarian ectopic

- pregnancy increasing? Eur J Obstet Gynecol Reprod Biol 1996;70:141-3.
2. Sergent F, Mauger-Tinlot F, Gravier A, Verspyck E, Marpeau L. Ovarian pregnancies: reevaluation of diagnostic criteria. J Gynecol Obstet Biol Reprod (Paris) 2002;31:741-6.
  3. Kraemer B, Kraemer E, Guengoer E, Juhasz-Boess I, Solomayer EF, Wallwiener D et al. Ovarian ectopic pregnancy: diagnosis, treatment, correlation to Carnegie stage 16 and review based on a clinical case. Fertil Steril 2009;92:e13-5.
  4. Raziel A, Golan A, Pansky M, Ron-El R, Bukovsky I, Caspi E. Ovarian pregnancy: a report of twenty cases in one institution. Am J Obstet Gynecol 1990;163: 1182-5.
  5. Fylstra DL. Ovarian ectopic pregnancy 6 years after supracervical cesarean hysterectomy: a case report. J Reprod Med 2009;54:649-51.
  6. Atabekoglu CS, Berker B, Dunder I. Ovarian ectopic pregnancy after intracytoplasmic sperm injection. Eur J Obstet Gynecol Reprod Biol 2004;112:104-6.
  7. Chiapponi C, Trifoglio O, Chiapponi R. Complex ovarian pregnancy. Obstet Gynecol 2012;119:478-9.
  8. Juan YC, Wang PH, Chen CH, Ma PC, Liu WM. Successful treatment of ovarian pregnancy with laparoscopy-assisted local injection of etoposide. Fertil Steril 2008;90:e1-2.
  9. Hong SY, Kim DW, Shin JH, Seo YS, Park EJ, Park WI. A case of ovarian pregnancy after ipsilateral partial salpingectomy. J Minim Invasive Gynecol 2010;17:397-8.
  10. Oliveira FG, Abdelmassih V, Costa AL, Balmaceda JP, Abdelmassih S, Abdelmassih R. Rare association of ovarian implantation site for patients with heterotopic and with primary ectopic pregnancies after ICSI and blastocyst transfer. Hum Reprod 2001;16:2227-9.

Received/Başvuru: 30.03.2012, Accepted/Kabul: 11.07.2012

#### Correspondence/İletişim

**Oktay KAYMAK**  
Zekai Tahir Burak Eğitim ve Araştırma Hastanesi Kadın Hastalıkları ve Doğum Bölümü ANKARA/TURKEY  
GSM: 0532 6451903  
E-mail: oktaykaymak@gmail.com

#### For citing/Atf için:

**Kaymak O, Şimsek Y, Celen S, Kahyaoğlu S, Timur H, Danışman N. Ovarian pregnancy at the 13<sup>th</sup> weeks of gestation: A case report. J Turgut Ozal Med Cent 2013;20(1):71-73 DOI: 10.7247/jtomc.20.1.16**