

Coexistence of Thyroid Tuberculosis and Graves Disease

İsmail Hakkı Ersoy¹, Oğuzhan Aksu¹, Banu Kale Köroğlu¹, İbrahim Metin Çiriş²,
Atıla Altuntaş³, Mehmet Numan Tamer¹

¹Süleyman Demirel University Medical School, Department of Endocrinology and Metabolism, Isparta, Türkiye

²Süleyman Demirel University Medical School, Department of Pathology, Isparta, Türkiye

³Süleyman Demirel University Medical School, Department Nephrology, Isparta, Türkiye

Abstract

Thyroid tuberculosis is a rare condition, even in the populations with high prevalence of tuberculosis. It shows different clinical course, and may be asymptomatic. The incidence of thyroid tuberculosis was reported as 0.003%-0.1% in a postmortem study, however, its real incidence is not known exactly. Therefore, diagnosis of the disease may be overlooked or delayed. Consequently, it may present as an advanced stage disease with increased morbidity and mortality. Primary thyroid tuberculosis that presented with rapidly enlarging goiter together with cervical lymphadenopathy without pulmonary involvement was first reported in 1893. Fine needle aspiration biopsy together with acido-resistant staining of the aspiration material and the culture are quite valuable in the diagnosis of the disease. In this paper, we will discuss a case of thyroid tuberculosis with graves and hypoactive nodule, which diagnosed by histopathological examination of postoperative thyroidectomy material.

Key Words: Thyroid Tuberculosis; Graves Disease; Thyrotoxicosis.

Graves Hastalığı ve Tiroid Tüberkülozu Birlikteliği

Özet

Tüberkülozun toplumdaki prevalansı yüksek olsa bile tiroid tüberkülozu nadir görülen bir durumdur. Bu durum farklı bir klinik seyir gösterir ve asemptomatik olabilir. Postmortem çalışmalarda tiroid tüberkülozu insidansı %0.003-0.1 olarak rapor edilmesine rağmen gerçek tiroid tüberkülozu insidansı bilinmemektedir. Bu nedenle hastalığın tanısı gözden kaçabilir veya geçikebilir. Sonuç olarak hastalık ilerleyebilir ve mortalite ve morbiditenin artmasına neden olabilir. Primer tiroid tüberkülozu ilk kez 1893 yılında pulmoner tutulumun olmadığı ve servikal lenfadenopatinin eşlik ettiği guatrda hızlı büyümeyle rapor edilmiştir. Hastalığın tanısında iab ve aspire edilen materyalin aside direçli olarak boyanması ve kültürü oldukça değerlidir. Biz burada tiroidektomi operasyonu sonrasında histopatolojik incelemede tanı konmuş graves ve hipoaktif nodülle beraber tiroid tüberküloz olgusunu tartışacağız.

Anahtar Kelimeler: Tiroid Tüberkülozu; Graves Hastalığı; Tirotoksikoz.

INTRODUCTION

Thyroid tuberculosis is an extremely rare condition, even in the populations with high prevalence of tuberculosis (1,2). It was first reported in 1862, in a case of disseminated tuberculosis (3). Primary thyroid tuberculosis that presented with rapidly enlarging goiter together with cervical lymphadenopathy without pulmonary involvement was first reported in 1893 (2). The incidence of thyroid tuberculosis was reported as 0.003%-0.1% in a postmortem study, however, its real incidence is not known exactly (1,4). Its incidence is about 43-46/100000 in Turkey (5). The clinical course of thyroid tuberculosis shows variations, and it may be asymptomatic. Therefore, diagnosis of the disease may be overlooked and delayed. Consequently, it may present as an advanced stage disease with increased morbidity and mortality (6). Fine needle aspiration biopsy together with acido-resistant staining of the aspiration material and the culture are quite valuable in the diagnosis of the disease (6,7). Although there are reported cases with concomitant thyroiditis, nodule, cyst, abscess and carcinoma in the thyroid gland, only

two cases with thyrotoxicosis and with graves were reported. In this paper, we will discuss a case of thyroid tuberculosis with graves and hypoactive nodule, which diagnosed by histopathological examination of postoperative thyroidectomy material.

CASE REPORT

A 40-year-old female patient was admitted to the endocrinology outpatient clinic with symptoms of palpitation, nervousness, weight loss and night sweat. Lymphadenopathy at the right submandibular area and palpable thyroid nodules were detected on physical examination. Laboratory parameters are shown in the table.

Thyroid ultrasonography showed, heterogeneous mixed nodules at the lateral and inferolateral regions of the right lobe with diameters of 22×15mm and 17×12mm and nodules with same character at the isthmus with the diameters of 25×14mm and 11×9mm. In addition, lymphadenopathy with a diameter of 2.5cm was observed in the submandibular area. On her thyroid scintigraphy, it was observed that the gland was

hyperplastic and iodine uptake has been increased (figure 1). She was diagnosed as Grave's disease and propylthiouracil was started. Additionally, hypoactive areas were observed in the inferolateral region of the right lobe. Fine needle aspiration biopsy was performed from the nodules in the inferolateral region of the right lobe and in the isthmus. Cytological examination was reported as benign. Total thyroidectomy was performed by general surgeon, after the patient being made euthyroid with antithyroid therapy. Postoperative pathology report showed granulomatous thyroiditis with caseification necrosis (figure 2,3). Two histochemical Ehrlich-Ziehl-Neelsen (EZN) staining procedures revealed no staining in favor of acido-resistant bacillus. The thorax tomography showed pleural shrinkage and two adjacent nodules in the medial segment of the middle lobe of the right lung, and numerous lymphadenopathies in the prevascular, aorticopulmonary and paraesophageal areas, the largest being 18×14mm in diameter at the right para-tracheal area. Due to these findings, patient was referred to the chest disease to evaluate for tuberculosis and antituberculosis therapy was started. The patient is still under follow-up with levothyroxine sodium replacement therapy and her general status is good.

Table: Laboratory parameters

	Değer	Referans
WBC	7600/μL	5200-12400
Hgb	8.4 gr/dl	13.6-17.2
MCV	60 fL	80.7-95.5
RDW	%18	11.8-14.3
Creatinine	0.4 mg/dL	0,66-1,09
Total protein	6.4 g/dL	4,1-8,3
Albumin	3.9 g/dL	2,8-5,2
Fecal occult blood	-	
Ferritin	3.8 ng/mL	4,63-204
ALT	19 U/L	0-45
AST	16 U/L	0-35
ESR	30	
CRP	3.1 mg/l	0-3
FT3	7 pg/ml	2.5-3.9
FT4	5,05 ng/dl	0.7-1.4
TSH	0.0007 IU/ml	0.34-4.2
Anti-TG	34 IU/ml	0-40
Anti-TPO	879 IU/ml	0-35

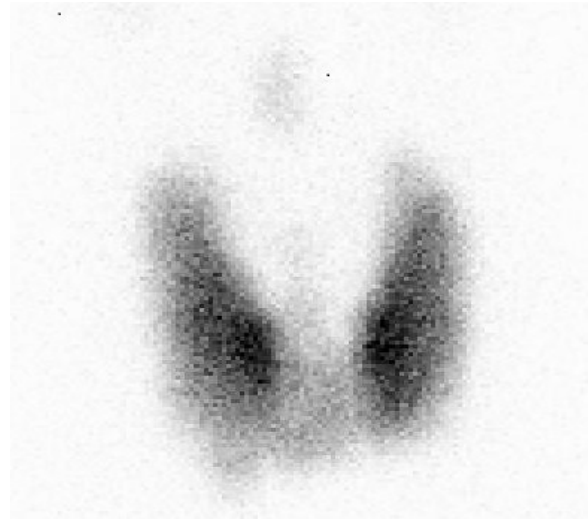

Figure 1. Thyroid scintigraphy, it was observed that the gland was hyperplastic and iodine uptake has been increased.

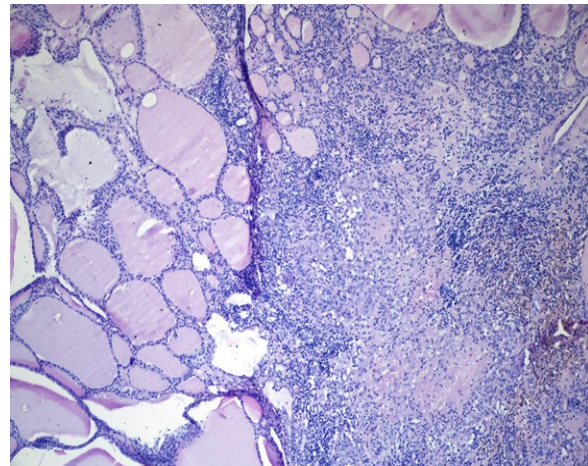


Figure 2. Areas of necrosis in thyroid tissue.

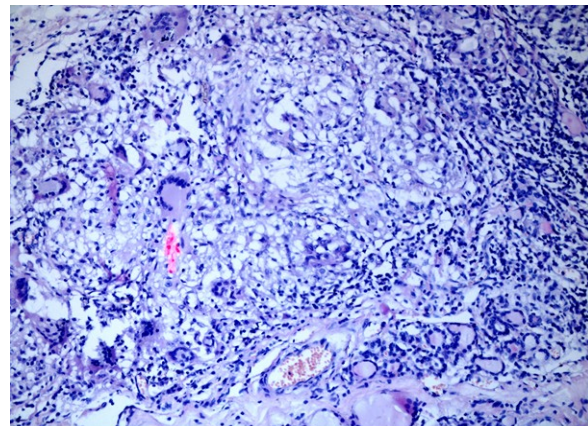


Figure 3. Photomicrograph showing thyroid follicles with an epithelioid cell granuloma and langerhans cells (H and E, ×200).

DISCUSSION

Tuberculosis is a disease affecting one third of the whole world, related to morbidity and mortality particularly in the developing countries. 5-10% of people who are infected with Tuberculosis bacilli become sick or infectious at some time during their life (5,8,10). Tuberculosis thyroiditis may present as the involvement of thyroid gland due to miliary tuberculosis or as focal caseous necrosis that is rarely seen and localized only in the thyroid tissue (7). The present case had disseminated tuberculosis involving also the thyroid gland. Thyroid gland may be affected due to hematogeneous or lymphogeneous spread or direct invasion from the laryngeal or cervical lymph nodes (9). Thyroid tuberculosis may be seen as a nodule, cold abscess, a cystic component, multinodular goiter or diffuse enlargement of the thyroid gland (9,10). Literature review revealed a case report with diffuse glandular enlargement but without cervical, mandibular or any other lymphadenopathy (11). Our patient presented with palpable nodule at thyroid gland and submandibular lymphadenopathy. However, in patients with tuberculosis thyroiditis, detection of regional and distant lymph nodes is very rare in the preoperative and even in the intraoperative period. (12). The postoperative computed tomography of the present case showed two adjacent nodules in the middle lobe of the right lung in addition to the multiple lymphadenopathies in the right paratracheal, prevascular, aorticopulmonary and paraesophageal areas. The clinical manifestation of tuberculosis thyroiditis may mimic acute infective thyroiditis, and the cases may describe pain and tenderness on the gland together with fever (13). Tuberculosis thyroiditis may rarely occur following subacute granulomatous thyroiditis (De Qervain's) or chronic nonsuppurative thyroiditis. Thyroid function tests are generally normal or may reveal euthyroid sick syndrome. It may be seen rarely together with hyperthyroidism (1,11) or hypothyroidism (14). The vascularization of the thyroid gland is increased in tuberculosis thyroiditis and excessive iodine deposition occurs. Furthermore, the phagocytes that are activated by tuberculosis bacillus may lead to hyperthyroidism by causing parenchymal damage and increasing hormone release (15). In a retrospective study, in which the patients with tuberculosis thyroiditis were reviewed, hyperthyroidism was found in only four of the 76 cases (10). Our patient had remarkable symptoms of hyperthyroidism at the presentation. In a reported case of tuberculosis thyroiditis concurrent with hyperthyroidism, diffuse enlargement of the gland without nodule and increased iodine uptake on the scintigraphy were determined in addition to the thyrotoxicosis clinic (11). It was considered that the case might be graves. The scintigraphy of the present case revealed increased I131 uptake and hypoactive areas on the thyroid gland. Antithyroglobulin and anti-TPO levels were high. Although, thyroid tuberculosis together with thyrotoxicosis has been reported in a limited number of studies; we were unable to find coexistence with graves. Tuberculosis might be triggering autoimmunity in the

developing populations, particularly in the regions with endemic goiter.

High erythrocyte sedimentation rate and positive ppd test may be helpful to verify the diagnosis of tuberculosis (15). However, the erythrocyte sedimentation rate was slightly high and the ppd was negative in the present case similar with the case in the literature (11). Despite the limited number of data in the literature, fine needle aspiration cytology and the culture are quite beneficial in the diagnosis of tuberculosis thyroiditis. The characteristic histological findings of tuberculosis are epithelial cell granulomas with central caseification necrosis, peripheral lymphatic infiltration, and Langhans type giant cells. Additionally, acido-resistant bacillus can be seen concurrently via EZN histochemical staining. Histological findings other than caseification necrosis can be seen also in subacute granulomatous thyroiditis (De Qervain's), therefore, special attention should be paid when making histological differential diagnosis (15). Moreover, sputum analysis, stool and urine cultures, polymerase chain reaction (PCR) and 14C-marked compounds may also be helpful in the diagnosis (3,15). In two studies, 8 of 1283 and 18 of 1565 cases respectively had been diagnosed with tuberculosis thyroiditis via fine needle aspiration cytology (3). According to the literature, fine needle aspiration cytology of the present case revealed no tuberculosis involvement, whereas, postoperative pathologic examination revealed granulomatous thyroiditis with caseification necrosis. However, two histochemical stainings with EZN showed no staining in favor of acido-resistant bacillus. In the literature, we observed a case of tuberculosis located in the thyroid gland, without lung and any other area involvement, with surgical treatment (11).

REFERENCES

1. Khan EM, Haque I, Pandey R, Mishra SK, Sharma AK. Tuberculosis of the thyroid gland: a clinicopathological profile of four cases and review of the literature. *Aust N Z J Surg* 1993;63:807-10.
2. Simkus A. Thyroid tuberculosis. *Medicina (Kaunas)* 2004;40:201-4.
3. Mondal A, Patra DK. Efficacy of fine needle aspiration cytology in the diagnosis of tuberculosis of the thyroid gland: a study of 18 cases. *J Laryngol Otol* 1995;109:36-8.
4. Tan KK. Tuberculosis of the thyroid gland--a review. *Ann Acad Med Singapore* 1993;22:580-2.
5. Bulbuloglu E, Ciralik H, Okur E, Ozdemir G, Ezberci F, Cetinkaya A. Tuberculosis of the thyroid gland: review of the literature. *World J Surg* 2006;30:149-55.
6. Pazaitou K, Chrisoulidou A, Ginikopoulou E, Angel J, Destouni C, Vainas I. Primary tuberculosis of the thyroid gland: report of three cases. *Thyroid* 2002;12:1137-40.
7. El Malki HO, El Absi M, Mohsine R, et al. Tuberculosis of the thyroid. Diagnosis and treatment. *Ann Chir* 2002;127:385-7.
8. Onyango RO. State of the globe: Tracking tuberculosis is the test of time. *J Glob Infect Dis* 2011;3:1-3.
9. Akbulut S, Sogutcu N, Arikanoglu Z, Bakir S, Ulku A, Yagmur Y. Thyroid tuberculosis in southeastern Turkey: Is this the resurgence of a stubborn disease? *World J Surg* 2011;35:1847-52.

10. Bulbuloglu E, Ciralik H, Okur E, Ozdemir G, Ezberci G, Cetinkaya A. Tuberculosis of the thyroid gland: review of the literature. *World J Surg* 2006;30:149-155.
11. Kapoor VK, Subramani K, Das SK, Mukhopadhyay AK, Chattopadhyay TK. Tuberculosis of the thyroid gland associated with thyrotoxicosis. *Postgrad Med J* 1985;61:339-40.
12. Tabacu E, Galie N, Galbenu P, Mitrea M. Thyroid tuberculosis a clinical case. *Pneumologia* 2000;49:41-4.
13. Fung LM, Ma RC, Chow CC, Cockram CS. Infective thyroiditis in two cases of systemic lupus erythematosus. *Hong Kong Med J* 2004;10:344-6.
14. Milcu SM, Spandonide T, Saim A. Tuberculous thyroiditis cured by drug therapy. *Endocrinologie* 1981;19:261-3.
15. Lioté HA, Spaulding C, Bazelly B, Milleron BJ, Akoun GM. Thyroid tuberculosis associated with mediastinal lymphadenitis. *Tubercle* 1987;68:229-31.

Received/Başvuru: 30.03.2012, Accepted/Kabul: 11.07.2012

Correspondence/İletişim

İsmail Hakkı ERSOY
Süleyman Demirel Üniversitesi Tıp Fakültesi, Endokrinoloji
ve Metabolizma Hastalıkları Bilim Dalı, ISPARTA, TÜRKİYE
E-mail: hakkiersoy@gmail.com

For citing/Atf için:

Ersoy IH, Aksu O, Koroglu BK, Ciris IM, Altuntas A, Tamer MN. Coexistence of thyroid tuberculosis and graves disease. *J Turgut Ozal Med Cent* 2013;20(3):262-265 DOI: 10.7247/jtomc.20.3.15