

Giant Concha Bullosa Pyocele: An Unusual Cause of Rapidly Developing Nasal Obstruction

Yuksel Toplu, Tuba Bayindir, Serdar Gullu, Erkan Karatas, Ahmet Kizilay

Inonu University, Faculty of Medicine, Department of Otorhinolaryngology, Malatya, Turkey

Abstract

Concha bullosa pyocele is an uncommon intranasal disorder and appears when concha bullosa becomes infected. In this pathology, middle concha may become expanded and can compress surrounding tissues. If it is not appropriately treated with the necessary surgical method, this pathology may lead to intracranial and orbital complications. In this paper, we would like to report a case of giant concha bullosa pyocele which has led to nasal obstruction and headache for two months. The resection of the lateral wall of concha bullosa was performed by transnasal endoscopic procedure. No complications were seen during or after the operation. There were no complaints reported by the patient at the follow-up period and the control endoscopic nasal examination was completely normal. The study aims to provide a consciousness of concha bullosa pyocele in the differential diagnosis of patients with rapidly developing nasal obstruction and headache.

Key Words: Concha Bullosa; Pyocele; Surgery.

Dev Konka Bülloza Piyoseli: Hızlı Gelişen Burun Tıkanıklığının Çok Nadir Bir Sebebi

Özet

Konka bülloza piyoseli nadir görülen bir hastalıktır ve konka bülloza enfeksiyonu sonucunda gelişir. Bu hastalıkta bülloz konka genişleyebilir ve çevre dokulara bası yapabilir. Tedavisi yapılmazsa orbital ve intrakranial komplikasyonlara sebep olabilir. Biz bu yazıda 2 aydır burun tıkanıklığı ve baş ağrısına sebep olan dev konka bülloza piyoselli bir olguyu sunduk. Burun içi endoskopik yaklaşımla konka büllozanın dış yan duvarını çıkardık. Ameliyat sırasında ve sonrasında herhangi bir sıkıntıyla karşılaşmadık. Kontrol muayenelerinde herhangi bir şikayeti olmayan hastanın endoskopik muayenesi de tamamen normal saptandı. Bu olgu, hızlı gelişen burun tıkanıklığı ve baş ağrısı şikayeti olan hastalarda ayırıcı tanıda konka bülloza piyoseline de dikkat çekmek için sunuldu.

Anahtar Kelimeler: Konka Bülloza; Piyosel; Cerrahi.

INTRODUCTION

The infection of concha bullosa, also called pneumatized concha, is defined as concha pyocele. Concha bullosa or turbinate pneumatization is the most common anatomic variation of the middle turbinate. Although usually asymptomatic, it may cause such complaints like nasal congestion, headache, and decreased sense of smell. In addition, having negative effects on osteomeatal complex drainage and aeration, it can cause diseases in surrounding structures (1). If concha bullosa is itself infected, then pyocele concha bullosa, a very rare disease, may occur. Concha bullosa pyocele growth enough to fill the nasal cavity is much more uncommon (2). This paper presents a case of middle turbinate pyocele that precipitates one-sided nasal congestion and headache while completely filling the nasal cavity. Our goal is to draw attention to concha bullosa pyocele in the differential diagnosis of rapidly developing nasal obstruction.

CASE REPORT

A sixteen-year old non-smoking male patient was admitted to our clinic with increasing headache that has

existed for two months, along with the complaints of nasal congestion and unilateral loss of smell. The complaints have carried on despite receiving antibiotics and nasal sprays treatment several times. Nothing noteworthy disease was detected in the patient's history or family history. Nasal examination revealed a mass which almost completely filled the nasal cavity, almost extending outside the vestibule; was covered with hard and red colored mucosa, showing no pulsation; and looked similar to inverted papilloma (Figure 1). The color and size of the mass did not change with the Valsalva maneuver. The paranasal sinus computed tomography showed an intranasal mass that completely filled the left nasal passage, closed the ostium of the neighbouring sinuses, pushed the septum to the right and almost extended out of the vestibule (Figures. 2a and 2b). The patient was operated under general anesthesia. The aspirated purulent and viscous fluid after the green tip of the needle went through the mass confirmed the concha bullosa pyocele diagnosis. The lateral lamellae of the concha bullosa was resected with intranasal endoscopic approach. The ostium of the neighbouring sinuses were reopened, the septoplasty was performed and the nasal passages were washed clean with saline solution. No complications were observed during and after the operation. A seven-day antibiotic treatment

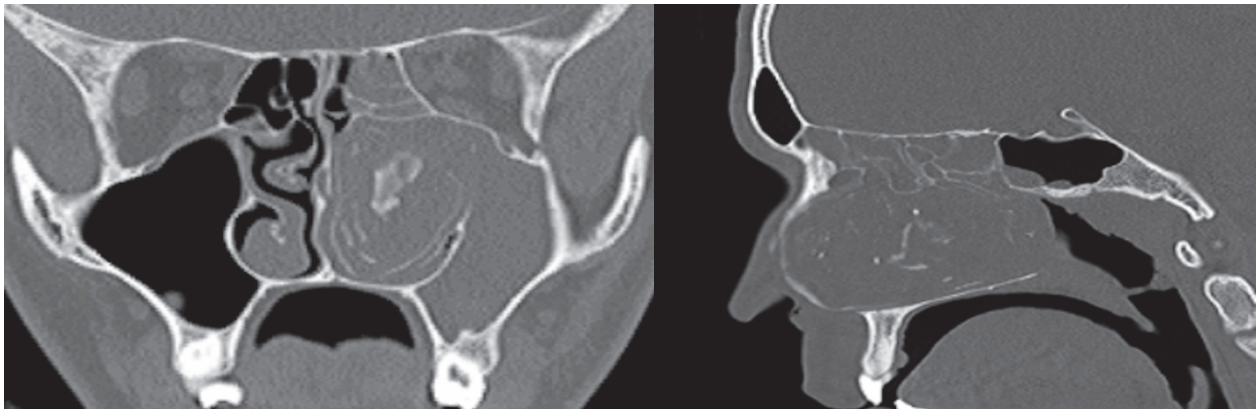
was applied. All symptoms were completely resolved after the surgery. The follow-up tomography one month after the operation was completely normal (Figure 3).

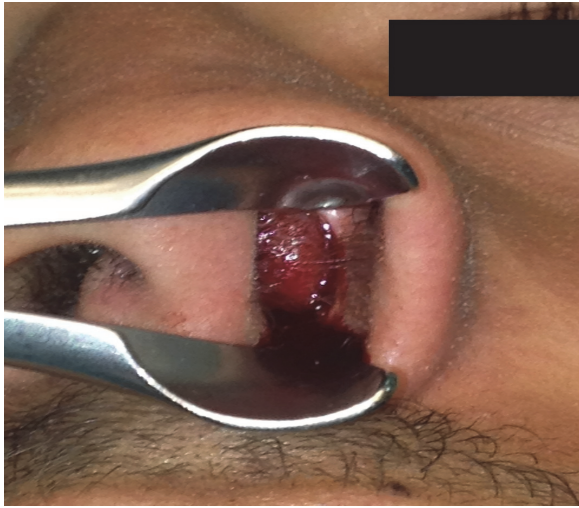

Figure 1. Nasal inspection showing the mass completely filling the left nasal cavity, almost about to exceed the vestibule, hard, covered with red-coloured mucosa, showing no pulsation, and resembling inverted papilloma

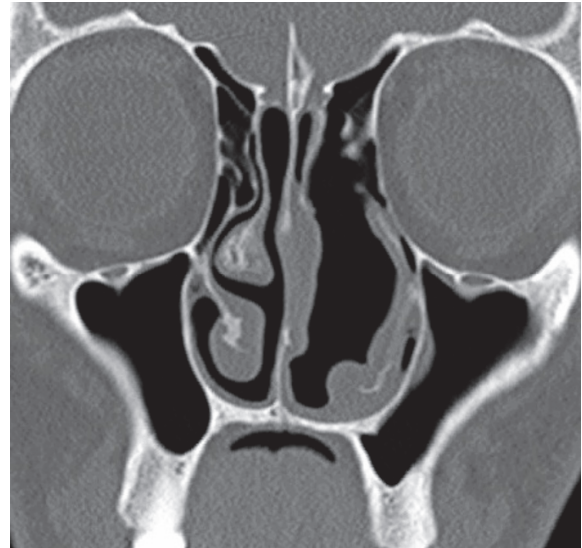

Figure 3. The normal CT image captured one month after the operation



Figures 2a and 2b. The paranasal sinus tomography revealing the mass as it has completely filled the left nasal cavity, pushing septum to the right, covering the ostium of the adjacent sinuses, and almost extending outside the vestibule in the front.

DISCUSSION

Concha bullosa infection is called concha bullosa pyocele. The formation mechanism of concha bullosa and pyocele is not completely understood yet. However, in the etiology, it is thought that air flow patterns of the nasal passages may play a role in its formation. According to this theory known as "E vacuo," air flow decreases on the side of the septal deviation while it increases on the opposite side. Therefore, conchal aeration on the opposite side of the deviation also increases (3,4). Anterior ethmoid sinuses (55%) and posterior ethmoid sinuses (45%) are often responsible for the aeration of the concha. The aeration is directly proportional to the severity of the complaints' degree (5). The incidence of concha bullosa ranges from 53% to

13% (5, 6). In the literature, concha bullosa has been described in three different subtypes: real, lamellar and bulbous concha (6). The incidence rate of each of these subtypes also varies. While lamellar and bulbous types are usually asymptomatic, bulbous types is symptomatic (6,7). In concha pyocele, firstly, the inner mucosa of concha bullosa is inflamed. Inflammation of the inner mucosa often brings about frontal recess of concha bullosa and, though less often, blockages in the mucociliary transport system towards the lateral sinus (8). This blockage usually develops due to chronic inflammation whereas trauma, tumors and surgical operations may also play a role in its etiology (9). Infection resulting from obstruction can cause excessive growth of the turbinate. Excessive growth of the turbinate, in turn, can lead to nasal passage congestion, sinusitis, destruction in the adjacent bones followed by

bone resorption. When untreated, this situation can end up with orbital and intracranial complications (10). In our case, there were no predisposing factors. Moreover, because it was treated in an early period, we did not observe any other complications.

The differential diagnosis must be performed before surgical treatment. Many benign and malignant reasons come to mind in swiftly growing nasal congestion. To ensure the success of differential diagnosis, a consideration of patient's family history, physical examination, endoscopic examination, radiological imaging and, if necessary, a biopsy should be applied. Radiologically, computed tomography shows middle turbinate as grown, but also intact all around the bone, and with soft tissue mass within. The absence of pulsations in the differential diagnosis of the mass and the lack of growth and change in colour with the Valsalva maneuver make intracranial and vascular based causes distant possibilities. In our case, aspirated purulent fluid coming out through the mass at the beginning of the operation confirmed the concha bullosa pyocele diagnosis.

While asymptomatic concha bullosa does not require special treatment, symptomatic concha bullosa cases causing congestion in the osteomeatal complex and concha bullosa pyocele require surgery. The treatment is surgical and includes endoscopic resection of the lateral wall of concha bullosa (1). Concomitant pathologies can be corrected in the same session. In addition to turbinate pyocele surgery of our case, we also performed septoplasty and endoscopic sinus surgery.

As a result, giant concha pyocele that block the nasal passages is very rarely seen. Overgrown pyoceles should be treated with surgical operation in the early stages. Because, if untreated, it may lead to orbital and intracranial complications. Finally, concha bullosa

pyocele should be considered in the differential diagnosis of patients with quickly growing nasal congestion and headache complaints.

The study has been accepted as a poster presentation for the 35th Turkish National Otorhinolaryngology and Head and Neck Surgery Congress (2-6 November, Antalya).

REFERENCES

1. Zinreich SJ, Benson ML, Oliverio PJ. Sinonasal cavities: CT normal anatomy, imaging of the osteomeatal complex, and functional endoscopic surgery. In: Som PM, Curtin HD, editors. Head and neck imaging. 3rd ed., St. Louis: Mosby-Year Book; 1996:97-126.
2. Yellin SA, Weiss MH, O'Malley B, Weingarten K. Massive concha bullosa masquerading as an intranasal tumor. Ann Otol Rhinol Laryngol 1994;103:658-9.
3. Uygur K, Tuz M, Dogru H. The correlation between septal deviation and concha bullosa. Otolaryngol Head Neck Surg 2003;129:33-6.
4. Ural A, Uslu SS, İleri F, Atilla MH, Özbilen S, Köybaşıoğlu A. Dev konka bülloza. KBB ve BBC Dergisi 2002;10:89-92.
5. Bolger WE, Butzin CA, Parsons DS. Paranasal sinus bony anatomic variations and mucosal abnormalities: CT analysis for endoscopic sinus surgery. Laryngoscope 1991;101:56-64.
6. Ünlü HH, Akçay S, Caylan R, Nalça Y. Concha bullosa. J Oto 1994;23:23-7.
7. Tonai A, Baba S. Anatomic variations of the bone in sinonasal CT. Acta Otolaryngol 1996;525:9-13.
8. Zinreich SJ. CT of the nasal cavity and paranasal sinuses with emphasis on inflammatory diseases. In: Anand VK, Panje WR. Practical endoscopic sinus surgery. New York, NY: McGraw-Hill, 1992:42-51.
9. Gullane P, Conley J. Carcinoma of the maxillary sinus: a correlation of the clinical course with orbital involvement, pterygoid erosion or pterygopalatine invasion and cervical metastases. J Otolaryngol 1983;12:141-5.
10. Toledano A, Herraiz C, Mate A, Plaza G, Aparicio JM, De Los Santos G, Galindo AN. Mucocoele of the middle turbinate: a case report. Otolaryngol Head Neck Surg 2002;126:442-4.

Received/Başvuru: 23.09.2013, Accepted/Kabul: 17.10.2013

Correspondence/İletişim

Yüksel TOPLU
Inonu University, Faculty of Medicine, Department of
Otorhinolaryngology, MALATYA, TURKEY
E-mail: yuksektoplu@hotmail.com

For citing/Atf için

Toplu Y, Bayindir T, Gullu S, Karatas, E Kizilay A. Giant pyocele of the concha bullosa, an unusual cause of fast developing nasal obstruction. J Turgut Ozal Med Cent 2014;21:151-3 DOI: 10.7247/jtomc. 2013.1358