

Scar Endometriosis: A Rare Cause of Pain at Cesarean Scar

Cemalettin Koç¹, Gürcan Şimşek¹, Volkan İnce², Ebru Esen¹, Bülent Ünal²

¹Batman Regional State Hospital, General Surgery Clinic, Batman, Turkey

²Inonu University School of Medicine, Department of General Surgery, Malatya, Turkey

Abstract

Scar endometriosis is a rare disease. The incidence rate is around %1,6. The aim of this paper is to investigate one of our patient's symptoms along with the diagnosis methods and surgical therapy used with reference to the literature. A 21-year-old woman was presented with pain and swelling complaints on the cesarean scar. She stated that her complaints were increasing around menstrual cycle. Radiologic examinations showed a vascular, heterogeneous solid mass extending into the rectus muscle. After the excision of the mass, pathologic investigation reported the mass to be endometrioma. Scar endometriosis diagnosis is difficult and it is a rare clinical situation. Scar endometriosis should be considered for female patients with pain around hypertrophic scars probably related to pelvic surgery incisions. In these cases, the relationship between the size of the mass as well as the changes in pain severity with menstrual cycle should be examined.

Key Words: Endometriosis; Scar; Cesarean.

Sezeryan Skarında Ağrının Nadir Bir Sebebi: Skar Endometriozis

Özet

Skar endometriozis nadir görülen bir hastalıktır. İnsidansı yaklaşık olarak %1,6 civarındadır. Bu olgu sunumunda skar endometriozisi tanısı ile cerrahi tedavi uygulanan hastanın semptomlarının, tanı metodlarının ve uygulanan cerrahi tedavinin literatür eşliğinde irdelenmesi amaçlanmıştır. Yirmi bir yaşında bayan hasta sezeryan skarında ağrı ve şişkinlik yakınması ile başvurdu. Şikayetleri menstrüasyon döneminde artan hastanın radyolojik tetkiklerinde, rektus kası içine uzanan vasküler, heterojen solid kitle tespit edildi. Kitle total olarak eksize edildi. Kitlenin patolojik incelemesi endometrioma olarak rapor edildi. Skar endometriozisi tanısı zor olan ve nadir görülen bir klinik tablodur. Skar endometriozisi özellikle pelvik cerrahi insizyon hattında ortaya çıkan ağrılı ve hipertrofik skarlarda akılda tutulmalı ve kitlenin boyutu ve ağrı şiddetindeki değişikliklerin menstrüel siklusla ilişkisi sorgulanmalıdır.

Anahtar Kelimeler: Endometriozis; Skar; Sezeryan.

INTRODUCTION

Endometriosis was first described by Rokitsky in 1860 (1). Endometriosis is a pathology that causes pelvic pain and infertility in the 5-10% women in their reproductive periods. Although endometriosis is usually a pelvic pathology, it may in many different locations from lungs to extremities (2).

Endometriosis in incision line (scar endometriosis), however, is a very rare clinical entity. In the literature, though the incidence of scar endometriosis was reported to be 6% in a series, this rate is around 6% in other series (1).

In this case report, the aim is to analyse the symptoms of a scar endometriosis diagnosed patient who underwent surgical treatment, the methods of diagnosis, and the surgical treatment in the light of the literature.

CASE REPORT

A 21 year old female patient with caesarean birth history was admitted to our clinic with painful swelling complaints in the caesarean section. The patient

reported that the pain had started a few months after from the birth and it rose towards the start of the menstrual period along with the swelling growing worse. She stated that both the pain and the swelling declined with menstrual bleeding. During the physical examination, a hard, irregular and painful-on-palpation mass of about 4x5 cm was palpated at the right lateral end of the Pfannensteil incision scar. The mass did not change in size with valsalva manoeuvre and could not be reduced into the abdomen. In the Doppler ultrasonography (USG) assessment, not a routine laboratory examination, we have defined a mass lesion of approximately 2x3 cm at the right lateral of the Pfannensteil incision, within the rectus muscle; the mass was heterogeneous hyperechoic and had vascularisation. The patient's entire abdominal computed tomographic (CT) evaluation reported the same lesion which was still heterogeneous with irregular contours and increased vascularity upon which a pathological examination was proposed (Figure 1).

With a preliminary diagnosis of endometriosis in the light of radiological findings and the ongoing complaints of the patient, she was taken to the operation room for surgery. Under spinal anaesthesia, we applied incision on the skin and penetrated into subcutaneous tissue.

Rectus sheath was opened and the mass was excised with clear surgical margins. After an uneventful postoperative follow-up, the patient was discharged on the postoperative 2nd day. Pathologic examination of the mass reported as endometrioma (Figure 2). The patient did not have any complaints following her first postoperative menstrual period.

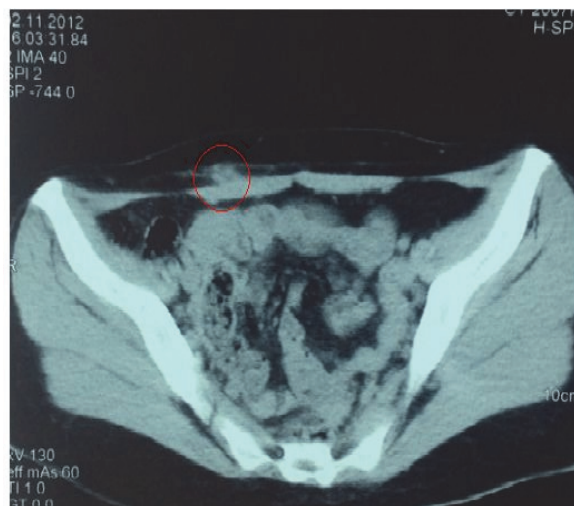


Figure 1. The CT image of the solid and heterogeneous mass along the subcutaneous tissue on the right rectus abdominis muscle.

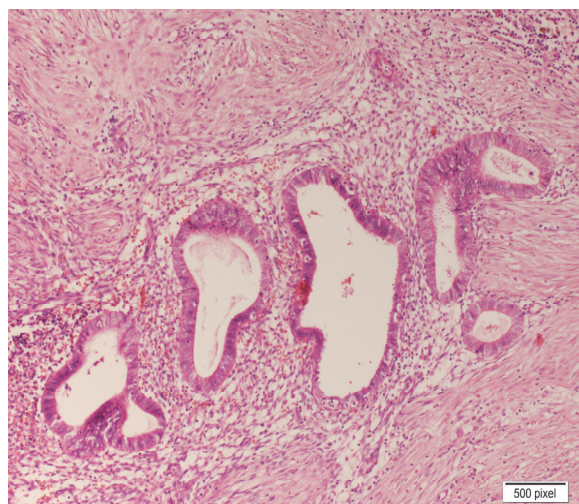


Figure 2. Endometrial glands within the connective tissue as viewed in the microscopic evaluation.

DISCUSSION

Endometriosis, occurring in the abdominal incision scars, is extremely rare in the gynecology literature. Although there are numerous theories concerning the formation of scar endometriosis, the most accepted theory is the theory of atrogenic transplantation around the edges of the wounds during abdominal and pelvic surgery (3-6).

The main clinical sign of scar endometriosis is the varying intensity of pain and size of the mass in the course menstrual period. However, the literature tells us only 20% of the patients had these findings in a series (7). The common finding in almost all patients, on the other hand, is the hypertrophic scars in the line of incision that are painful on palpation (7). In our study, the swelling and pain complaint of the patient at hand was in line with the menstruation. This situation made us suspect scar endometriosis.

Scar endometriosis is a very-difficult-to-diagnose clinical condition. These patients often end up with diagnoses such as hernia, abscess, tumor and lipoma (8). The Doppler ultrasound, as a radiological method, is usually effective in the diagnosis of lesions greater than 30 mm (3). CT usually displays the lesions as a well-circumscribed solid mass. Magnetic resonance imaging is more effective diagnostic method for small and muscle-plan-hid masses. (8).

In our study, the patient was initially examined through Doppler ultrasound after which the lesion was reported as a hypervascular mass. CT, however, showed the heterogeneous nature of the mass and considered the mass vascular, thus, in turn, we planned pathological examination.

Oral contraceptives can be used as pregestational and androgenic agents in the treatment of scar endometriosis. However, the recurrence rate after medical treatment is quite high. Therefore, the definitive treatment for scar endometriosis is surgical excision (9).

As a result, it can be concluded that of scar endometriosis is difficult to diagnose. In particular, painful and hypertrophic scars emerging in pelvic surgery incision line should be kept in mind. The relation between the changes in the mass in terms of size and severity of pain and of menstrual cycling relations should be questioned mass. The definitive treatment for the disease is surgical excision.

REFERENCES

1. Roberge RJ, Kantor WJ, Scorza L. Rectus abdominis endometrioma. *Am J Emerg Med* 1999;17:675-77.
2. Hashim H, Shami S. Abdominal wall endometriosis in general surgery. *Internet J Surg* 2002;3:46-9.
3. Francica G, Giardiello C, Angelone G et al. Abdominal wall endometriosis near cesarean delivery scars. *J Ultrasound Med* 2003;22:1041-7.
4. Kaloo P, Reid G, Wong F. Caesarean section scar endometriosis: Two cases of recurrent disease and literature review. *Aust NZ J Obstet Gynaecol* 2002;42:218-20.
5. Tanos B, Anteby SO. Caesarean scar endometriosis. *Int J Gynaecol Obstet* 1994;47:163-6.
6. Douglas C, Rotimi O. Extragenital endometriosis: A Clinicopathological review of Glasgow hospital with case illustrations. *J Obstet Gynecol* 2006;3:247-9.
7. Ding CD, Hsu S. Scar endometriosis at the site of cesarean section. *Taiwanese J Obstet Gynecol* 2006;3:247-9.
8. Khalifa Al-Jabri. Endometriosis at caesarian section scar. *Oman Med J* 2009;24:4.

9. Payman J, Danielpour MD, John C Layke DO. Scar endometriosis- a rare cause for painful scar: A case report

and review of the literature. Can J Plast Surg 2010;18:1.

Received/Başvuru: 21.09.2013, Accepted/Kabul: 04.11.2013

Correspondence/İletişim

Cemalettin KOÇ
Batman Regional State Hospital, General Surgery Clinic,
BATMAN, TURKEY
E-mail: ckoc_41@hotmail.com



For citing/Atıf için

Koc C, Simsek G, Ince V, Esen E, Unal B. Rare cause of pain at cesarean scar: scar endometriosis. J Turgut Ozal Med Cent 2014;21:154-6 DOI: 10.7247/jtomc.2013.1354