



## Subcutaneous Emphysema Following a Gun Shot Abdominal Ateşli Silah Yaralanması Sonrası Ciltaltı Amfizem

Bora Barut<sup>1</sup>, Volkan İnce<sup>2</sup>, Cemalettin Koç<sup>3</sup>, Serdar Karakaş<sup>2</sup>, Bülent Ünal<sup>2</sup>

<sup>1</sup>Malatya State Hospital, Department of General Surgery, Malatya, Turkey

<sup>2</sup>İnönü University School of Medicine, Department of General Surgery, Malatya, Turkey

<sup>3</sup>Batman Regional State Hospital, Department of General Surgery, Batman, Turkey

Dear Editor,

As a quite rare case, abdominal subcutaneous emphysema often occurs in intra-abdominal infections caused by gas producing organisms. Meanwhile, it may either be a result of the intraluminal gas emission from the retroperitoneum due to intraluminal pressure or perforation, or directly of colcutaneous fistula (1,2). Therefore, it is the harbinger of a life-threatening clinical condition. With this report, we would like to present a patient's case who developed extensive abdominal subcutaneous emphysema within 24 hours after the surgery he underwent as a result of a gun shot.

Twenty six years old male patient was brought to the emergency department with firearm injury. The bullet had entered the body from the epigastric region and gone out through the right lumbar. In good state of consciousness and moderate general state of health, the patient underwent operation in the second hour after the injury. The patient had a 1x1cm perforation in the stomach prepylorus, hematoma in the right retroperitoneal region, and grade two kidney laceration. Primary repair of the abdomen achieved, the duoedo was brought to a coherent state. The gastrocolic ligament was opened and the right colon was liberalised. There were no other pathologies.

The efficacy of the stomach was tested by performing a leak test with methylene blue through nasogastric intubation. No leak was detected. Having observed hemorrhage leakage from around the geroter fascia of the right kidney, we applied packing to compress the leakage. After the operation, the patient was intubated and was sent to the intensive care unit. Hemodynamic support treatment was started on the patient. At the postoperative 24th hour, we observed abdominal subcutaneous emphysema on physical examination and x-rays (Figure 1).

After the developing fever, both to perform depacking and to check for the possibility of overlooked perforation, the patient was re-operated. We observed that the hemostasis was in good state, stomach repair was intact, and that there were no other perforations.

The postoperative follow-up was uneventful and the patient was discharged on the seventh day. In his fourth postoperative month, the patient continues to live without any problems.

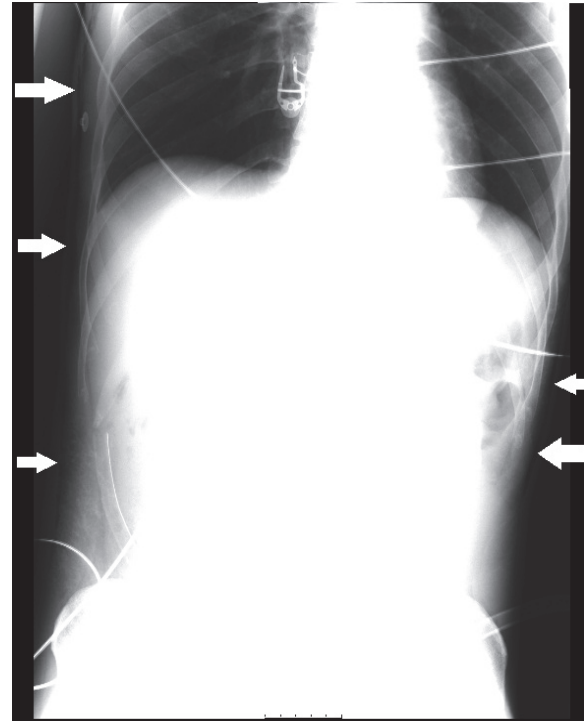


Figure 1. Abdominal subcutaneous emphysema (arrows)

The stomach perforation after the bullet injury was treated within two hours from the accident but abdominal subcutaneous emphysema developed though the time required for gas producing organisms was too short to get infected. Because we did not find out any perforations in the depacking operation, we believe that the cause for abdominal subcutaneous emphysema development was the bullet injury.

## REFERENCES

1. Sutton PA, Jenner-O'Brien M, Monk D. Subcutaneous emphysema of the abdominal wall. *BMJ Case Rep* 2013;10;2013.

2. Yaşar NF, Kebapçı M, İhtiyar E. Pneumomediastinum and subcutaneous emphysema caused by sigmoid diverticulum perforation secondary to blunt abdominal trauma: report of a case. *Ulus Travma Acil Cerrahi Derg* 2011;17:93-5.

Received/Başvuru: 04.02.2014, Accepted/Kabul: 11.03.2014

## Correspondence/İletişim

**Bora BARUT**  
Malatya State Hospital, Department of General Surgery,  
MALATYA, TÜRKİYE  
E-mail: borabarut@mynet.com



## For citing/Atıf için

Barut B, Ince V, Koc C, Karakas S, Unal B. Subcutaneous emphysema following gun shot. *J Turgut Ozal Med Cent* 2014;21:247-8 DOI: 10.7247/jtomc.2014.1758